



REVIEW ARTICLE

ANTERIOR ABDOMINAL WALL NECROTIZING FASCIITIS A CASE REPORT IN A NEWLY  
DIAGNOSED DIABETIC PATIENT

\*Dr. Sathish.V.Shivamallaiiah

Consultant Surgeon, Taliparamba co-op Hospital, Taliparamba

ARTICLE INFO

Article History:

Received 05<sup>th</sup> January, 2014  
Received in revised form  
04<sup>th</sup> February, 2014  
Accepted 15<sup>th</sup> May, 2014  
Published online 20<sup>th</sup> May, 2014

Key words:

Necrotising fasciitis, Surgical  
debridements, High index of suspicion.

ABSTRACT

Necrotising fasciitis is a dreaded disease with high mortality and morbidity, can affect any part of the body, mostly in patients with immunocompromised individuals such as diabetics, patients on immunosuppressants, old debilitated bedridden patients, cancer patients etc. It requires high index of suspicion like Dish water discharge will help in early diagnosis and prompt treatment which includes serial surgical debridements and directed antibiotic treatment, here I have made an attempt which will help in early diagnosis which in turn decreases its high mortality and morbidity.

Copyright © 2014 Dr. Sathish. V. Shivamallaiiah. This is an open access article distributed under the Creative Commons Attribution License, which permits unrestricted use, distribution, and reproduction in any medium, provided the original work is properly cited.

INTRODUCTION

Necrotising fasciitis is a dreaded Polymicrobial infection of subcutaneous tissues and deep fascia with high mortality rate which requires high index of suspicion, early diagnosis emergency prompt multimodality treatment which includes serial surgical debridements and sensitivity directed antibiotic treatment in a war footing fashion in order to reduce the mortality and morbidity rates.

Case report

In our hospital I came across an obese female patient aged about 44 years with diffuse abdominal tenderness, fever and anorexia of seven days duration without a history of trauma. She was not a known diabetic or hypertensive. On examination patient was febrile and anterior abdominal wall appeared erythematous and a pointing pus presented in the left iliac fossa with diffuse tenderness all over the abdomen. There was no guarding or rigidity and bowel sounds were present.

Initially I suspected anterior abdominal wall abscess and incision & drainage was planned and incision was put over the pointing pus under local anesthesia and about 50ml of pus drained. Still on palpating the erythematous region pus started pouring which was of dish water like (Fig.1 & 2), then I suspected necrotising fasciitis and admitted the patient and planned for wound exploration under spinal anesthesia.

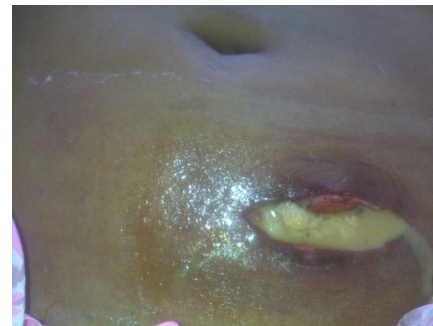

Fig.1.

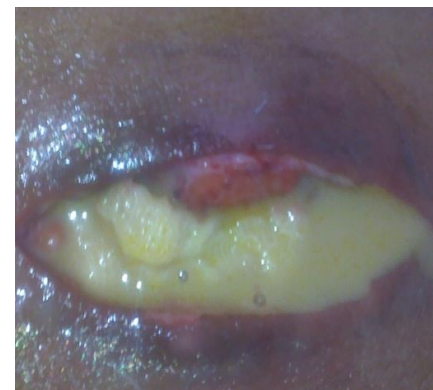

Fig.2.

\*Corresponding author: Dr. Sathish. V. Shivamallaiiah,  
Consultant Surgeon, Taliparamba co-op Hospital, Taliparamba.

All routine investigations were done and she was found to be diabetic. Her total count and neutrophils were markedly raised, erect x-ray abdomen and USG of abdomen were done to rule out any intraabdominal extension or communication which

were normal except anterior abdominal wall edema and collection.

Under spinal anesthesia previously put incision was extended and on exploration huge amount of pus, necrotic tissue and slough were noted, pus sent for culture and sensitivity, thorough debridement was done and dressing was done with a pack and drain on both iliac fossae after confirming that there were no communications with the peritoneal cavity. (Fig.3,4)

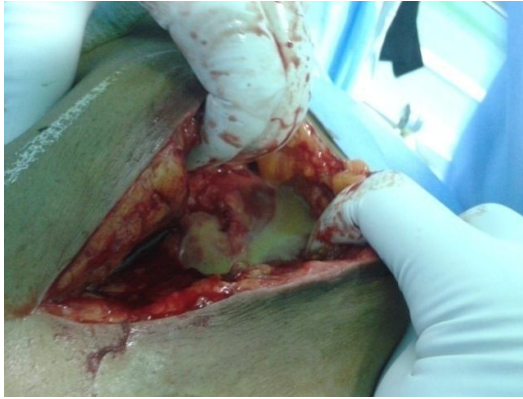


Fig.3.

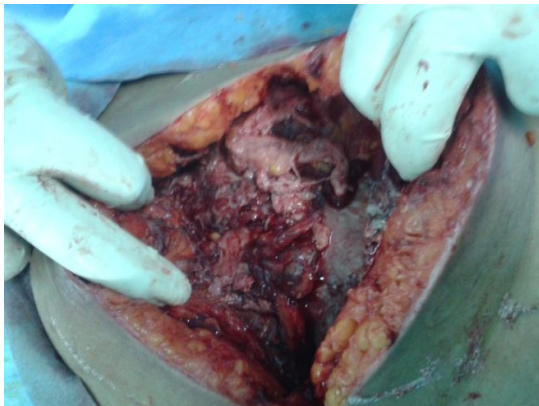

Fig.4.

Antibiotics were given according to pus culture and sensitivity and alternate day dressing with debridement under sedation was done regularly and diabetes was controlled with insulin and oral hypoglycemics. After 15 days healthy pink granulation tissue appeared with no pus or discharge.

Patient was undertaken for secondary suturing after 3 repeated cultures were negative for any organisms. Suturing was done with mono-filament non absorbable suture after trimming the edges over suction drains on either iliac fossae. Drains removed after fifth post operative day when the discharge was less than fifteen ml and antibiotics were continued according to the last culture sensitivity report for 7 days. After 12 days no collection or dehiscence was noted, sutures were removed and topical antiseptics were given for 5 days and after 5 days patient was asymptomatic without any complaints. She was discharged. (Fig.5,6,)

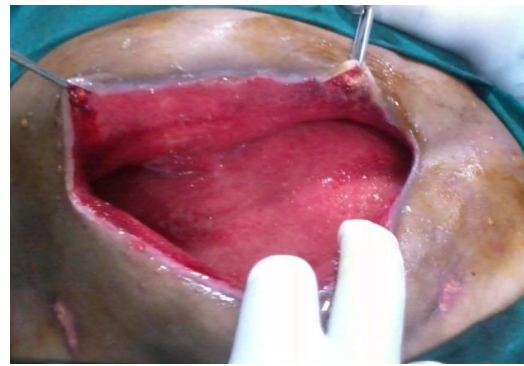


Fig.5.

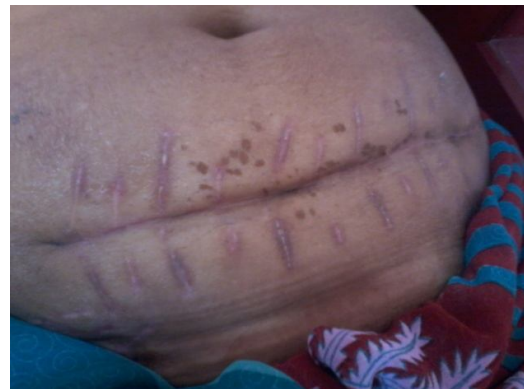

Fig.6.

## DISCUSSION

Necrotising fasciitis is a dreaded (Polymicrobial in nearly 85% of cases and Monomicrobial in nearly 15% of cases) infection of subcutaneous tissues and deep fascia with high mortality rate which requires high index of suspicion, early diagnosis emergency multimodality treatment which includes serial surgical debridements and sensitivity directed antibiotic treatment. In 1871 Jones first clearly defined necrotising soft tissue infection as HOSPITAL GANGRENE there after many authors defined, described and grouped this into various types. The term necrotizing fasciitis was coined by Wilson in 1952 and subsequently many definitions and types were described, most acceptable being - 'its an acute surgical condition which progresses rapidly and affects the fascia and subcutaneous tissue concomitantly with development of thrombosis of skin microcirculation resulting in necrosis of skin and soft tissues and destruction of muscles and liquefaction of fats'. (Dubraveo Huljer *et al.*, 2005; Necrotizing fasciitis)

### Risk factors for the development of necrotising fasciitis are

1. Diabetes mellitus
2. Age more than 50 years
3. Recent surgical procedures such as appendicectomy, hernioplasty, laparotomy etc
4. NSAIDs in post operative patients
5. Immunocompromised conditions

6. Bedridden patients (Demuro *et al.*, 2012; Sabiston's text book of surgery; Bailey & Love's text book of surgery; Schwartz text book of surgery).

## MICROBIOLOGY

Majority of infection are due to normal skin commensals and hence reflects the anatomical location of the lesions. Most common organism isolated in monomicrobial type is Group A Streptococcus (*Streptococcus pyogenes*) followed by Staph. Aureus, *Clostridium perfringens*, *Bacteroides fragilis*, *Aeromonas hydrophila* etc (Roje *et al.*, 2011). There are numerous types or classifications of this condition most widely accepted is as follows:

1. Type 1: Polymicrobial which constitutes more than 85 % of the cases
2. Type 2: Monomicrobial which makes up to rest of 15 %
3. Type 3: Gas gangrene caused by *Clostridium perfringens* in majority of the cases, followed by *Clostridium septicum* (Medicine Net.com Infectious diseases & Necrotising fasciitis by Charles Patrick Danis, Melisa Conrad Stoppler; International journal of surgery, case rep 2013)

The condition demands prompt combined early and aggressive approach of treatment to avoid the mortality which ranges from 50 to 100 % if delayed. High index of suspicion, early diagnosis and prompt treatment with antibiotics and serial debridements will help in reducing this high mortality rate. (Dubraveo Huljer *et al.*, 2005; Sabiston's text book of surgery; Bailey & Love's text book of surgery; Schwartz text book of surgery)

## Complications

1. Amputation, in 25% of patients with necrotising fasciitis of limb, in whom mortality rate ranges from 50 to 80 %.
2. Renal insufficiency, in 31.6 % of cases with a mortality rate up to 50%
3. Acute respiratory distress syndrome, in 29% of patients with a mortality up to 59%
4. Multi-Organ failure, in 21% of cases with a mortality of 77.5% (Dubraveo Huljer *et al.*, 2005; Necrotizing fasciitis; Wikipedia The free encyclopedia; Sabiston's text book of surgery; Bailey & Love's text book of surgery; Schwartz text book of surgery)

## Treatment

Early aggressive serial surgical debridements with frequent pus cultures directed antibiotic treatment and dressings will be helpful in controlling the progression and spread of disease.

(Dubraveo Huljer *et al.*, 2005; Necrotizing fasciitis; Demuro 2012; Wikipedia The free encyclopedia; Sabiston's text book of surgery; Bailey & Love's text book of surgery; Schwartz text book of surgery)

## Prognosis

Mortality rate is 50 to 100% which can be reduced with a high index of suspicion, early diagnosis and aggressive multimodality treatment as described. (Dubraveo Huljer *et al.*, 2005; Roje *et al.*, 2011; Necrotizing fasciitis; Wikipedia The free encyclopedia; Sabiston's text book of surgery; Bailey & Love's text book of surgery; Schwartz text book of surgery) Conclusion: Even though the mortality rate in cases of necrotising fasciitis is high, with high index of suspicion, early diagnosis, multiple surgical debridements, with directed antibiotic therapy and treating or controlling underlying cause or predisposing factors will reduce it and prognosis will be better.

## REFERENCES

- Bailey & Love's text book of surgery 23<sup>rd</sup> edition page no- 171-172
- Balaggan K S, Godamali SI. Periorbital necrotising fasciitis after minor trauma, *Br. J Ophthalmol* 2010 Dec 94(12);1577-85 doi; 10.1136/bjo.2009.167486 E Pub 2009 Nov 5.
- Demuro JP, AF Hanna, E. Chalas and BA Cunha. *Journal of surgical case reports* volume 2012, issue 9 pg 10. Medicine Net.com Infectious diseases and Necrotising fasciitis by Charles Patrick Danis, Melisa Conrad Stoppler.
- Hong GL, Lu CJ *et al.* Pub Med.gov- Surgical treatment of 19 cases with vibrio necrotizing fasciitis, 2012 mar, 38(2); 290-5, doi; 10.1016/ *J. Burns* 2011.04.013- E Pub-2011 nov 21.
- International journal of surgery*, case rep 2013; 4(3);286-9. Doi 10.1016/j.ijsr.2012.12.008. E Pub 2013/1/5.
- Necrotising fasciitis of abdominal wall as a post surgical complication. By Dubraveo Huljer MD, *et al.* Med space publication 2005; 17(7);169-177.
- Necrotizing fasciitis; Wikipedia The free encyclopedia.
- Richard. F. Edlich *et al.* Necrotising fasciitis treatment and management, Med space.
- Sabiston's text book of surgery 18<sup>th</sup> edition page no- Schwartz text book of surgery 8<sup>th</sup> edition page no-434 & 1107-1108
- World journal of Emergency surgery*, Roje *et al.* 2011, 6;46.

\*\*\*\*\*