



## RESEARCH ARTICLE

### LEMMEL SYNDROME: RARE BUT NOT UNCOMMON ENTITY

Parveen Malhotra, Yogesh Sanwariya, Bibin CF, Senti, Harman Singh and Sandeep Kumar

Lemmel Syndrome, Jaundice, Pain abdomen, Dyspepsia, Cholangitis

#### ARTICLE INFO

##### Article History:

Received 20<sup>th</sup> October, 2024  
Received in revised form  
17<sup>th</sup> November, 2024  
Accepted 24<sup>th</sup> December, 2024  
Published online 31<sup>st</sup> January, 2025

##### Key Words:

ABO; Rh-D; Blood group; South Sudan;  
Blood bank; Blood transfusion.

\*Corresponding author:  
Parveen Malhotra

#### ABSTRACT

**Background:** Understanding the distribution of ABO and Rh-D blood groups in a local population is crucial for planning and managing blood bank inventories and ensuring safe blood transfusion practices. Despite such importance, there is no data in South Sudan on the distribution of the ABO and Rh-D blood groups in the population across the country. **Methods:** Using a conventional forward blood typing approach, we examined the prevalence of ABO and Rh-D blood groups and their distribution among different community members from seven ethnic counties of Unity State living in a Protection of Civilian (PoC) site in Juba, South Sudan. **Results:** The results revealed that, out of the 339 participants, blood group O was the most prevalent (57.5%), followed by blood groups A (21.8%), B (15.9%), and AB (4.7%), across all the study areas. Rh-D-positive participants comprised 89.1% of the study population, while Rh-D-negative participants made up 10.9%. When the ABO and Rh-D blood group distributions were analyzed with respect to the participants' areas of origin and gender, the study revealed no significant association between blood group distribution and area of origin. However, there was a significant difference in the distribution of the ABO and Rh-D blood groups between male and female participants. **Conclusion:** This study's findings will guide future national health policy planning of national and regional blood banks in South Sudan. We recommend that a large regional or nationwide study involving participants from different regions and ethnic backgrounds be conducted in the country to confirm our findings.

Copyright©2025, Parveen Malhotra et al. This is an open access article distributed under the Creative Commons Attribution License, which permits unrestricted use, distribution, and reproduction in any medium, provided the original work is properly cited.

Citation: Parveen Malhotra, Yogesh Sanwariya, Bibin CF, Senti, Harman Singh and Sandeep Kumar. 2025. "Lemmel syndrome: rare but not uncommon entity". International Journal of Current Research, 17, (01), 31519-31521.

## INTRODUCTION

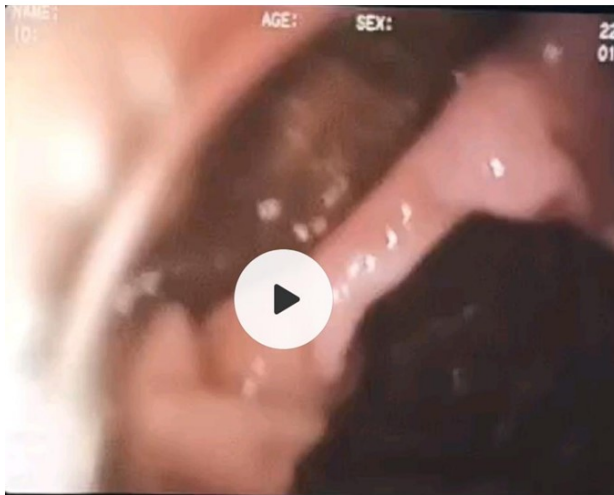
Lemmel syndrome (LS) constitutes the presence of obstructive jaundice in the absence of choledocholithiasis or pancreatic-biliary tumours (1). It was first reported in 1934 by Lemmel, who described a peri-ampullary duodenal diverticulum (PDD), a potentially obstructive sac-like outlet pouch from the duodenal mucosa. Most of their presentation is found in asymptomatic patients, and they can be identified incidentally in up to 22% of the population, of which <10% will present with symptoms (2). Clinically, LS consists of pain in the right upper quadrant, and elevated levels of bilirubin, transaminases and/or pancreatic enzymes, consequently from the involvement of the ampulla of Vater (3). Nowadays, the use of endoscopic treatment using ERCP is recommended for the diagnosis of PDD leading to LS (4).

## CASE REPORTS

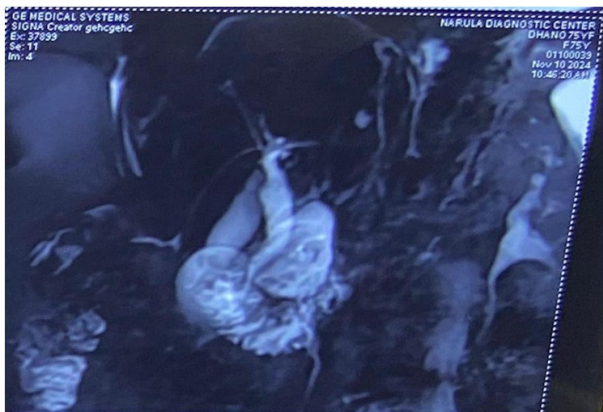**FIRST CASE-**Our patient was a 65-year-old female and was not a known case of any chronic illness and presented with jaundice and pain abdomen for last two weeks. There was no history of initial prodrome of fever, myalgia or vomiting, suggestive of acute viral hepatitis.

He had features of obstructive jaundice like severe itching and passage of clay-coloured stools. Physical examination showed scleral icterus and abdominal examination revealed painful abdomen on palpation in the epigastrium and right hypochondrium. There was no fever, tachycardia or neurological manifestations. The cardiopulmonary examination was essentially normal. The labs revealed normal complete hemogram with raised serum bilirubin levels, total bilirubin (8 mg/dl), direct bilirubin (4.50 mg/dl), alkaline phosphatase (195 U/L), gamma-glutamyl transferase (202 U/L), aspartate aminotransferase (48 U/L), alanine aminotransferase (30 U/L), albumin (3.4 g/dl), International Normalized Ratio (1), normal serum amylase and lipase levels. The ultrasound abdomen showed multiple 2-3 mm gall stones but without any features of cholecystitis, common bile duct was 8mm but without any stones or sludge in it. The contrast enhanced computed tomograph (CECT Scan) abdomen confirmed the findings of ultrasonogram abdomen but in addition revealed large duodenal diverticulum with solid contents in it, compressing CBD and pancreatic duct, suggestive of Lemmel syndrome. The endoscopy also confirmed the large duodenal diverticulum with thick inspissated material in it which was removed with foreign body forceps and later on flushed with normal saline.

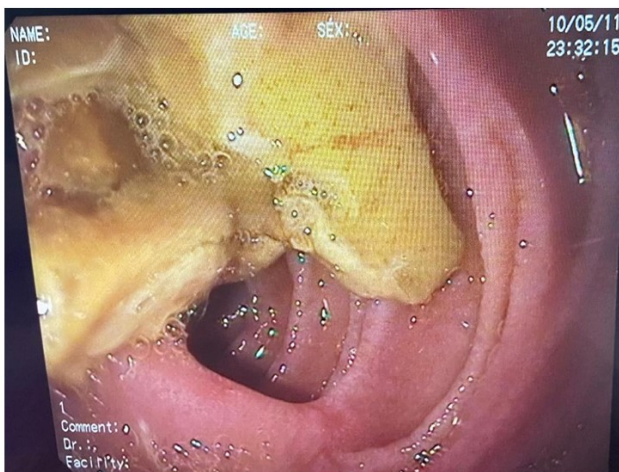Majority of this yellow coloured inspissated material which was mixture of food residue, bile and pancreatic juice was removed. This led to steady decrease in obstructive jaundice symptoms which ultimately normalized and patient had complete resolution of all the symptoms. He was advised ERCP and laparoscopic Cholecystectomy but refused and wanted to get it done on follow up due to personal reasons. This patient was lost to follow up.



**Figure 1. Showing Large Duodenal Diverticulum in D2 After Removing of Debris**



**Figure 2. MRCP Showing Dilated CBD Due To Extrinsic Compression By Diverticulum**



**Figure 3. Endoscopy Showing Retained Inspissated Debris in Duodenal Diverticulum**

## SECOND CASE

This patient was a 48-year-old female and was not a known case of any chronic illness and presented with dyspepsia and pain abdomen for last three months. She was unaware of jaundice. There was no history of initial prodrome of fever, myalgia, haematemesis, Malena or pain radiating to back. The general physical examination showed mild scleral icterus but abdominal examination was essentially normal. The cardiovascular, pulmonary and neurological examination was unremarkable. The labs revealed normal complete hemogram with mildly raised serum bilirubin levels, total bilirubin (2.7mg/dl), direct bilirubin (1.6 mg/dl), alkaline phosphatase (172 U/L), gamma-glutamyl transferase (106 U/L), aspartate aminotransferase (29 U/L), alanine amino-transferase (41 U/L), albumin (3.6 g/dl), International Normalized Ratio (1.1) with normal serum amylase and lipase levels.

The ultrasound abdomen showed distended gall bladder with few filling defects with largest measuring 12 mm and common bile duct was dilated to 11.5 mm but without any stones or sludge in it. The Magnetic resonance cholangiopancreatography (MRCP) revealed dilated CBD of 11.5 mm with focal outpouching arising from the medial aspect of the second part of duodenum, adjacent to the duodenal papilla measuring 34 mm x 23 mm in size and showing flocculent heterogenous contents within the lumen likely diverticulum, causing smooth extrinsic compression on the adjacent distal CBD., no definitive thickening or mass. There was moderate dilatation of upstream CBD noted with no significant dilatation of intrahepatic bile ducts. The gall bladder was distended with few filling defects with largest measuring 12 mm. The endoscopy also confirmed duodenal diverticulum with thick inspissated material in it which was removed with foreign body forceps and later on flushed with normal saline. Whole of this yellow coloured inspissated material which was mixture of food residue, bile and pancreatic juice was removed. This led to complete resolution of symptoms and serum bilirubin level. The patient has been planned for laparoscopic Cholecystectomy and ERCP,

## DISCUSSION

Of all the types of duodenal diverticulum, the periampullary are the most frequent (5), LS is caused by these with association to obstructive jaundice; patients are usually asymptomatic, although 5% may present with complications such as recurrent gallbladder or bile duct stones, obstructive jaundice, cholangitis or acute pancreatitis, less frequently they present diverticulitis, haemorrhage, perforation or fistula formation (6). The pathophysiology of LS depends on the location of the diverticulum, chronic fibrosis of the papilla can occur secondary to periampullary diverticulitis and chronic inflammation of the ampulla (7). As well as a dysfunction of the sphincter of Oddi, or by external compression of the common bile duct or the ampulla of Vater by the PDD (6). Magnetic Resonance Cholangiography or ERCP (7) are indicated, the latter has the advantage of representing an effective mixed modality (diagnostic/therapeutic), which allows for a sphincterotomy and placement of a biliary stent. The laparoscopic cholecystectomy is advisable in majority of cases depending upon symptoms and size of stones, as had been in our two cases.

## CONCLUSION

It is very important for treating medical specialists like gastroenterologist, hepatologist, general physicians and surgeons who most frequently analyse patients of jaundice, dyspepsia and pain abdomen to be vigilant for rare causes of jaundice, especially with obstructive jaundice and pain abdomen which includes Lemmel syndrome which is rare but not uncommon. It is always said that eyes see those things which brain knows. Lemmel syndrome can lead to devastating complications like cholangitis, pancreatitis, haemorrhage, perforation, multiple organ failure and even death. Thus, it warrants early diagnosis and timely treatment.

**CONFLICT OF INTEREST STATEMENT:** The authors declare there is no conflict of interest.

## REFERENCES

1. Kang HS, Hyun JJ, Kim SY, *et al.* Lemmel's syndrome, an unusual cause of abdominal pain and jaundice by impacted interdiverticular enterolith: case report. *J Korean-Med Sci* 2014; 29:874–8.
2. Khan BA, Khan SH, Sharma A. Lemmel's syndrome: a rare cause of obstructive jaundice secondary to periampullary diverticulum. *EJCRIM* 2017;1–3.
3. Rouet J, Gaujoux S, Ronot M, Palazzo M, Cauchy F, Vilgrain V, *et al.* Lemmel's syndrome as a rare cause of obstructive jaundice. *Clin Res Hepatol Gastroenterol* 2012;36: 628–31.
4. Bernshteyn M, Rao S, Sharma A, Masood U, Manocha D. Lemmel's syndrome: usual presentation of an unusual diagnosis. *Cureus* 2020;12: e7698.
5. Chomel JB. Report of a case of duodenal diverticulum containing gallstones. *Histoire Acad R Sci Paris* 1710;1710:48–50.
6. Desai K, Wermers JD, Beteslassie N. Lemmel syndrome secondary to duodenal diverticulitis: a case report. *Cureus* 2017;9: e1066. Published 2017 Mar 1.
7. Frauenfelder G, Maraziti A, Ciccone V, *et al.* Computed tomography imaging in Lemmel syndrome: a report of two cases. *J Clin Imaging Sci* 2019; 9:23.

\*\*\*\*\*