



## RESEARCH ARTICLE

### DUAL APPLIANCE- SPACE REGAINER AND MAINTAINER IN SAME APPLIANCE

\*Dr. Rahmi, S. and Dr. Rashmi, S.

KVG Dental College and Hospital, Sullia, Karnatake, India

#### ARTICLE INFO

##### Article History:

Received 24<sup>th</sup> July, 2024  
Received in revised form  
17<sup>th</sup> August, 2024  
Accepted 29<sup>th</sup> September, 2024  
Published online 30<sup>th</sup> October, 2024

##### Key Words

Satire, Politique, Morale, Religion,  
Fanatisme.

##### \*Corresponding author:

Dr. Rahmi, S.

#### ABSTRACT

Primary teeth are need to stay in place till they are replaced by permanent teeth, so they are the best space maintainers. One of the main reasons for early extraction of primary teeth is be Early childhood caries especially in the anterior. So, any untimely loss of anterior teeth subsequently causes a) morphological problems- impaction and eruption disturbances of permanent successors; inclination and/ or extrusion of adjacent and antagonist teeth, respectively; midline deviation; and crowding b) functional problems; speech disorders, aesthetic problems, and development of non-nutritive habits c) psychosocial problems; decrease in self-esteem<sup>2</sup>. However, in some cases there can be a combination of problem like early loss of tooth leading to space loss and impaction of the erupting tooth so that calls for regaining the lost space and restoring the missing tooth till the permanent teeth replacement is done. This paper presents an innovative design incorporating both the treatment objectives in a single appliance: A dual appliance with dual treatment outcome.

Copyright©2024, Rahmi and Rashmi. This is an open access article distributed under the Creative Commons Attribution License, which permits unrestricted use, distribution, and reproduction in any medium, provided the original work is properly cited.

Citation: Dr. Rahmi, S. and Dr. Rashmi, S. 2024. "Dual appliance- space regainer and maintainer in same appliance". *International Journal of Current Research*, 16, (10), 30204-30207.

## INTRODUCTION

Primary teeth plays significant role in maintaining natural space and function until succeeded by permanent teeth. Premature loss of primary teeth can cause damage to the stability of the arch and negatively impact the proper alignment of permanent teeth<sup>1</sup>. It is not uncommon to come across early loss of anterior teeth in primary dentition and the main reason being the Early childhood caries. In India, 64.3% accounts for primary teeth loss due to ECC followed by 43.02% among children<sup>2</sup>. The loss of anterior teeth is essentially due to the vulnerability of involving cervical margin of all anterior and fracture at the neck of the teeth- a typical pattern of Early Childhood Caries<sup>3</sup>. It is shown that immediate replacement can avoid impaction and eruption disturbances of permanent successors, inclination and/ or extrusion of adjacent and antagonist teeth, midline deviation and crowding, speech disorders, aesthetic problems, and development of non-nutritive habits and psychosocial problems decreasing self-esteem<sup>4</sup>. Even though space loss is less in the anterior compared to posterior, this paper highlights the space loss following early extraction of deciduous tooth and its management by a novel design incorporating dual strategies of regaining the space and prosthetic rehabilitation in a single appliance.

## CASE REPORT

A 6-year-old male child accompanied by the parents visited to dept of pediatric and preventive dentistry, KVG dental college and hospital, Sullia, Karnataka with chief complain of gap in upper anterior teeth region since few months. History of Early childhood caries and extraction of 52 done one year back with no follow up. On intra oral examination, early loss of 52 with mesial migration of 53 and distal migration of 11 leading to impaction of 12 and midline diastema between 11 and 21 with mucosal labial frenum attachment. Other findings include missing 74, class II caries irt 54,55,64 and 65 and class II restored irt 84. On model analysis, available space showed less than predicted space requiring space regainer. Radiographic investigation reveals 4-5mm of soft tissue covering 12 and distal migration of 11 and mesial migration of 53. This correlates to rule out ugly duckling stage that normally occurs between 9 to 11 years of age after the eruption of lateral incisors and before the eruption of permanent canines. Diagnosis made was class I molar relation with spacing irt maxillary anteriors with space loss.

#### Treatment Objectives included:

- Space regaining occlusal guide for the eruption of lateral incisor
- Closure of midline diastema in maxillary arch
- Space maintenance irt 74

Treatment options for this case included fixed or removable space regainer followed by functional space maintainer until the eruption of 22. the fixed space maintainer was opted for better patient compliance & was decided for a dual objective in the same plate and prosthetic replacement to fulfil the aesthetic replacement till the eruption of lateral incisor as the child and parent were particular about the aesthetic.

### Treatment was planned in 2 phases

**Phase 1:** banding was done irt 16 and 26 followed by a novel design to fulfil the two objectives in a single plate fabrication. Banding was also done irt 75 for conventional band and loop space maintainer fabrication. A fixed appliance was preferred for patient compliance. Therefore, Nance palatal arch with finger spring incorporated within the nance acrylic button for mesial movement of 11(Figure 1& 2).

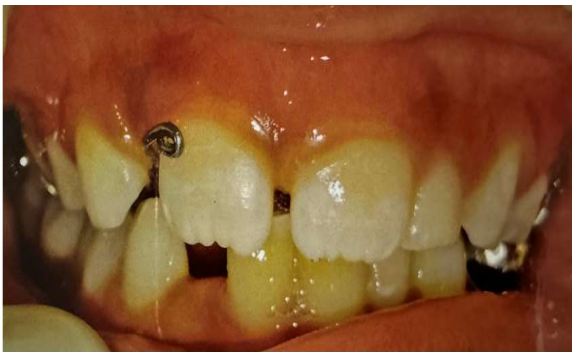

Figure 1. Pre operative

Phase 1 treatment: Nance palatal arch incorporated with finger spring irt 11

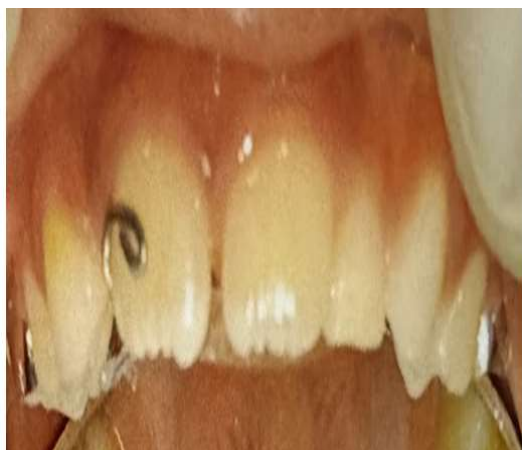
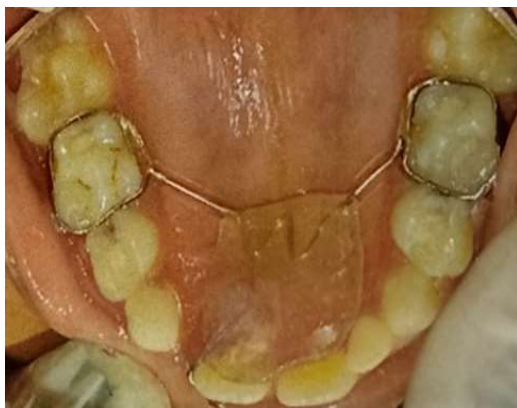
Figure 2. Intraoral image of the appliance

Finger spring was activated 2 mm once in month for 2 months until space regained. Conventional band and loop space maintainer cemented irt 75 (figure 4).

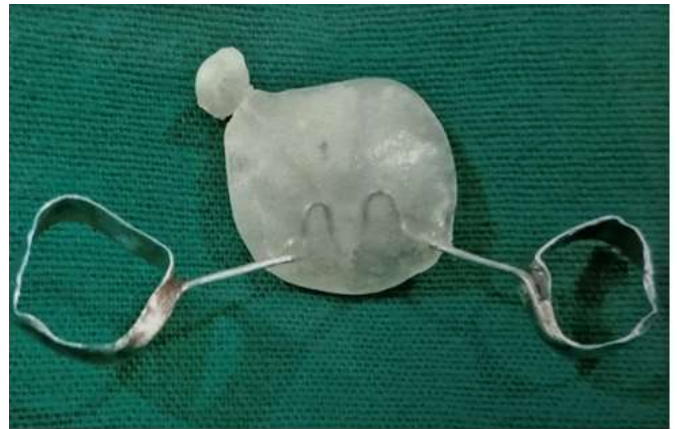


Figure 3. Appliance with luxatemp

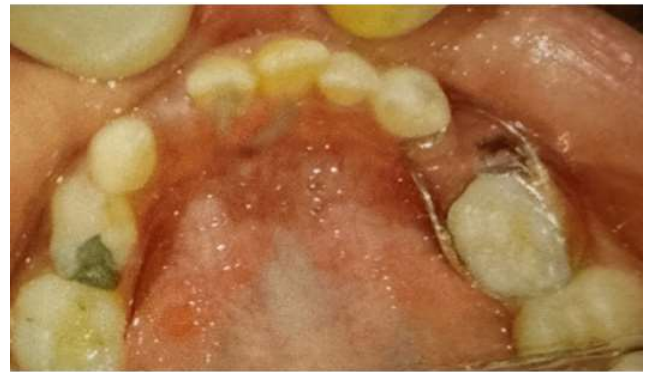
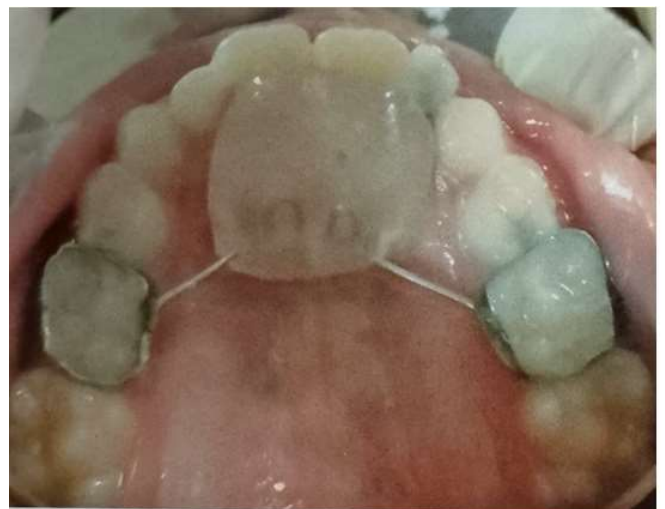
Figure 4. band and loop space material for 52 maintainer

**Phase 2:** Once the closure of diastema and desired space was achieved, the same finger spring was bent to use as an anchorage to incorporate functional space maintainer. maxillary impression was made, wax model of adequate measurements was done on the cast referring to the contralateral lateral incisors and reimpression of the cast was taken. Luxatemp material was used as a choice of material for the fabrication of lateral incisor replacing the space acquired by wax model (Figure 3). The appliance fabricated placed intraorally to check for the fit and occlusal harmony (figure 5& 6) and corresponding radiograph was taken (figure7).



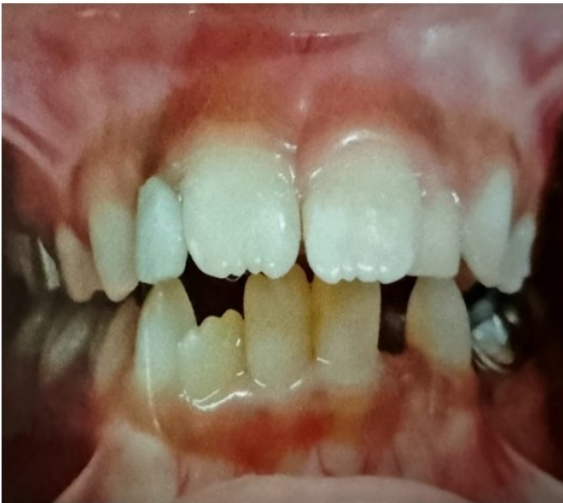

Figure 5. Phase 2 treatment: nance palatal arch

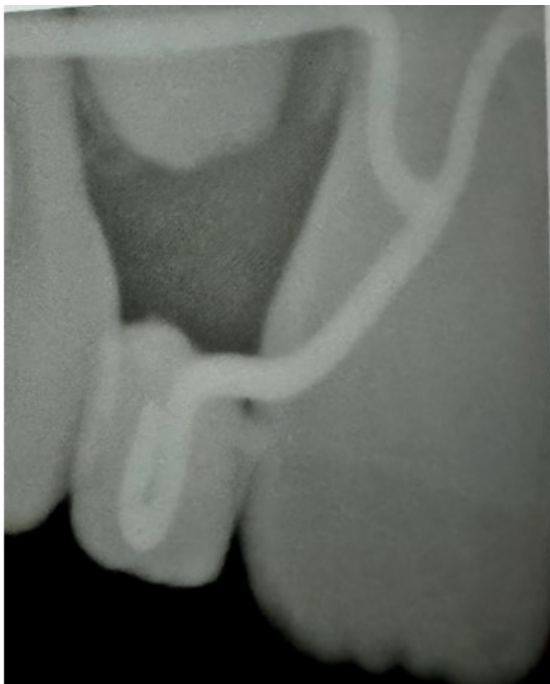


Figure 7. Radiograph showing luxatemp tooth incorporated with finger spring

## DISCUSSION

Immediately addressing the loss of deciduous teeth minimises the potential implications of malocclusion, which in turn requires expensive future treatment. Interceptive orthodontics measures has to be undertaken when signs and symptoms of malocclusion have appeared, to prevent potential malocclusion progressing into more severe form<sup>4</sup>. In the present case, early loss of deciduous upper lateral incisors was main cause for space loss leading to midline diastema between central incisors. If not corrected promptly, palatal eruption of lateral incisors and crossbite occurrence is undoubted. The goal of the interceptive orthodontic treatment in the present case included space regaining and midline closure with prosthetic rehabilitation to restore esthetic functions, improving speech, and restoring emotional and psychological well-being of the child<sup>2,4</sup>. In the present case available space was lesser for eruption of 22 into right place. RVG revealed no bone coverage but soft tissue covering 4mm.

Considering the factors; age of the patient (6 years), physiological eruption of permanent lateral incisors (7-8 years) and loss of space, space regainer as well as functional maintenance of space until the eruption of lateral incisor was considered. This appliance is handy and advantageous as it is a single appliance which can be modified to use as space regainer and maintainer as well with the simple fabrication and cost effective. Fixed appliances are more accepted by both patient and the parent compared to removable appliances.

Fixed space retainers has advantages of reduced treatment time, better compliance from patients as not required to remove and clean the appliance, less chances of distortion and reduced chances of swallowing the appliance by the younger children<sup>5</sup>. However, fixed space maintainers which usually lack functional ability of space maintainers unlike removable appliances<sup>6</sup>. In this case, a novel modification of nance palatal arch space maintainer was made with incorporation of finger spring until the desired mesiodistal space was achieved and the same appliance was then modified for functional space maintainer by bending the finger spring parallel to the long axis of the adjacent central incisor and incorporating customized luxatemp crown into the shape of lateral incisor. The luxatemp is a bis-acrylic composite resin material with good flexural strength, better colour and dimensional stability. With its added advantage of different shades availability makes it suitable for a temporary crown replacement as pontic<sup>7,13</sup>.

The advantage of this dual appliance is the simple modification that allows space regainer and replacement to maintain space till eruption with reduced time duration and multiple fabrication and prevent multiple visit. Disadvantage of the appliance includes chances of breakage of the wire, hypoplasia of gingival tissue under the acrylic button and hypomineralization of the bonded molars<sup>8</sup>. The other treatment options of the space regainer followed by surgical exposure was ruled out as the stage of root being formed was less than 1/3<sup>rd</sup> and to avoid more chances of ectopic eruption with inadequate surgical skill of the dentist. As a pediatric dentist, occlusal guidance diagnosis is a major milestone in preventing further possibilities developing malocclusion due to early loss of teeth and treating on right time is the key to prevent and intercept any forthcoming malocclusion.

## REFERENCES

1. Nadelman P, Magno MB, Pithon MM, CASTRO AC, Maia LC. 2021. Does the premature loss of primary anterior teeth cause morphological, functional and psychosocial consequences?. *Brazilian oral research*. Nov 19;35:e092.
2. Bansal M, Gupta N, Gupta P, Arora V, Thakar S. Reasons for extraction in primary teeth among 5-12 years school children in Haryana, India-A cross-sectional study. *Journal of clinical and experimental dentistry*. 2017 Apr;9(4):e545.
3. Losso EM, Tavares MC, da Silva JY, Urban CD. Severe early childhood caries: an integral approach. *Jornal de pediatria*. 2009;85:295-300.
4. Tunison W, Flores-Mir C, ElBadrawy H, Nassar U, El-Bialy T. Dental arch space changes following premature loss of primary first molars: a systematic review. *Pediatric dentistry*. 2008 Jul 1;30(4):297-302.

5. Rajab L, Murad E, Abu-Ghazaleh S. Interceptive and orthodontic treatment provided by pediatric dentists in Jordan. *Jordan Medical Journal*. 2022 Oct 16;56(4).
6. Abdin M, Abdelgadir Ahmed EE, Hamad R, Splieth CH, Schmoeckel J. Success rates and failures of fixed and removable space maintainers after the premature loss of primary molars. *Quintessence International*. 2024 Apr 1;55(4).
7. Savitha Sathyaprasad DA. Rehabilitation of Badly Broken Anterior Teeth in Early Childhood Caries Byluxatemp: Case Report
8. Arbildo-Vega HI, Oliva JC, Durand RC, Alva JA, Alvarado AR, Vásquez H. Survival rate of fixed space maintainers used in Dentistry. Systematic review and Meta-analysis. *Journal of Oral Research*. 2021;10(6):1-0.
9. Kirtaniya BC, Singla A, Gupta KK, Khanna A, Kaur G. Space Regainer Cum Space Maintainer-A New Appliance For Paediatric Dentistry. *Indian Journal of Dental Sciences*. 2014 Sep 1;6(3).
10. Metin-Gursoy G, Tortop T. A New Perspective on the Relationship Between Anchorage and Palatal Morphology: Three-Dimensional Digital Model Analysis. *Nigerian Journal of Clinical Practice*. 2022 Oct 1;25(10):1666-73.
11. Arikan V, Kizilci E, Ozalp N, Ozcelik B. Effects of fixed and removable space maintainers on plaque accumulation, periodontal health, candidal and Enterococcus faecalis carriage. *Medical Principles and Practice*. 2015 Jun 4;24(4):311-7.
12. Chu CH, Mei L. Heat treatment during setting on properties of resin-based provisional-restorative materials. *Dental Materials*. 2014.
13. Vignesh KC, Kandaswamy E, Muthu MS. A comparative evaluation of fracture toughness of composite resin vs protemp 4 for use in strip crowns: an in vitro study. *International Journal of Clinical Pediatric Dentistry*. 2020 Jan;13(1):57.

\*\*\*\*\*