



RESEARCH ARTICLE

CROSSED K-WIRE FIXATION OF DISPLACED SUPRACONDYLAR FRACTURES OF THE HUMERUS IN CHILDREN: OUTCOMES AND IMPLICATIONS OF DELAY IN PRESENTATION

*Nuradeen Altine Aliyu and Ibrahim Salihu Gada

Department of Orthopaedics and Trauma, Usmanu Dan Fodio University Teaching Hospital, Sokoto, Nigeria

ARTICLE INFO

Article History:

Received 20th June, 2024
Received in revised form
19th July, 2024
Accepted 19th August, 2024
Published online 30th September, 2024

Key words:

Supracondylar Fracture humerus, Crossed K-wire, Delayed Presentation. Fractures in Children.

*Corresponding author:

Nuradeen Altine Aliyu

ABSTRACT

Background: Supracondylar fracture of the humerus in children is one of the most common fractures in children with peak age of occurrence from 5 to 8 years. The time of presentation and intervention of the displaced fracture greatly determine the treatment outcome. The study aims to report the outcome and implications of delayed presentation in the treatment of displaced supracondylar fractures of the Humerus in children in 63 patients. **Methods:** This a retrospective study of 63 paediatric patients with closed and displaced supracondylar fractures of the humerus who presented to orthopaedic hospital Wamakko between March 2015 and January 2022. The patients' data were obtained from the previous records and information during clinic visits while on follow-up. History and examination findings were extracted using a proformer. Radiographs were taken to determine the Gartland fracture type, Baumann's angle, carrying angle, and reduction sufficiency. The outcomes of these measurements and assessments were determined using Flynn's criteria. **Results:** The average follow-up time was 2.6 years (range 1.5 to 3.2 years). Out of the 63 cases in the study, the peak age range of presentation was 5 to 8 years with 34(54%) patients. There were 44(70%) males and 19 (30%) females with a male-to-female ratio of 2.3:1. The right sides affected were 38(60%) and left side 25(40%). The presentation time from the injury ranges from within 24 hours to 4 weeks: 16 (25%) presented within 24 hours of injury, 7(11%) between 25 and 48 hours, 11(18%) between 26 and 72 hours, 14(22%) between 4 to 7 days, 9(14%) between 1 and 2 weeks, and 6(10%) between 3 and 4 weeks. Fall on outstretched hand (FOOSH) was found in 61(97%) patients and those with elbow in flexion were found in 2(3%) patients. Twenty-seven (43%) had Gartland type 2, and 36(57%) had Gartland type 3. According to Flynn's score 32(51%) were excellent, 21(33%) good, 7(11%) fair and 3(5%) poor. Complications at presentation were 11(17%) elbow stiffness, 3(5%) nerve palsy, and 1(2%) compartment syndrome. Fifty-one patients (81%) had percutaneous K-wire fixations, and 12(19%) patients had open reduction and K-wire fixations. The postoperative period was uneventful in 45(71%) patients while 8(13%) had Elbow stiffness, 5(8%) had wound infection, 2(3%) had nerve palsy, 2(3%) had mal-union (cubitus varus), and 1(1%) had fracture non-union. **Conclusion:** Crossed K-wire fixation of displaced supracondylar fractures in children provides a stable and safe treatment method with satisfactory outcomes, especially among patients with early and timely presentations.

Copyright©2024, Nuradeen Altine Aliyu and Ibrahim Salihu Gada. This is an open access article distributed under the Creative Commons Attribution License, which permits unrestricted use, distribution, and reproduction in any medium, provided the original work is properly cited.

Citation: Nuradeen Altine Aliyu and Ibrahim Salihu Gada. 2024. "Crossed k-wire fixation of displaced supracondylar fractures of the Humerus in children: outcomes and implications of delay in presentation". *International Journal of Current Research*, 16, (09), 29752-29757.

INTRODUCTION

Supracondylar fractures of the humerus in children occur at the distal end of the humerus on the weakest point where the lateral column merges with the olecranon fossa (1). It has an incidence of 3 to 18% and is the second most common fracture in children after radius and ulnar fractures (2). The peak age of occurrence is usually 5 to 8 years and is attributed to increased and frequent falls among the paediatric age group (3). Variations may exist in the reported age incidence of supracondylar fractures in children depending on the study

reports (2,3). However, the peak incidence remains largely between four to seven years (31.2%) and three to six years (53.6%) age group (3,4). The time of presentation varies, but most patients present early, especially in the developed nations where full awareness and accessibility to healthcare services are not an issue. The challenge usually lies in the late presentation, particularly with a fracture type that is associated with neurovascular, bony and soft tissue complications around the elbow (5). The fracture classification is based on injury severity and fracture displacement according to Gartland (6) who classified the fracture into type 1 which is undisplaced, type 2 displaced with intact posterior hinge, and type 3 which

is completely displaced. Neurovascular complications are commonly found in displaced fractures with involvement of radial nerve in 28% of cases and brachial artery in 10 to 20% of cases (7). Supracondylar fractures in children can generally be managed operatively or non-operatively depending on the displacement status as classified by Gartland and also the presence or absence of neurovascular problems (6,8). Non-operative treatment is indicated for non-displaced fractures whereas operative management which entails either closed or open reduction with Kirshner (K) wire pinning is indicated in failed closed reduction, displaced fractures, fractures with vascular or neurological complications, and late presentation (9).

For patients that fall into the operative category, closed reduction and percutaneous K-wire fixation are safer with fast recovery and fewer postoperative complications (9,10). Presentations, defined more than 2 days after injury are regarded as a late presentation, and the treatment options according to some studies include continuous traction of the injured limb which leads to prolonged hospitalisation (11,12) or they are left alone to malunion, and later a corrective osteotomy is done (13). Delay in presentation could be a factor in missing the advantage a closed reduction offers, because any undue delay in presentation may have to be treated with open reduction and K-wire fixation with all its attendant complications.

S. Aliet al. in their study offunctional outcome following closed reduction and percutaneous pinning and open reduction and pinning in displaced supracondylar fractures of the humerus in children reported an average time to union of 5.71 weeks in the percutaneous pinning group to be significantly better than in an open reduction group with average 6.88 weeks to fracture union (14). Currently, there is a paucity of reports on the outcomes of delayed treatment of displaced supracondylar fractures in children especially in settings where late presentation is rarely seen. The need to highlight the implications of delayed treatment in these patients as compared to early presentation and treatment is important for a change in the affected society for a call to early presentation of these cases. The study aims to report the outcome and implications of delayed presentation in the treatment of displaced supracondylar fractures of the Humerus in children in 63 patients.

Table 1. Flynn's score criteria (15)

| Results | Rating | Loss of carrying angle | Loss of motion |
|----------------|-----------|------------------------|----------------|
| | Excellent | 0°-5° | 0°-5° |
| Satisfactory | Good | 5°-10° | 5°-10° |
| | Fair | 11°-15° | 11°-15° |
| Unsatisfactory | Poor | >15° | >15° |

MATERIALS AND METHODS

This a retrospective study of 63 paediatric patients with closed and displaced supracondylar fractures of the humerus who presented to orthopaedic hospital Wamakko between March 2015 and January 2022. Ethical approval (with Ref no. SMH/1580/V.IV) was obtained from the Ministry of Health, Sokoto, Nigeria before the commencement of the study. The inclusion criteria were paediatric patients aged between 3 and

16 years, closed displaced supracondylar fracture of the Humerus, duration of presentation from within 24 hours to 4 weeks of injury, and both genders. Exclusion criteria were open fracture, undisplaced fracture, and neglected fracture with more than 4 weeks of presentation. The patients' data were obtained from the previous records and information during clinic visits while on follow-up. History and examination findings were extracted using a proformer; the patient's age, gender, mechanism of injury, examination of the injured part particularly noting the vascular and neurological complications, type of surgery performed, follow-up period, range of motion, and complications were recorded (Figure 1a).

Radiographic evaluation with an anteroposterior (AP) and lateral views of the affected elbows (Figures 1b & 3a) were done to determine the Gartland fracture type, Baumann's angle, carrying angle, and reduction sufficiency. The outcomes of these measurements and assessments were determined using Flynn's criteria (Table 1)(15). Laboratory investigations data as preoperative routine investigations were collected from the record and they include Complete blood count (CBC) and other screening tests for patients' optimisation before the surgery. The anaesthesia was general anaesthesia to achieve full relaxation with the patient in a supine position with the affected arm fully draped and free on the arm board. The insertion sites were on the medial and lateral epicondyles of the humerus.

A 1 cm incision was performed at each K wire insertion site, followed by continuous dissection to avoid tendon and neurovascular lesions. The K-wire sizes used were between 2 mm and 2.5 mm in diameter for smaller and larger children, respectively. Longitudinal traction was applied with counter-traction followed by finger hyper-flexion while maintaining the traction. Finger pressure could be applied to further reduce the displaced fracture, particularly at the olecranon tip. The K-wire was manually passed through the epicondyle and passed in a crossed manner fashion to hold the fracture in place. An intraoperative image guide was used to check the fracture reduction and the K-wire placements.

Then, the elbow was slightly extended to 90° of flexion, and vascular assessment was done distally to ascertain continuous blood flow. For those patients who presented late (mostly around 2 to 4 weeks), open reduction was employed through the anterior elbow approach. In patients with flexion-type injury (n=2), following longitudinal traction on the affected limb to reduce the fracture, K-wire was passed through both epicondyles while the elbow remained fully extended, and this was the final position of splintage until the fracture healed. Finally, the K-wires were bent and cut and left externally exposed for subsequent removal after fracture union. Then, above the elbow back-slab Plaster of Paris (POP) was applied to further add to the fracture reduction and stability. The arm was immobilised with a collar and cuff bandage. Postoperative management continued with arm elevation and closed monitoring of vital signs. The discharge time was usually on the 3rd to 5th days postoperatively, and outpatient visits were scheduled at 6 weeks, 3 months, 6 months and 1 year after operation. Serial radiographs (Figure 3b) were taken during the follow-up visits to assess fracture union and elbow functions. The crossed k-wires were removed at an average of 6 weeks postoperatively (Figures 3c & 3d).

Table 2. Demographic and clinical characteristics (n=63)

| Characteristics | Frequency (%) |
|---------------------------------------|---------------|
| Age | |
| <5yrs | 5(8%) |
| 5-8yrs | 34(54%) |
| 9-12yrs | 18(29%) |
| 13-16yrs | 6(9%) |
| Sex | |
| Male | 44(70%) |
| Female | 19(30%) |
| Side(Laterality) | |
| Right | 38(60%) |
| Left | 25(40%) |
| Duration of presentation | |
| <24hrs | 16(25%) |
| 24-48hrs | 7(11%) |
| 49-72hrs | 11(18%) |
| 4-7 days | 14(22%) |
| 1-2 weeks | 9(14%) |
| 3-4 weeks | 6(10%) |
| Injury type | |
| Extension type (FOOSH) | 61(97%) |
| Flexion type (Direct trauma) | 2(3%) |
| Gartland type | |
| Type I | 0(0%) |
| Type II | 27(43%) |
| Type III | 36(57%) |
| Complications at presentation | |
| None | 48(76%) |
| Elbow stiffness | 11(17%) |
| Nerve palsy | 3(5%) |
| Compartment syndrome | 1(2%) |
| Open vs. Percutaneous fixation | |
| Percutaneous | 51(81%) |
| Open | 12(19%) |
| Postoperative complications | |
| None | 45(71%) |
| Elbow stiffness | 8(13%) |
| Wound infection/PTI | 5(8%) |
| Nerve palsy | 2(3%) |
| Mal-union (CubitusVarus) | 2(3%) |
| Non-union | 1(1%) |

hrs=years, hrs=hours, PTI=pin tract infection FOOSH
 =Fall on outstretched hand

RESULTS

The demographic and essential clinical characteristics were summarised in Table 2. The average follow-up time was 2.6 years (range 1.5 to 3.2 years). Out of the 63 cases in the study, the peak age range of presentation was 5 to 8 years with 34(54%) patients. There were 44(70%) males and 19 (30%) females with a male-to-female ratio of 2.3:1. The right sides affected were 38(60%) and left side 25(40%). The presentation time from the injury ranges from within 24 hours to 4 weeks: 16 (25%) presented within 24 hours of injury, 7(11%) between 25 and 48 hours, 11(18%) between 26 and 72 hours, 14(22%) between 4 to 7 days, 9(14%) between 1 and 2 weeks, and 6(10%) between 3 and 4 weeks. Fall on outstretched hand (FOOSH) was found in 61(97%) patients and those with elbow in flexion were found in 2(3%) patients. Twenty-seven (43%) had Gartland type 2, and 36(57%) had Gartland type 3. According to Flynn's score (Table 1 and 4), 32(51%) were excellent, 21(33%) good, 7(11%) fair and 3(5%) poor. In terms of complications at presentation, 48(76%) of patients presented without complications while 11(17%), 3(5%), and 1(2%) of patients presented with elbow stiffness, nerve palsy and compartment syndrome respectively. Fifty-one patients (81%) had percutaneous K-wire fixations, and 12(19%) patients had open reduction and K-wire fixations. The postoperative period (table 3) was uneventful in 45(71%) patients while 8(13%) had Elbow stiffness, 5(8%) had wound infection/PTI, 2(3%) had

nerve palsy, 2(3%) had mal-union (cubitusvarus), and 1(1%) had fracture non-union. Out of the 8(13%) patients with elbow stiffness, 1 patient who presented in the 4th week post-injury had heterotopic ossification. Among those patients who presented within the first 48hours of injury had no postoperative complications, only 1 had elbow stiffness among those who presented within 49 to 72hours, 3 patients within 4 to 7 days of injury, and the majority of those with postoperative complications presented within 2 to 4 weeks after the injury (Table 3).

Table 3. Presentation time vs. Outcome

| Presentation | No.(%) | Avg Union time | Complications |
|--------------|---------|----------------|-----------------------------------------------------------|
| <24hrs | 16(25%) | 6wks | None |
| 24-48hrs | 7(11%) | 6wks | None |
| 49-72hrs | 11(18%) | 6.4wks | Elbow stiffness(1) |
| 4-7 days | 14(22%) | 6.7wks | Elbow stiffness(2), PTI(3) |
| 1-2 weeks | 9(14%) | 7.5wks | Elbow stiffness(3), PTI (1),N. palsy(1),Mal-union(1) |
| 3-4 weeks | 6(10%) | 8.3wks | Elbow stiffness(3), PTI (1), Nerve palsy(1), Non-union(1) |

Table 4. Final results according to Flynn's score

| Results | Rating | Number (%) |
|----------------|-----------|------------|
| Satisfactory | Excellent | 32(51%) |
| | Good | 21(33%) |
| | Fair | 7(11%) |
| Unsatisfactory | Poor | 3(5%) |

DISCUSSION

The peak age in most literatures ranges from 5 to 8years, this is closely related to our findings of 54% of patients who presented within the same age range of 5 to 8 years (16). In terms of sex incidence, the majority of our cases were male patients with a male-to-female ratio of 2.3 to 1. This is the usual finding in many studies showing boys preponderance over girls (17). Some reports showed a higher incidence among girls by a narrow margin (18). Reasons for higher incidence among boys in our study could be because of involvement in vigorous activities by the male genders in our settings. The side that was most affected was on the right arm and this corresponds to the dominant upper limb in most of them. The mechanism of injury was FOOSH on the extended elbow in 61(97%) patients as against the direct trauma to the flexed elbow in 2(3%) patients. This coincided with the FOOSH as the most common injury mechanism in 97 to 99% of cases in nearly all the related studies (19). Flynn's score criteria (Table 1) were used to evaluate and finally report our findings (Table 4). The classification is very pertinent because the presence of cubitusvarus deformity falls under poor results whatever will be the outcome of elbow function. Our treatment outcomes were 32(51%) were excellent, 21(33%) good, 7(11%) fair and 3(5%) poor. The 3 poor results were from 2 patients with cubitusvarus due to treatment offered at a late presentation and 1 patient with non-union associated with postoperative infection. One of the striking features in our study is the variation in times of presentation. This has greatly influenced the outcome because those with early presentation did not have significant postoperative complications as opposed to patients who presented late within weeks of the initial injury. Most of the postoperative complications including joint stiffness, heterotopic ossifications, wound infections, nerve palsy, mal-union and non-union were attributed to the delay in presentation (20).

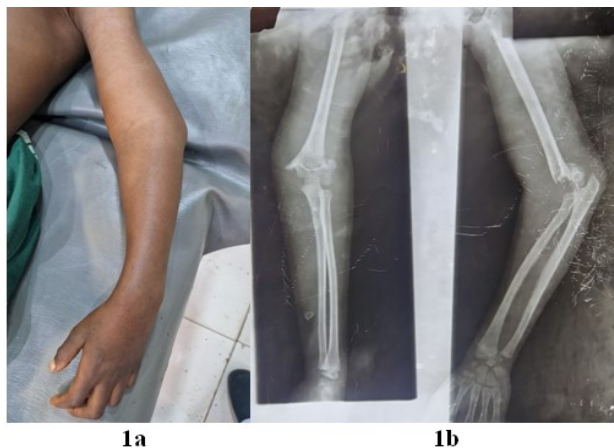


Figure 1. A 9 year old female patient with 16 hour injury to the left elbow (1a). Xray (1b) showed displaced supracondylar fracture of the humerus

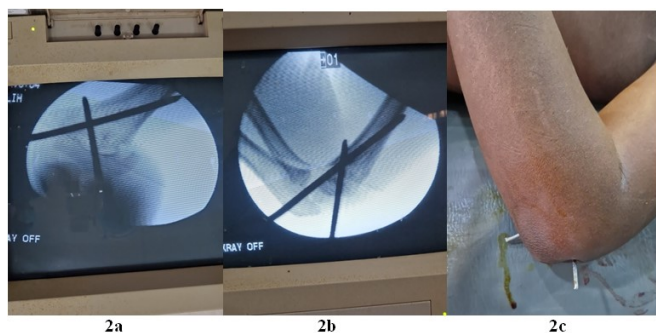


Figure 2. Intra-operativeradiographs (2a & 2b), and post-fixation clinical picture (2c) of a 9 year old female patient with supracondylar fracture of the left humerus

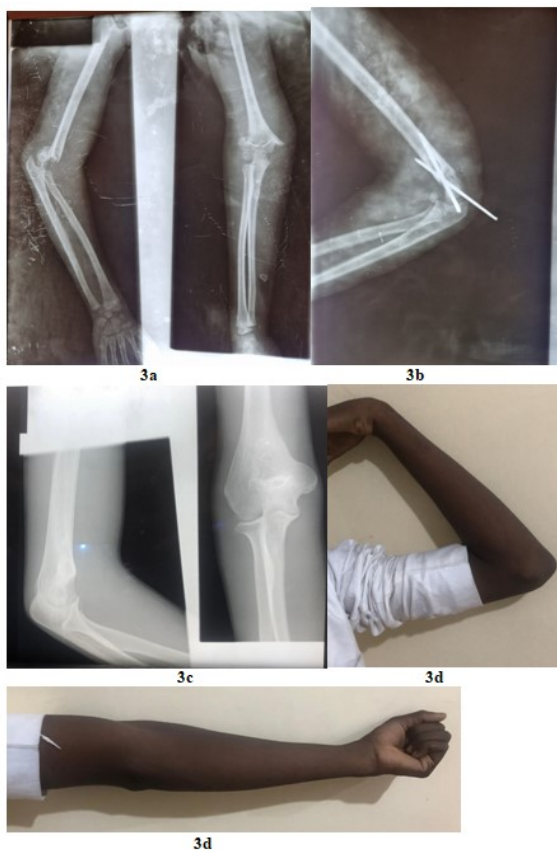

Figure 3. A 16 year old male with a displaced supracondylar fracture of the left humerus (3a), had crossed k-wire fixation and presented at 6 weeks postoperatively (3b). He later presented with a united fracture (3c) 2 years post-fixation showing satisfactory elbow function (3d).

With the fracture healing already setting in before the presentation, the closed reduction becomes nearly impossible to achieve, especially without risking the surrounding structures' integrity. More so, complications that may be associated with fracture at an early stage were presented late adding further challenges in managing both the fracture and the associated complications. Gartland type 1 fracture was excluded in the study because all our patients had displaced fractures either Gartland type 2 or 3 that required K-wire fixation. The justification for crossed K wire fixation in these patients has been reported by many studies as the best form of treatment particularly for stability (21). The recent publication by Zhu D et al, reported the outcome of conservative versus surgical treatment of Gartland type 2 supracondylar humeral fractures in children, even though they found no statistical differences between the two groups in fracture healing time and Flynn score, the conservative treatment was discovered to be superior to surgical treatment in functional recovery times (22).

Although, some literature reported successful non-operative management in some selected Gartland type 2 fractures, in our study, 15(24%) patients presented after 1 week of injury; 12 (19%) out of these 15 patients had to undergo open reduction before the final stabilisation. Gartland type 4 fractures have been described and can only be diagnosed intra-operatively. It is characterised by completely torn periosteum which leads to a high fracture instability (23). Whether with closed or open reduction method, all our 63 patients had crossed k wire fixations. This method of fixation has been shown to be safe, dynamically strong and stable, and has been employed by many surgeons with excellent postoperative outcomes (21,24). Two parallel k wires passed laterally through the lateral epicondyle has been equally a reliable method of supracondylar displaced fracture fixation in children with great success and has been the first choice of treatment method by many paediatric orthopaedic practitioners as reported by Ladenhauf HN et al. (25). This method may compromise stability in the medial column, and this has to be addressed by passing extra pin through the medial epicondyle to achieve stability with the attendant risk of ulnar nerve injury as reported the same study. We did not consider incorporating patients with more than 4 weeks of fractures because union may have been partially achieved and was expected to consolidate at 4 to 16 weeks post-injury (26). There was a report in the literature on preferably leaving the malunited supracondylar fracture alone until the child reaches adolescence when a corrective osteotomy could be an option in the presence of unwanted elbow deformity for cosmetic and functional reasons. This is because the functional outcome in the presence of cubitusvarus may be acceptable in the presence of compensatory mild shoulder rotation (27).

The postoperative elbow joint stiffness represents an extension of preoperative stiffness in patients with late presentation. There were 8 cases with this complication, and among them, 1 with 4 weeks at presentation post-injury had associated heterotopic ossification (HTO) around the affected elbow joint. The use of prophylactic postoperative oral Indomethacin against HTO in patients with delayed presentation and subsequent open reduction may have contributed in preventing the development of HTO in other patients (28). The nerve palsies developed by the patients before presentation and after the procedure were all neuropraxia and have resolved within the range 8 to 12 weeks postoperatively.

Only one patient had non-union. He was a 16-year-old male child who presented 4 weeks post-injury and developed postoperative infection with poor compliance to treatment on discharge and irregular follow-up visits. Non-union in these fractures is rare, and a report by Wingfield JJ et al. did not find any case of non-union in the displaced supracondylar fracture of the humerus in children that were managed with open reduction and percutaneous pin fixation within the span of their literature search. (29). Although compartment syndrome is yet to be reported as a complication of postoperative pin fixation following displaced supracondylar fracture of the humerus in children (30), our study reported 1 patient who presented within the first 48 hours of injury with a tight local limb splint applied by traditional bone setters. An emergency preoperative assessment revealed compartment syndrome and the patient was immediately managed intra-operatively with fasciotomy and fracture fixation. The early intervention did not result in significant disabilities associated with Volkmann's ischaemic contracture. The surgical management of displaced supracondylar fractures in children using crossed k-wire fixation technique is reliable with satisfactory outcome particularly among patients with early presentation. The study was on 63 sample sized patients with an average 2.6 years postoperative follow-up, the use of a larger sample size and longer follow up time would however provide more validity and strength in the study. Although we used Flynn's score to determine the final outcomes of our study, carrying out a statistical analysis can further revalidate our findings.

Conflict of interest: There is no conflict of interest in the study

Funding: None

REFERENCES

- Uhl M. The Elbow and Forearm: Acquired Disorders. In *Pediatric Orthopedic Imaging* 2014 Nov 5 (pp. 187-221). Berlin, Heidelberg: Springer Berlin Heidelberg.
- Kumar V, Singh A. Fracture supracondylar humerus: a review. *Journal of clinical and diagnostic research: JCDR*. 2016 Dec;10(12):RE01.
- Vaquero-Picado A, González-Morán G, Moraleda L. Management of supracondylar fractures of the humerus in children. *EFORT open reviews*. 2018 Oct 1;3(10):526-40.
- Holt JB, Glass NA, Shah AS. Understanding the epidemiology of pediatric supracondylar humeral fractures in the United States: identifying opportunities for intervention. *Journal of Pediatric Orthopaedics*. 2018 May 1;38(5):e245-51.
- Bales JG, Spencer HT, Wong MA, Fong YJ, Zions LE, Silva M. The effects of surgical delay on the outcome of pediatric supracondylar humeral fractures. *Journal of Pediatric Orthopaedics*. 2010 Dec 1;30(8):785-91.
- Shenoy PM, Islam A, Puri R. Current management of paediatric supracondylar fractures of the humerus. *Cureus*. 2020 May;12(5).
- DeFranco MJ, Lawton JN. Radial nerve injuries associated with humeral fractures. *The Journal of hand surgery*. 2006 Apr 1;31(4):655-63.
- Tomaszewski R, Pethe K, Kler J, Rutz E, Mayr J, Dajka J. Supracondylar Fractures of the Humerus: Association of Neurovascular Lesions with Degree of Fracture Displacement in Children—A Retrospective Study. *Children*. 2022 Feb 24;9(3):308.
- Leung S, Paryavi E, Herman MJ, Sponseller PD, Abzug JM. Does the modified Gartland classification clarify decision making?. *Journal of Pediatric Orthopaedics*. 2018 Jan 1;38(1):22-6.
- Devkota P, Khan JA, Acharya BM, Pradhan NM, Mainali LP, Singh M, Shrestha SK, Rajbhandari AP. Outcome of supracondylar fractures of the humerus in children treated by closed reduction and percutaneous pinning.
- Devnani AS. Late presentation of supracondylar fracture of the humerus in children *ClinOrthopRelat Res* 2005;431:36–41.
- Tiwari A, Kanojia RK, Kapoor SK. Surgical management for late presentation of supracondylar humeral fracture in children. *Journal of Orthopaedic Surgery*. 2007 Aug;15(2):177-82.
- Wilson JA. Injuries of the elbow. In: *Watson-Jones fractures and joint injuries*. Vol II, 6th ed. Edinburgh: Churchill Livingstone; 2000;583–649.
- Ali S, Sarfraz AH, Nadeem RD, Sah RK, Nasir MB. Functional Outcome Following Closed Reduction and Percutaneous Pinning and Open Reduction and Pinning in Displaced Supracondylar Fractures of the Humerus in Children: A Single Center Study. *Annals of King Edward Medical University*. 2021 Nov 4;27(Special Issue (Jul-Sep)):434-9.
- Flynn JC, Matthews JG, Benoit RL. Blind pinning of displaced supracondylar fractures of the humerus in children: sixteen YEARS'EXPERIENCE with long-term follow-up. *JBJS*. 1974 Mar 1;56(2):263-72.
- Otsuka NY, Kasser JR. Supracondylar fractures of the humerus in children. *JAAOS-Journal of the American Academy of Orthopaedic Surgeons*. 1997 Jan 1;5(1):19-26.
- Khan MS, Sultan S, Ali MA, Khan A, Younis M. Comparison of percutaneous pinning with casting in supracondylar humeral fractures in children. *Journal of Ayub Medical College Abbottabad*. 2005;17(2).
- Houshian S, Mehdi B, Larsen MS. The epidemiology of elbow fracture in children: analysis of 355 fractures, with special reference to supracondylar humerus fractures. *Journal of orthopaedic science*. 2001 Jul;6:312-5.
- Cheng JC, Lam TP, Maffulli N. Epidemiological features of supracondylar fractures of the humerus in Chinese children. *Journal of Pediatric Orthopaedics B*. 2001 Jan 1;10(1):63-7.
- Walmsley PJ, Kelly MB, Robb JE, Annan IH, Porter DE. Delay increases the need for open reduction of type-III supracondylar fractures of the humerus. *The Journal of Bone & Joint Surgery British Volume*. 2006 Apr 1;88(4):528-30.
- Lee SS, Mahar AT, Miesen D, Newton PO. Displaced pediatric supracondylar humerus fractures: biomechanical analysis of percutaneous pinning techniques. *Journal of Pediatric Orthopaedics*. 2002 Jul 1;22(4):440-3.
- Zhu D, Wen Y, Wang Q, Son B, Feng W. Conservative versus surgical treatment of Gartland type II supracondylar humeral fractures in children. *Journal of Pediatric Orthopaedics B*. 2024:10-97.
- Yiğit Ş, Arslan R, Arslan H, Özkul E, Atic R, Akar MS. Predictive factors for the development of Gartland type IV supracondylar humerus fractures: a prospective clinical study. *ActaOrthopaedicaetTraumatologicaTurcica*. 2022 Nov;56(6):361.

24. Larson L, Firoozbakhsh K, Passarelli R, Bosch P. Biomechanical analysis of pinning techniques for pediatric supracondylar humerus fractures. *Journal of Pediatric Orthopaedics*. 2006 Sep 1;26(5):573-8.
25. Ladenhauf HN, Schaffert M, Bauer J. The displaced supracondylar humerus fracture: indications for surgery and surgical options: a 2014 update. *Current opinion in pediatrics*. 2014 Feb 1;26(1):64-9.
26. Hasler CC. Supracondylar fractures of the humerus in children. *European Journal of Trauma*. 2001 Feb;27:1-5.
27. Sanpera I, Salom M, Fenandez-Ansorena A, Frontera-Juan G, Pizà-Vallespir G. The fate of the malrotated elbow supracondylar fractures in children: is varus really a problem?. *International orthopaedics*. 2024 Jun;48(6):1453-61.
28. Atwan Y, Abdulla I, Grewal R, Faber KJ, King GJ, Athwal GS. Indomethacin for heterotopic ossification prophylaxis following surgical treatment of elbow trauma: A randomized controlled trial. *Journal of Shoulder and Elbow Surgery*. 2023 Jun 1;32(6):1242-8.
29. Wingfield JJ, Ho CA, Abzug JM, Ritzman TF, Brighton BK. Open reduction techniques for supracondylar humerus fractures in children. *JAAOS-Journal of the American Academy of Orthopaedic Surgeons*. 2015 Dec 1;23(12):e72-80.
30. Wingfield JJ, Ho CA, Abzug JM, Ritzman TF, Brighton BK. Open reduction techniques for supracondylar humerus fractures in children. *JAAOS-Journal of the American Academy of Orthopaedic Surgeons*. 2015 Dec 1;23(12):e72-80.
