



ISSN: 0975-833X

Available online at <http://www.journalcra.com>

INTERNATIONAL JOURNAL
OF CURRENT RESEARCH

International Journal of Current Research

Vol. 16, Issue, 05, pp.28268-28272, May, 2024

DOI: <https://doi.org/10.24941/ijcr.47175.05.2024>

RESEARCH ARTICLE

INDICATIONS AND COMPLICATIONS OF FUNCTIONAL ENDOSCOPIC SINUS SURGERY AT OTORHINOLARYNGOLOGY DEPARTMENT AT MUHIMBILI NATIONAL HOSPITAL

Fatuma. T. Kibao^{1,*} and Enica Richards²

¹Amana Regional Referral Hospital Dar es Salaam, Tanzania

²Muhimbili university of Health and Allied Sciences, Dar es Salaam, Tanzania

ARTICLE INFO

Article History:

Received 20th February, 2024

Received in revised form

25th March, 2024

Accepted 14th April, 2024

Published online 23rd May, 2024

Key words:

Complications, Endoscopic Sinus Surgery.

*Corresponding author:

Fatuma. T. Kibao

ABSTRACT

Background: Functional endoscopic sinus surgery is a minimally invasive technique used to restore sinus ventilation and normal function. FESS like any other surgery is also associated with both intra and post-operative complications. Due to lack of local data on FESS the burden on indication and complications of this procedure is not known, so this study will help to identify them and develop a local guideline for proper management of FESS. **Material and Method:** Descriptive cross sectional study hospital based study was conducted at Muhimbili National Hospital for 8 months from February 2022 to September 2022 and involved all patients who underwent FESS and consented. One hundred and twelve (112) patients were studied; were followed from admission, intra-operatively and four weeks post-operative for complications. Collected data was analyzed by SPSS version 23, to determine the complications, the proportion of all patients undergoing FESS and those with complications were calculated. Findings were presented using tables, graphs and text. **Results:** A total 112 patients who met inclusion criteria were enrolled in the study, comprising female 57(50.9%) and male 55(49.1%). The age ranged from 8 years to 77 years and majority belonged to age group 25-39 years. The indications for FESS were CRS without NP 49(43.8%), followed by CRS with NP 34(30.4%) and others 3(2.7%) which were, two (2) synechiae released with sinus opening and one(1) was sinus tumor excision. The complication rate was 8.1% whereby there was no intraoperative or major complications. The lead complication was crusts 3(2.7%) and the complication were decreased during the time of follow up where endoscopic toilet was done, though one(1) patient had synechiae till last week follow up scheduled for release later. **Conclusions:** The indications of functional endoscopic sinus surgery were similar to other studies where majority had chronic rhinosinusitis without nasal polyps. There were minor complications which were managed during the time of follow up with endoscopic toileting. So post-operative follow up is the main stay for reducing complications post operatively.

Copyright©2024, Fatuma. T. Kibao and Enica Richards. This is an open access article distributed under the Creative Commons Attribution License, which permits unrestricted use, distribution, and reproduction in any medium, provided the original work is properly cited.

Citation: Fatuma. T. Kibao and Enica Richards. 2024. "Indications and Complications of Functional Endoscopic Sinus Surgery at Otorhinolaryngology Department at Muhimbili National Hospital". *International Journal of Current Research*, 16, (05), 28268-28272.

INTRODUCTION

Functional endoscopic sinus surgery (FESS) is a minimally invasive, surgical technique, using an endoscope to restore the drainage and ventilation of the nasal cavity and paranasal sinuses. The concept of FESS is the removal of tissue obstructing the OMC and the facilitation of drainage while conserving the normal non-obstructing anatomy and mucous membrane. This operation has now become a well-established strategy, comprising several techniques, for the treatment of chronic rhino sinusitis refractory to medical treatment and is a set of minimally invasive surgical techniques which allow direct visual examination and opening of the sinuses(1-5).

It is a reliable method for treatment of many sinonasal diseases and advancement in the field, have allowed for less morbidity, improved patient comfort, and surgery in places that would have otherwise required more invasive and obviously more morbid approaches. The advantages of FESS is the avoidance of external facial scar, an early drainage of the affected sinuses, leading to an enhanced recovery and a reduced hospital stay (6-9). Functional Endoscopic Sinus Surgery is indicated in several conditions such as chronic sinusitis refractory to medical treatment, recurrent sinusitis, sinonasal polyps, sinus mucocele, excision of selected tumors, CSF leak closure, orbital decompression and others(3). Standard preparation for FESS involves general anesthesia with a regular end tracheal tube.

The procedure will involve insertion of adrenaline pack prior to, so as to decongest the nose, The following surgical steps are selectively performed according to patient disease, resection of the uncinatate process (uncinectomy), Middle meatal antrostomy, Anterior ethmoidectomy, Posterior ethmoidectomy, Frontal sinusotomy, Endoscopic septoplasty, Concha bullosa exenteration, Endoscopic polypectomy, Sphenoidectomy. After finishing the operation, light anterior nasal packing is inserted in the middle meatus and the nasal cavity(10,11). Even though FESS is considered to be minimally invasive and safe but as in any surgery complications may arise due to the closeness of many vital organs to the sinonasal region. These complications includes orbital hemorrhage ,loss of vision/blindness, diplopia, CSF leak ,meningitis, brain abscess, massive hemorrhage requiring blood transfusion, intracranial hemorrhage and direct brain trauma, anosmia, injury to internal carotid artery in sphenoid sinus, injury to nasolacrimal duct and epiphora (3). And minor complications such as; Periorbital ecchymosis, periorbital emphysema, post-operative epistaxis, post-operative infection: rhinitis orsinusitis, adhesions, stenosis of maxillary or frontal sinus opening, exacerbation of asthma, hyposmia, dental pain (12–14). This study therefore aims at determining the indications and complications of FESS among patients treated at MNH.Since there are no local data available, and so far in Tanzania FESS is mainly done at MNH by qualified super specialists, magnitude on indication and complications of this procedure at our setting is not known.So far there is no study on indications and complications of FESS in Sub-Saharan Africa to show the magnitude of this procedure so there is a need of this study.

METHODOLOGY

This study was conducted at MNH-Otolaryngology department. MNH is a tertiary referral hospital with the ORL-department receiving ORL referral patients from all other regional and district hospital as well as other department at MNH. This was a descriptive, prospective, cross-sectional and hospital based study, conducted from February 2022 to September 2022 to all patients who underwent FESS for various indications. They consented and those who met inclusion criteria were enrolled in the study their history was taken, followed with ENT examination and CT-scan was mandatory for diagnosis and as operative map road during operation. Patient were followed intraoperatively to confirm diagnosis and any intraoperative complications and during the hospital stay. Follow up and data collection commenced from when the patient was enrolled in the study throughout operation and hospital stay until discharged by using a structured checklist .The data collected were coded and entered in a Statistical Package for Social Science (SPSS) version 23-computer software program for analysis. Data cleaning was done. Categorical variables were summarized using frequency along with percentage. Continuous variables were presented in the table and their frequencies and percentage was calculated, findings were presented using tables and text.

RESULTS

A total of 112 patients were enrolled into the study. The age group ranged from 8-77 years with median age 35.5 years and SD 16.7 years and majority of patient were 25-39(34.8%) years and least group was <10(0.9%) years.

Table 1. Age and sex distribution N=112

Character	N	%	
Age in years	<10	1	0.9
	11-24	26	23.2
	25-39	39	34.8
	40-54	25	22.3
	55-69	16	14.3
	70+	5	4.5
	Total	112	100
Sex	Male	55	49.1
	Female	57	50.9
	Total	112	100

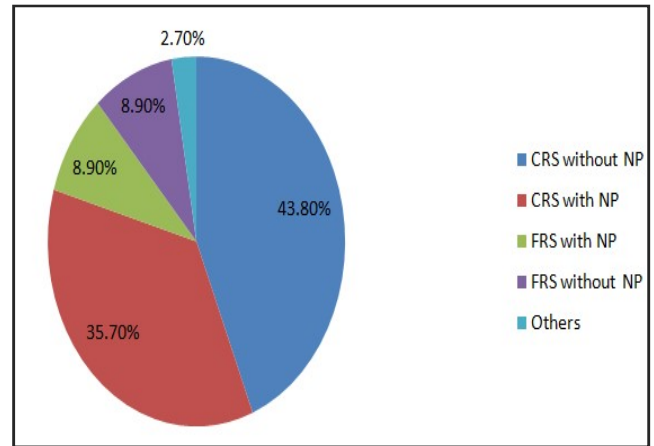


Figure 1. Indications of FESS

There was no statistical different in sex of participants.(Table 1). Figure 1 Shows the indications of FESS among participants who underwent FESS. Chronic sinusitis without nasal polyps was higher 49 (43.8%) followed by chronic sinusitis without nasal polyps 40 (35.7%) least were others 3(2.7%).

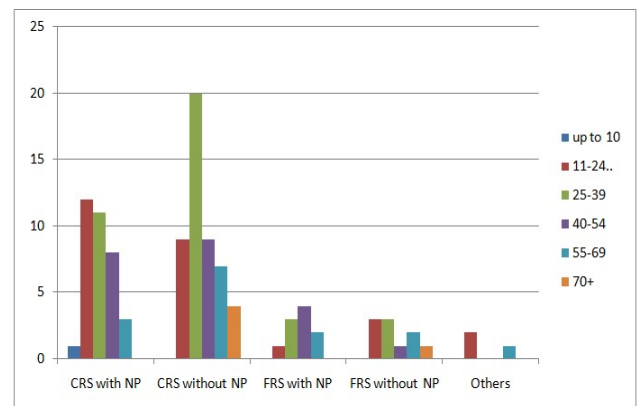


Figure 2. Indications of FESS by age N=112

Indications of FESS by age of patients was higher in the age groups of 25-39 (34.8%) years and the commonest was CRS without NP (51.3%) while the age group of <10 years had lower indications 0.9 % (Figure 2). Males had higher indications on CRS without NP (50.1%). And the least were seen in female on others (1.8% sinonasal tumor excision). During the study there was no intraoperative or major complication.9 (8.1%) patients had minor complications on first week and 1(0.9%) patient had on fourth week this was reduced by post-operative nasal irrigation and suction.

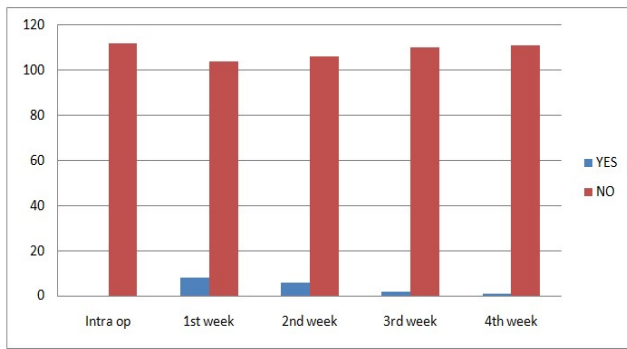


Figure 3. Complications of FESS

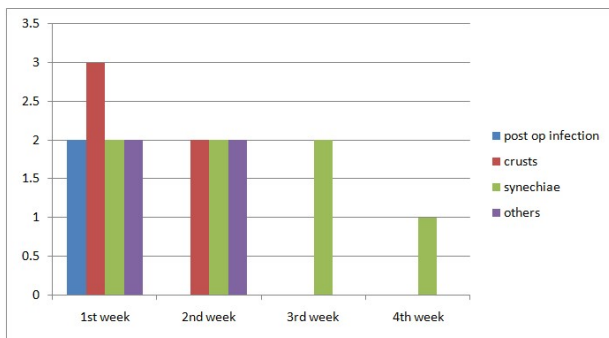


Figure 4. Complications of FESS

CRS without NP (51.3%) while the age group of <10 years had lower indications 0.9 % (Figure 2). The overall minor complications were 17(15%) where 9(8.1%) patients were seen at first week and 1(0.9%) at fourth week and synechia was most seen in (41.2%) patients

Table 1. Indications of FESS by sex

Sex	Indications		Total			
	CRS with NP	CRS without NP	FRS without NP	FRS with NP	Others	
Male	20(36.4%)	28(50.1%)	3(5.5%)	2(3.6%)	2(3.6%)	55(49.1%)
Female	20(35.7%)	21(36.8%)	7(12.3%)	8(14.1%)	1(1.8%)	57(50.9%)
Total	40(35.7%)	48(43.8%)	10(8.9%)	10(8.9%)	3(2.7%)	112(100%)

DISCUSSION

Functional endoscopic sinus surgery (FESS) is a minimally invasive, surgical technique to restore the drainage and ventilation of the nasal cavity and paranasal sinuses(15).The concept of FESS is the removal of tissue obstructing the OMC and the facilitation of drainage while conserving the normal non obstructing anatomy and mucous membrane(16–19). In this study, the indications and complications of FESS was assessed on 112 patients who met inclusion criteria and participated in the study. Among these females and males were almost equal in number, the reason for this could be that the indications of FESS affects equally both sexes (14). Patients age in this study ranged from 8 years to 77 years with median age of 35.5 years(SD 16.7years).This was similar to some studies(20) this explains that FESS is a relatively safe procedure in experienced hands in all age group. It can provide symptomatic relief for children with chronic sinusitis and other diseases(10). But this also was different to other studies that assess the efficacy of FESS in the treatment of primary and recurrent nasal polyposis and the other that looked at outcome after FESS,that they have to take adults patients((21,22).

The leading indications of FESS seen were CRS without NP, followed by CRS with NP then fungal RS with or without nasal polyps and others in small percentage which were 2 synechia release with sinusitis and one sinonasal tumor excision. This was similar to some studies (23). This also different to other studies that showed antrochoanal polyp being the leading indication (24) and also some studies looked at indications at symptomatic view rather than diagnosis (25) thus the indications results were different. Majority of patients were male at age group between 25-39 years and the lead was CRS without NP and the least group was >10 years.

This also was similar to some studies(20)and also was different to some studies that looked only at nasal polyps (22).and the sex with high indication was male due to male tendency of late seeking medical attention behavior ,though in majority of studies sex difference in indications was not documented since have no effects on the study (24). During the study there were no major or intraoperative complications, but minor was present to eight patients. This was similar to other study((20) and contrary to other studies which showed the presence of major complications due to large study population (23). The complications were more to male patients at the age range 40-54 years. And crusts was leading with three(3) patients and was cleared during follow up period. Synechia was released during follow up, though one patient had major synechia that was persisting till the ends of the study though was scheduled for release later. And this was similar to other studies (26). This was similar to a study that showed that complication rate was higher in patients with increased extent of disease and health-related quality of life and the presence of comorbidity (27).

This was contrary to another study that showed an exponential rise in the practice of functional endoscopic sinus surgery and a major complication rate of 0.23%(28,29).And another study that showed the ocular complications post FESS showed the overall complications occurred in 11 patients (0.66%), with minor complications of (0.3%) with the most frequent being periorbital ecchymosis and major complications seen in one patient (0.06%) with severe complications in 5 cases, the retro orbital hematoma, optic nerve injury and one case of extra ocular muscle injury(30).This was different with the study, where they found the overall complications to be 0.05% and there was major complications too by 0.38%(31).

CONCLUSION

In this study, 112 patients underwent functional endoscopic sinus surgery and was done in all age group and sex, the common indication was CRS without NP. There were no major complications in the study but minor complications of overall 1.8% and the leading was synechia due to inappropriate follow up and nasal irrigations. Functional endoscopic sinus surgery is reliable method for treatment of

many nasal diseases with acceptable incidence of minor complications. Most complications are transient and can be effectively managed by regular follow up and endoscopic examination. Post FESS follow is the main stay of reducing complications.

RECOMMENDATIONS

- Other studies with large sample size should be done.
- There is a need for having a local guideline on when and how to perform FESS and perioperative management
- There is a need for more specialists to be taught on how to perform this procedure and post-operative follow up management to meet the need.
- For the hospital where this procedure is performed; clinic facilities should include endoscopes for nasal examination and other necessary instruments for follow up.

Abbreviations: CRS-Chronic rhinosinusitis, FESS-Functional Endoscopic Sinus Surgery, NP-Nasal Polyps

REFERENCES

1. Tzifa KT, Skinner DW. Peri-orbital surgical emphysema following functional endoscopic sinus surgery, during extubation. *J Laryngol Otol.* 2001;115(11):916–7.
2. Chinwe R, Alazigha N. Egyptian Journal of Ear , Nose , Throat and Allied Sciences Computed tomography anatomy of the paranasal sinuses and anatomical variants of clinical relevants in Nigerian adults q. *Egypt J Ear Nose Throat Allied Sci.* 2017;18(1):31–8.
3. McMains KC. Safety in endoscopic sinus surgery. *Curr Opin Otolaryngol Head Neck Surg.* 2008;16(3):247–51.
4. Machado Alves Basilio F, Carlini Arantes M, Cristine Ballin A, Rafael Dallagnol M, Bohn Bornhausen M, Cavazzani Szkudlarek D, et al. Efficacy of Endoscopic Sinus Surgery in the Treatment of Chronic Rhinosinusitis Eficácia da Cirurgia Endoscópica Nasal no Tratamento da Rinossinusite Crônica. *Arch Otorhinolaryngol.* 2010;14(4):433–7.
5. Mafee MF, Chow JM, Meyers R. Functional Endoscopic Sinus Surgery: Anatomy, CT Screening, Indications, and Complications. *AJR.* 1993;160:735–44.
6. Becker SS. Surgical Management of Polyps in the Treatment of Nasal Airway Obstruction. *Otolaryngologic Clinics of North America.* 2009. p. 377–85.
7. Rudmik L, Soler ZM, Hopkins C, Schlosser RJ, Peters A, White AA, et al. Defining appropriateness criteria for endoscopic sinus surgery during management of uncomplicated adult chronic rhinosinusitis: a RAND/UCLA appropriateness study. *Int Forum Allergy Rhinol.* 2016;6(6):557–67.
8. Abdul-Malik Alnori H. Endoscopic Sinus Surgery: Indications and Complications. *Tikrit Med J.* 2013;19(1):89–94.
9. Alipanahi R, Sayyahmelli M, Sayyahmelli S. Ocular complications of functional endoscopic sinus surgery. *JPMA.* 2011;61(6):537–40.
10. Bublik M, Herman B, Younis R. Functional endoscopic sinus surgery. *YOTOT.* 2009;20:167–71.
11. Suzuki S, Yasunaga H, Matsui H, Fushimi K, Kondo K, Yamasoba T. Complication rates after functional endoscopic sinus surgery: Analysis of 50,734 Japanese patients. *Laryngoscope.* 2015;125:1785–91.
12. Tan BK, Lane AP. Endoscopic Sinus Surgery in the Management of Nasal Obstruction. *Otolaryngologic Clinics of North America.* 2009. p. 227–40.
13. Toros SZ, Bölükbası S, Naiboğlu B, Er B, Akkaynak C, Noshari H, et al. Comparative outcomes of endoscopic sinus surgery in patients with chronic sinusitis and nasal polyps. *Eur Arch Otorhinolaryngol.* 2007;264(9):1003–8.
14. Siedek V, Pilzweger E, Betz C, Berghaus A, Leunig A. Complications in endonasal sinus surgery: A 5-year retrospective study of 2,596 patients. *Eur Arch Otorhinolaryngol.* 2013;270(1):141–8.
15. Schick B. Functional Endoscopic Sinus Surgery. *Am Acad Fam Physicians.* 1998;58(3):707–18.
16. Al-Mujaini A, Wali U, Al-Khabori M. Functional Endoscopic Sinus Surgery: Indications and Complications in Ophthalmic Field. *Oman Med J.* 2009;24(2):70–80.
17. Kane KJ. The early history and development of endoscopic sinonasal surgery in Australia : 1985 – 2005. *Aust J Otolaryngol.* 2018;1:1–10.
18. Kennedy DW. Technical Innovations and the Evolution of Endoscopic Sinus Surgery. 2006;115(9):3–12.
19. Marta M. The history of paranasal sinus surgery. *Med Hist.* 2017;1(3):139–46.
20. Hemant Chopra, A.S. Khurana, Manish Munjal KD, Key. ROLE OF F.E.S.S. IN CHRONIC SINUSITIS. *Indian J Otolaryngol Head Neck Surg Vol.* 2006;58(2):137–8.
21. Khademi B, Gandomi B, Chohedri AH. ENDOSCOPIC SINUS SURGERY: RESULTS AT TWO YEAR FOLLOW-UP ON 200 PATIENTS. *Pak J Med Sci.* 2007;23(4):6–8.
22. Shahid Gohar M, Asif Niazi S, Baber Niazi S. Functional Endoscopic Sinus Surgery as a primary modality of treatment for primary and recurrent nasal polyposis. 380 *Pak J Med Sci.* 2017;33(2):380–2.
23. Smith LF, Brindley PC. Indications, evaluation, complications, and results of functional endoscopic sinus surgery in 200 patients. *OTOLARYNGOL HEAD NECK.* 1993;108:688–96.
24. Levine H I. Functiona Endoscopic Sinus Surgery:Evaluation,Surgery,and follow up of 250 patients. *Laryngoscope.* 1990;100:79–84.
25. Smith LF, Brindley PC. Indications, evaluation, complications, and results of functional endoscopic sinus surgery in 200 patients. *Am Acad Otolaryngol.* 1993;108(6):688–96.
26. Shivakumar T, Sambandan @bullet A P. Retrospective Analysis of the Effectiveness of Functional Endoscopic Sinus Surgery in the Treatment of Adult Chronic Rhinisinusitis Refractory to Medical Treatment. *Indian J Otolaryngol Head Neck Surg.* 2011;63(4):321–4.
27. Hopkins C, Browne JP, Slack R, Lund VJ, Topham J, Reeves BC, et al. Complications of surgery for nasal polyposis and chronic rhinosinusitis: The results of a national audit in England and Wales. *Laryngoscope.* 2006;116(8):1494–9.
28. V.L. C, R.M. S, I.S. M. Major complications of functional endoscopic sinus surgery. *Clin Otolaryngol Allied Sci.* 1994;19(3):248–53.
29. Vlastarakos P V., Fetta M, Segas J V., Maragoudakis P, Nikolopoulos TP. Functional endoscopic sinus surgery improves sinus-related symptoms and quality of life in

- children with chronic rhinosinusitis: A systematic analysis and meta-analysis of published interventional studies. *Clinical Pediatrics*. 2013. p. 1091–7.
30. Seredyka-Burduk M, Burduk PK, Wierzchowska M, Kaluzny B, Malukiewicz G. Ophthalmic complications of endoscopic sinus surgery PALAVRAS CHAVE. *Braz J Otorhinolaryngol*. 2017;83(3):318–23.
31. Suzuki S, Yasunaga H, Matsui H, Fushimi K, Kondo K, Yamasoba T. Complication rates after functional endoscopic sinus surgery: Analysis of 50,734 Japanese patients. *Laryngoscope*. 2015;125:1785–91.
