



ISSN: 0975-833X

Available online at <http://www.journalcra.com>

INTERNATIONAL JOURNAL
OF CURRENT RESEARCH

International Journal of Current Research
Vol. 15, Issue, 11, pp.26428-26431, November, 2023
DOI: <https://doi.org/10.24941/ijcr.46285.11.2023>

RESEARCH ARTICLE

REPLANTATION OF 3 AVULSED PERMANENT TEETH: CASE REPORT

¹Dr. Nidhi Kaushal, ²Dr. Surinder Kaur, ³Dr. Haridarshan Singh Sidhu and
⁴Dr. Jaspreet Kaur Tiwana

¹PG, Pediatric and preventive Dentistry, Department of Paediatrics and Preventive dentistry, Government Dental College & Hospital, Patiala; ^{2,3}Assistant Prof. & Head, Department of Paediatrics and Preventive dentistry, Government Dental College & Hospital, Patiala; ⁴Demonstrator, Department of Paediatrics and Preventive Dentistry, Government Dental College & Hospital, Patiala

ARTICLE INFO

Article History:

Received 20th August, 2023
Received in revised form
27th September, 2023
Accepted 15th October, 2023
Published online 28th November, 2023

Key words:

Avulsion, Delayed Replantation, Replacement Resorption.

*Corresponding author:

Dr. Surinder Kaur

ABSTRACT

Introduction: Dental avulsion is a serious dental injury which leads to complete displacement of the tooth out of the socket. Reimplantation is the most common and standard treatment for avulsed teeth. The success of the treatment depends upon the status of periodontium, including other factors such as extra-oral dry time, storage media and contamination. Delay in the replantation of avulsed teeth can increase the risk of ankylosis and resorption. **Case presentation:** This case report presented a 15-year-old boy with avulsion of 3 permanent teeth to a 1-year-follow up after the replantation of avulsed both maxillary central incisors and left lateral incisor with extra-oral dry time of more than 60 minutes. The avulsed teeth were managed throughout as per treatment guidelines. The teeth were replanted and splinted for four weeks. Two months after the replantation, there were signs of replacement root resorption in the replanted teeth. **Conclusion:** The treatment plan followed in this case has the advantage of maintaining the patient's esthetic appearance and function. On 1 year follow-up clinical and radiographic examination, the replanted teeth were showing signs of resorption.

Copyright©2023, Nidhi Kaushal et al. This is an open access article distributed under the Creative Commons Attribution License, which permits unrestricted use, distribution, and reproduction in any medium, provided the original work is properly cited.

Citation: Dr. Nidhi Kaushal, Dr. Surinder Kaur, Dr. Haridarshan Singh Sidhu and Dr. Jaspreet Kaur Tiwana. 2023. "Replantation of 3 avulsed permanent teeth: Case report". *International Journal of Current Research*, 15, (11), 26428-26431.

INTRODUCTION

Dental avulsion is a serious dental injury which leads to complete displacement of the tooth out of the socket. It accounts for 0.5-16% of all dental injuries^[1]. It generally occurs as a result of falls, fights, sports injuries, automobile incidents and child abuse^[2]. The teeth most commonly avulsed in both primary and permanent dentition are maxillary central and lateral incisors. Complications of avulsed teeth include pulp necrosis, internal/external root resorption, ankylosis, and loss of the periodontal ligament. The incidence of complications depends on several factors, namely, transportation/storage of the teeth, the time that elapses between avulsion and reimplantation, and splinting technique and time. Avulsed permanent teeth can be saved if replanted immediately or stored in a physiological solution, such as saline, milk or even saliva until professional help is obtained. However, if such proper first aid procedures are not provided, the tooth will be lost. The immediate and appropriate management of traumatically avulsed teeth provided after avulsion is critical for the long treatment. Delayed replantation can lead to external resorption or replacement resorption or ankylosis. The risk of infection and root resorption can occur after replantation at any time, which may affect the treatment outcome and prognosis.

CASE REPORT

A 15-year-old male patient, reported to the Department of Pediatric and Preventive Dentistry at Government Dental College and Hospital, Patiala, Punjab. The patient had fallen during morning assembly and hit his face on the floor resulting in dental trauma. There was a loss of consciousness for a few seconds and the patient was referred to a general physician, who had detected no neurological damage or medical complications. A clinical examination of the patient was done for any signs of intraoral and extraoral injury. The intraoral examination revealed that the maxillary permanent central incisors and left lateral incisor (11, 21 & 22) were avulsed. The patient found avulsed teeth after an hour of trauma and then report to the department 180 minutes after the fall with the avulsed teeth preserved in a small container filled with milk. The crowns of the avulsed teeth were intact, and the roots had closed apices. Intra-oral examination and pre-operative IOPA showed empty 11, 21 & 22 sockets and no signs of adjacent tooth or bone fracture. There was no relevant medical history. Since the extraoral dry time is more than 60 minutes, possible outcomes and prognosis of teeth were explained to the parent and patient. After administering local anesthesia, informed consent from the patient was obtained. The treatment plan was executed.

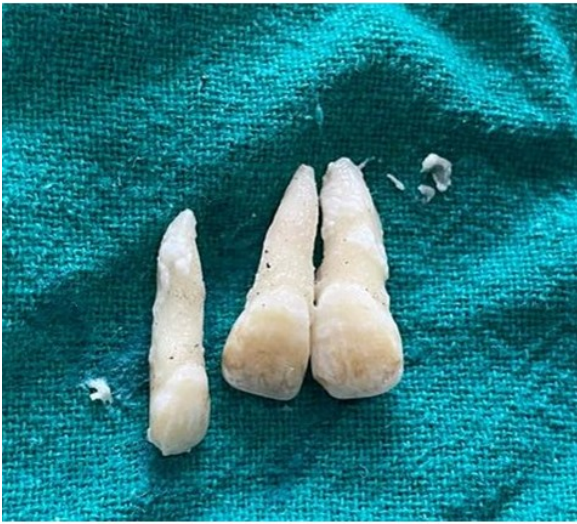

Figure 1. Avulsed teeth

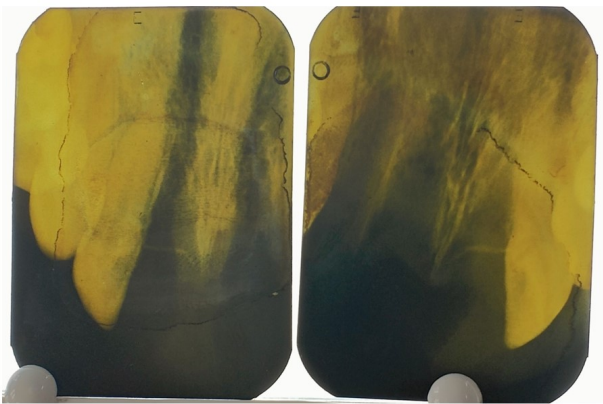


Figure 2. Pre-op IOPA showing no adjacent alveolar fracture

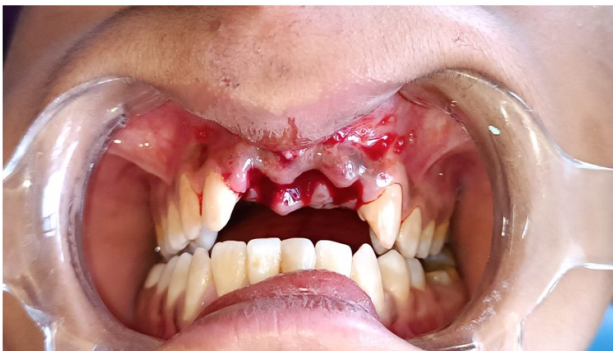

Figure 3. Pre-op picture showing avulsed maxillary central incisors and left lateral incisors

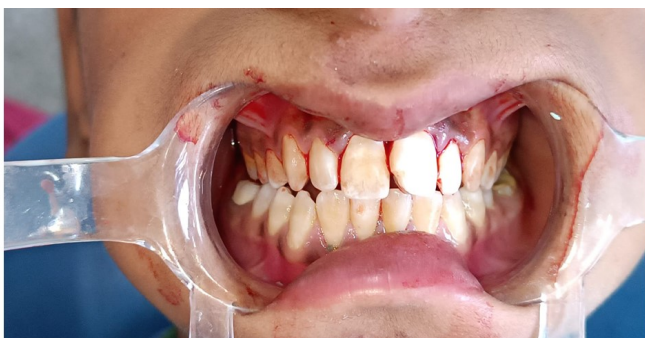

Figure 4. Positioning of avulsed teeth in the socket before splinting

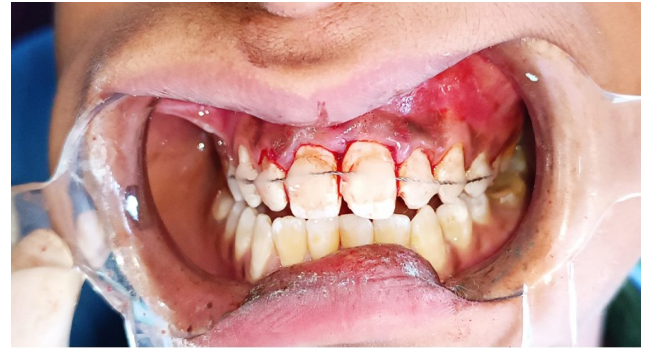

Figure 5. Splinting of avulsed teeth

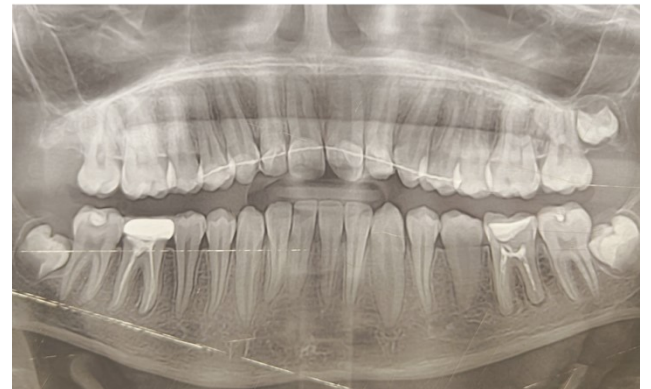


Figure 6. OPG after replantation and splinting of avulsed teeth

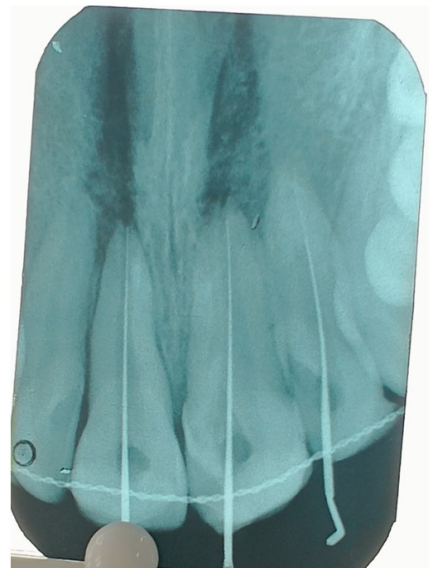

Figure 7. Working Length X ray (1st week after splinting)

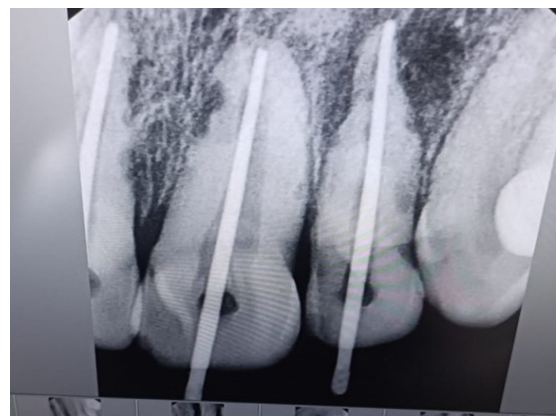

Figure 8. Two-months after replantation

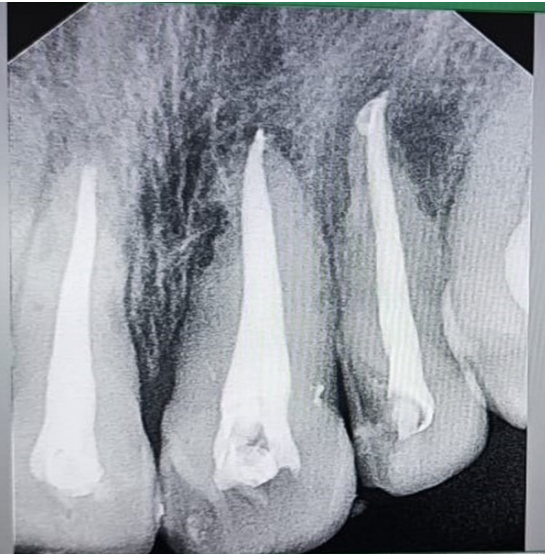

Figure 9. Three months after replantation (Calcium hydroxide as intracanal medicament)

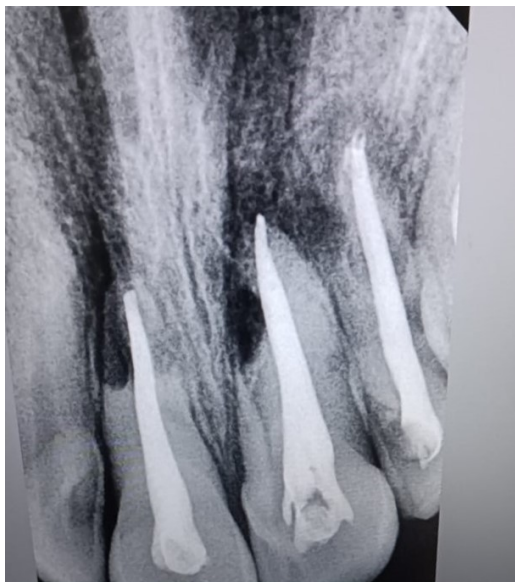

Figure 10. Six months after replantation

The roots and the sockets were cleaned gently with saline and the teeth were replanted into the socket with slight manual pressure. Once the teeth were seated, alignment was checked and stabilized with adjacent teeth using a semi-rigid splint by acid-etch composite resin technique. The position of the teeth was verified both clinically and radiographically. The splint was left in place for 4 weeks. Systemic antibiotics along with anti-inflammatories were prescribed.

Post-op Instructions: The patient was advised to take a soft diet. For good oral hygiene brushing with a soft-bristle toothbrush and 0.12% chlorhexidine mouthwash for two weeks is recommended.

Follow-up: (as per IADT guidelines)

- The patient was called one week after to start root canal treatment. Calcium hydroxide was kept as an intracanal medicament.
- After 4 weeks, the patient was called for the removal of the splint.
- 2 months after reimplantation, the patient was monitored and it was found that root resorption of the reimplanted teeth had been started.

FOLLOW UP

- Clinical and radiographic examinations were done at an interval of 3,6 and 12 months. During these follow-ups, teeth showed satisfactory clinical and esthetic value along with replacement resorption.
- Maximum resorption was seen around 22.

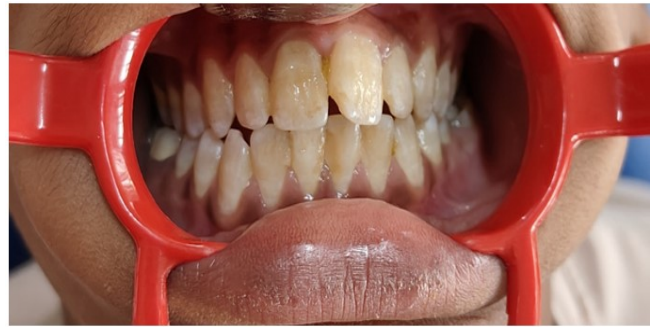

Figure 11. One year after trauma

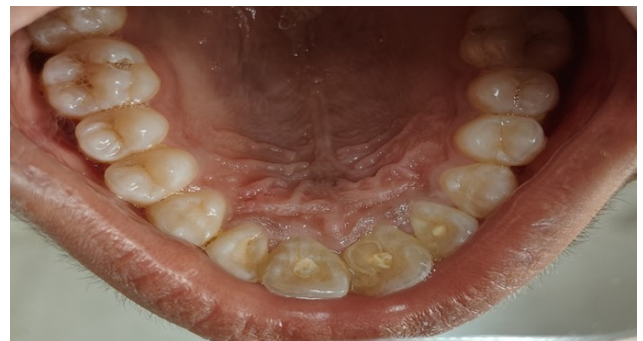

Figure 12. Palatal view

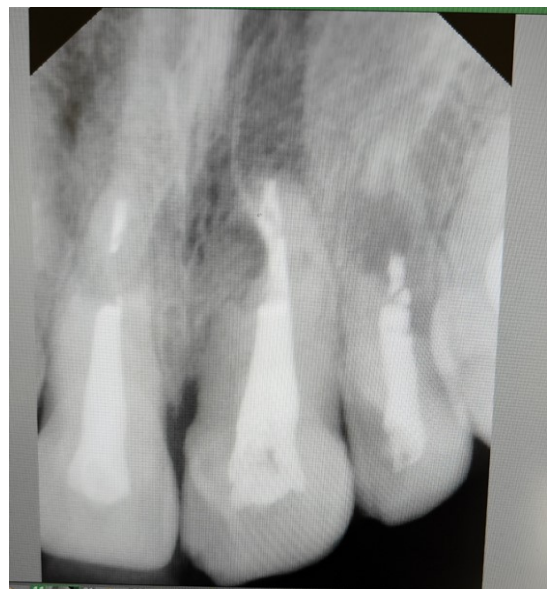

Figure 13. Periapical radiograph, 12 months after replantation

DISCUSSION

The ideal management for an avulsed tooth sticks to its speedy and immediate replantation. However, it is not always possible to perform it immediately. The treatment choice for an avulsed tooth depends on factors like the maturity of the root apex open or closed and the condition of the PDL cells. Whereas, the PDL cells viability depends on the storage medium and the extra-oral dry time. This extra-oral time plays a significant role in the outcome and prognosis.

It has been shown through clinical studies that the speedy replantation of teeth within 30 minutes after avulsion can provide the best prognosis. In this case, the patient found teeth after an hour and came to the department with the avulsed teeth stored in milk. Hence, the condition of PDL cells was considered non-viable. The management of this case was then followed in accordance with the accepted replantation protocol described by the International Association of Dental Traumatology. Because of the mature apex, there is no possibility of pulp space revascularization and the presence of non-viable PDL cells, it was not expected to heal and root canal treatment was opted for the replanted avulsed teeth. Therefore, root canal treatment was started 1 week after the replantation but before removing the splint in order to avoid any unwanted destabilization of the teeth during access cavity preparation. The endodontic treatment was not completed as there were signs of resorption seen on the 2nd-month follow-up visit. There was no sign of pain, mobility or discoloration found until the last appointment.

CONCLUSION

The success of avulsed tooth replantation is directly attributed to the extra-oral time and storage or transport media of the tooth. Despite an extended extra oral dry storage time, teeth with delayed replantation may regain a stable and functional position in the dental arch, if they are managed following proper guidelines & protocols. Clinical and radiographic examination revealed that the reimplanted teeth show signs of replacement resorption, maintaining the esthetic appearance and function. Follow-up appointments are crucial in order to obtain & confirm the successful management of teeth avulsion.

REFERENCES

1. Fouad AF, Abbott PV, Tsilingaridis G, et al. 2020. International Association of Dental Traumatology guidelines for the management of traumatic dental injuries: 2. Avulsion of permanent teeth. *Dent Traumatol.*, 36:331–342.
2. Savas S, Kucukyilmaz E, Akcay M, Koseoglu S. 2015. Delayed replantation of avulsed teeth: Two case reports. *Case Rep Dent.*, 2015:197202
3. Andreasen FM, Andreasen JO, Tsukiboshi M, Cohenca N. 2019. Examination and diagnosis of dental injuries. In: JO Andreasen, FM Andreasen, L Andersson, editors. *Textbook and color atlas of traumatic injuries to the teeth*, 5th edn. Oxford, UK: Wiley Blackwell; p. 295–326.
4. American Association of Endodontists. Recommended guidelines of the American Association of Endodontists for the treatment of traumatic dental injuries. Chicago; 2003.
5. Cohenca N, Silberman A. Contemporary imaging for the diagnosis and treatment of traumatic dental injuries: a review. *Dent Traumatol.* 2017; 33: 321–8.
6. Bourguignon C, Cohenca N, Lauridsen E, et al., 2020. International Association of Dental Traumatology guidelines for the management of traumatic dental injuries: 1. Fractures and luxations. *Dent Traumatol.* 36:314–330.
7. Levin L, Day PF, Hicks L, et al., 2020. International Association of Dental Traumatology guidelines for the management of traumatic dental injuries: General introduction. *Dent Traumatol.*, 36:309–313
8. Andreasen JO. 1975. Periodontal healing after replantation of traumatically avulsed human teeth: assessment by mobility testing and radiography. *Acta Odontol Scand.*, 33:325–35.
9. Trope M. 2002. Avulsion and replantation. *Refuat Hapeh Vehashinayim.* 19:6–15, 76
10. Adnan S, Lone MM, Khan FR, Hussain SM, Nagi SE. 2018. Which is the most recommended medium for the storage and transport of avulsed teeth? A systematic review. *Dent Traumatol.*, 34:59–70.
11. Hashim R. 2011. Dental trauma management awareness among primary school teachers in the Emirate of Ajman, United Arab Emirates. *European journal of paediatric dentistry.* Jun 1;12(2):99-102.
12. Kenny KP, Day PF, Sharif MO, Parashos P, Lauridsen E, Feldens CA. et al., 2018. What are the important outcomes in traumatic dental injuries? An international approach to the development of a core outcome set. *Dent Traumatol.* 34: 4–11.
