



ISSN: 0975-833X

Available online at <http://www.journalcra.com>

INTERNATIONAL JOURNAL  
OF CURRENT RESEARCH

International Journal of Current Research  
Vol. 14, Issue, 01, pp.20556-20559, January, 2022

DOI: <https://doi.org/10.24941/ijcr.43027.01.2022>

## CASE REPORT

### APPLICATION OF LASER IN PEDIATRIC DENTISTRY: A CASE SERIES

**<sup>1</sup>Dr. Nupur Nandkishor Agarwal, <sup>2</sup> Dr. Rucha Shivajirao Bhise Patil, <sup>3</sup> Dr. Ashveeta Jagdish Shetty and <sup>4</sup> Dr. Miloni Paresh Sanghavi**

<sup>1</sup>Post-Graduate Student, Department of Pediatric and Preventive Dentistry, D.Y Patil University- School of Dentistry, Nerul, Navi Mumbai

<sup>2</sup>MDS, Associate Professor, Department of Pediatric and Preventive Dentistry, D Y Patil University - School of Dentistry Nerul, Navi Mumbai

<sup>3</sup>MDS, Assistant Professor, Department of Pediatric and Preventive Dentistry, D.Y Patil University- School of Dentistry, Nerul, Navi Mumbai

<sup>4</sup>Post-Graduate Student, Department of Pediatric and Preventive Dentistry, D.Y Patil University- School of Dentistry, Nerul, Navi Mumbai

#### ARTICLE INFO

##### Article History:

Received 17<sup>th</sup> October, 2021

Received in revised form

09<sup>th</sup> November, 2021

Accepted 14<sup>th</sup> December, 2021

Published online 31<sup>st</sup> January, 2022

##### Keywords:

Laser, Mucocoeles, Ankyloglossia, Oral Surgical Procedures, Dentistry for Children.

##### \*Corresponding author:

**Nupur Nandkishor Agarwal**

#### ABSTRACT

Use of laser in dentistry has evolved in an immense way. With the recent advancement in laser application, it is now effectively used for diagnosis, prevention, and treatment of dental caries and for minimally invasive procedures. The rational use of soft-tissue and hard tissue laser for different oral procedures in infants, children, and adolescents is also recommended by the American Academy of Pediatric Dentistry. Use of laser has numerous benefits in the field of pediatric dentistry like the selective and precise interaction with diseased tissues, less thermal necrosis of adjacent tissues, maintaining a dry and bloodless operative field, produces less pain, sound, and vibration thus increasing the patient compliance. This paper describes a series of four cases wherein excision of bilateral mucocoele and granulomatous lesion on the lower lip, a soft tissue mass on the palate and lingual frenectomy were successfully carried out with the help of diode laser.

Copyright © 2022. Nupur Nandkishor Agarwal et al. This is an open access article distributed under the Creative Commons Attribution License, which permits unrestricted use, distribution, and reproduction in any medium, provided the original work is properly cited.

Citation: Dr. Nupur Nandkishor Agarwal, Dr. Rucha Shivajirao Bhise Patil, Dr. Ashveeta Jagdish Shetty and Dr. Miloni Paresh Sanghavi. "Application of Laser in Pediatric Dentistry: A Case Series", 2022. *International Journal of Current Research*, 14, (01), 20556-20559.

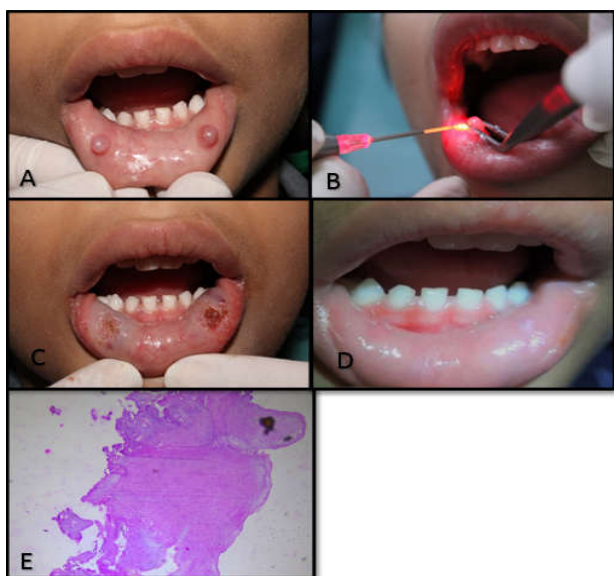
## INTRODUCTION

In the domain of medicine, laser technology has lately been created in an attempt to fulfil patients' diagnostic and therapeutic needs more rapidly and efficiently.<sup>i</sup> The first use of laser in dentistry was for oral soft tissue surgery.<sup>ii</sup> By cutting or ablating tissue with laser light energy, the laser functioned as a scalpel. Its mechanism of action is based on the stimulation of a synthetic material inside a light chamber, which produces intensified light. Without directly contacting the target organ, the energy is emitted uniformly and continuously. In medicine and dentistry, lasers in the wavelengths ranging from 193 to 10600 nm are useful.<sup>iii</sup> One of the benefits of laser use in pediatric dentistry is the selective and precise interaction with diseased tissues.<sup>iii</sup>

Less thermal necrosis of adjacent tissues is produced with lasers than with electrosurgical instruments.<sup>iv</sup> During soft tissue procedures, hemostasis can be obtained without the need for sutures in most cases.<sup>v</sup> Hence, during soft tissue treatments, wound healing can occur more rapidly with less post-operative discomfort and a reduced need for analgesics.<sup>vi,vii</sup> Lasers demonstrate decontaminating and bacteriocidal properties on tissues, requiring less prescribing of antibiotics post-operatively.<sup>vi,vii</sup> Lasers eliminate the vibratory effects of the conventional high-speed handpiece allowing tooth preparations to be comfortable and less anxiety provoking for children and adolescents.<sup>ii, iii</sup> Because of its minimum invasiveness, laser therapy is well-accepted by both children and parents.<sup>viii</sup> Several authors have stated that lasers can reduce psychological trauma and fear during the dental visit.<sup>ix,x</sup> Having a less painful first dental experience through the use of a modern technology like laser would be an efficient

preventive and therapeutic strategy in management of pediatric dental patients. Lasers can be successfully used for diagnosis of oral and dental conditions, treatment of the hard and soft tissue lesions, prevention of rapidly progressing dental conditions in children. Through this paper we aim to highlight a clinical case series representing the application of laser in carrying out various treatment modalities in paediatric patients.

**Case 1- Bilateral mucocele:** A 6-year-old female patient reported to the Department of Pediatric and Preventive Dentistry with a chief complaint of bilateral painless swelling on the right and left side of the lower lip since 2 months. The patient gave a positive history of persistent lip biting habit. The medical as well as family history was non-contributory. On intraoral examination, (Fig. 1) bilaterally symmetrical painless, raised, well circumscribed, semi translucent, pinkish white well-defined lesions were located on the right and the left labial mucosa of the lower lip. Both the lesions were similar in size, shape, consistency and colour. On the basis of history and clinical examination a provisional diagnosis of mucocele was made. Various treatment modalities such as laser excision, surgical incision and cauterization were explained to the parents and they opted for laser excision. Before starting the procedure, both the lesions as well as the surrounding areas were sterilized with betadine solution. After applying a topical anesthetic agent, 4% articaine with 1:80,000 (Septodont) was administered around the periphery of the lesion. The mucocele was pulled upward with the help of artery forceps to create tension and circumferential incision was made initially with the help of diode laser. The entire lesion was then excised using diode laser (Biolase) in the wavelength of 980 nm with 300-micron tip diameter at 1.5 W in continuous mode. Immediate hemostasis was achieved. The excised tissue was then sent for the histopathological examination which confirmed the diagnosis of mucous extravasation cyst. Post-operative instructions were given to the patient that included maintenance of the surgical site and oral hygiene, soft diet and analgesics along with multivitamin syrup and topical application of Vitamin E capsules was prescribed. The healing progressed with no complications on 1 and 6 weeks follow-up.

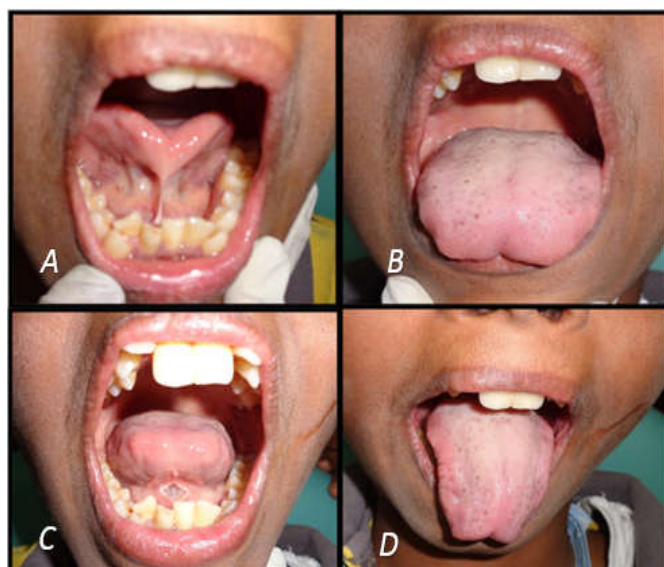

**Fig. 1:** A Pre-operative view, B Laser assisted excision of mucocele, C Immediate post-operative view, D One week follow up, E Histopathological examination

**Case 2- Lingual Frenectomy:** A 10-year-old patient reported with the chief complaint of difficulty in speaking and

deglutition. On examination, (Fig. 2) it was seen that there was a high lingual frenal attachment at the tip of tongue (Class IV frenum). A bifid tongue was observed on protrusion and the tongue movement was restricted. The parents were explained about the treatment options and frenectomy was planned using laser.

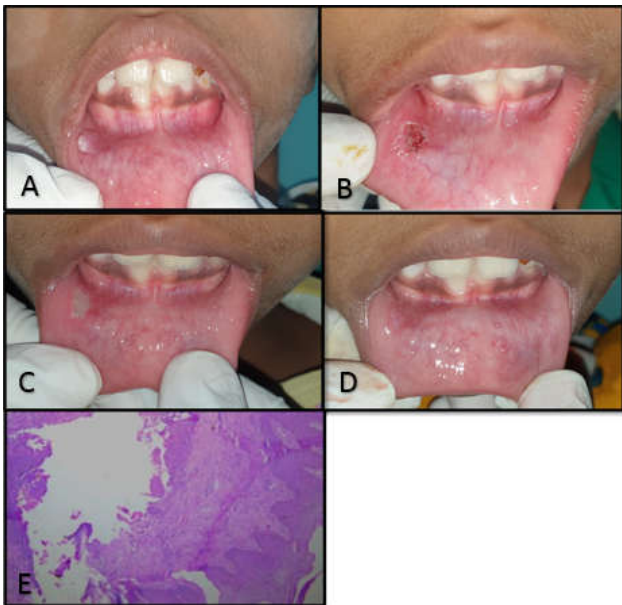
A medical and family history was taken and it was non-contributory. After topical anesthetic application, a few drops of an anaesthetic agent were deposited at the base of the tongue and into the frenum. The tongue was retracted with a mouth mirror. An initiated tip of diode laser (Biolase) in wavelength of 980 nm with 300-micron tip diameter at 1.5 W in continuous mode was used. The tip was moved from the apex of frenum to the base in a brushing stroke, cutting the frenum. High vacuum suction was used continuously to evacuate saliva. After excision, the area was cleaned and Vitamin E (Evion 400, Merck; Ponda Goa, India) was applied. Tongue movement was checked by protrusion to assess complete elimination of the frenum. The patient was prescribed analgesics and recalled after 7 days.



**Fig. 2.** A-B Pre-operative view, C Immediate post-operative view, D Complete protrusion of the tongue observed at 7 days follow-up

**Case 3- Excision of a granulomatous lesion:** A 7-year-old female patient reported with the chief complaint of a painless swelling (soft tissue mass) on the right side of the lower lip. The swelling was painless, raised, well circumscribed, pinkish white in colour (Fig. 3). The patient did not give any positive history of lip biting habit. After discussing various treatment modalities with the parents, excision of the soft tissue mass using laser was decided.

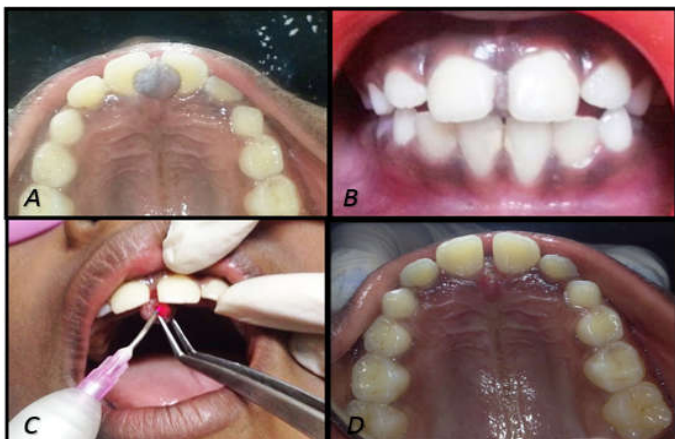
Following the application of topical anaesthesia, 2% lignocaine was administered around the periphery of the lesion. The soft tissue mass was then pulled upward with the help of an artery forceps to create tension and circumferential excision was carried out with the help of diode laser. Immediate haemostasis was achieved. The healing was uneventful at 1 week follow up. The excised soft tissue mass was then sent for histopathological examination which confirmed the diagnosis of granulomatous inflammation. Complete healing was observed at 6 months follow up.



**Fig. 3. A Pre-operative view, B Immediate post-operative view, C Uneventful healing at 7 days follow up, D Complete healing at 6 months follow up. E Histopathological examination.**

#### **Case 4 – Excision of a soft tissue mass (fibro-epithelial hyperplasia)**

A 9-years old male patient complained of soft tissue mass growing behind the front teeth and aesthetically unpleasant appearance due to the same. The soft tissue mass was interfering with the occlusion. On examination, (Fig. 4) the soft tissue mass was round in shape, greyish white in colour with firm consistency and measured about 1 cm in size. After discussing various treatment modalities with the parents, excision of the soft tissue mass using laser was decided. On achieving profound anesthesia, the tissue mass was held with a tweezer and incision was given starting from the buccal aspect going palatally. The incision was given using 940nm wavelength diode laser (Biolase) in continuous mode at 1.8 W power. The laser tip diameter used was 400 $\mu$ m. Slowly incision was progressed palatally and the tissue mass was excised completely. The patient was prescribed analgesics and recalled after 7 days for follow up. Satisfactory haemostasis was obtained postoperatively. The excised soft tissue mass was then sent for histopathological examination and a diagnosis of fibro epithelial hyperplasia was made.



**Fig. 4: A-B Pre-operative view, C Laser assisted excision of soft tissue mass, D Complete healing at 7 days follow up**

## **DISCUSSION**

The introduction of lasers in pediatric dentistry has led to an enormous broadening of the different treatment possibilities for children. It allows the dentist to perform minimally invasive dentistry, removing only the diseased dental tissue and preserving the remaining healthy tooth structure. Recent advances have shown that laser treatment can be added as an alternative or complement to conventional methods. The American Academy of Pediatric Dentistry (AAPD) recognized the judicious use of lasers as a beneficial instrument in providing dental restorative and soft tissue procedures for infants, children, and adolescents including those with special health care needs.<sup>xi</sup> Scalpel (surgical) excision was the most commonly used method to treat any of the oral anomalies and benign pathologies affecting children. Even though surgical treatment does not require an expensive equipment and has a negligible cost involved, it does have certain drawbacks like; requires great control of the instrument and accurate tactile awareness, also requires placement of sutures. There could be a potential for post-operative bleeding and discomfort. It requires a longer healing period and a more ulcerative appearance/scar formation could be observed on healing.<sup>xii, xiii</sup> However, with the advent of a newer technology like laser most of these drawbacks have been eliminated.

The most commonly used lasers in dentistry include holmium yttrium aluminium garnet (HO: YAG), neodymium-doped yttrium aluminium garnet (Nd: YAG), carbon dioxide laser (CO<sub>2</sub>), erbium-doped yttrium aluminum garnet (Er: YAG), diode, chromium doped yttrium scandium gallium garnet Er-(Cr: YSGG) and argon lasers. Clinical applications of lasers in dentistry include soft and hard tissue surgery, detection of dental caries, cleaning the root canal system, etching, periodontal therapy and peri-implantitis treatment. Enhancement of tooth eruption, treatment of drug-induced gingival hyperplasia, resection of fibroma, aphthous lesions, mucocele and pyogenic granuloma and aesthetic procedures are among the other applications of lasers. In the present case series, diode laser was used to perform all the oral surgical procedures. Diode laser is the most frequently used laser in dentistry due to its reliability, versatility and convenience, together with its handiness and simple set-up.<sup>xiv</sup> Diodes are available in wavelengths: 635,670,810,830,980 nm. As its wavelength is poorly absorbed by hard dental tissue, diode laser is safe and well indicated for soft oral tissue surgeries i.e. cutting, vaporization, blood coagulation and haemostasis in the oral region. Its use in contact mode provides tactile feedback during surgical procedure.

Huang *et al.*, conducted a study in which 82 mucoceles were excised with the help of laser.<sup>xv</sup> The authors reported no post-operative bleeding or healing complications. Only two relapses were recorded among the 82 lower lip mucoceles that were treated with the help of laser. Similarly, in another study, of the 50 mucoceles of the lower lip, 25 were excised with the CO<sub>2</sub> laser and the rest with scalpel.<sup>xvi</sup> There was a greater incidence of complications and relapses with the latter technique. The authors stated that the comparatively greater recurrence rate could be attributable to damage to the neighbouring minor salivary glands, caused by the scalpel during removal of the mucocele, or by the needle upon suturing. In the present case, there were no signs of post-operative bleeding or discomfort. Unlike surgical (scalpel) procedures, there was no requirement of suture placement post-operatively.

This procedure does not require suturing due to protein denaturation caused during the contact of laser with the soft tissues.<sup>xvii</sup> The healing was favourable and uneventful without any scar formation. It is believed that a more appropriate healing process results from a higher synthesis of collagen fibres in the laser-irradiated tissues, resulting in a better connective tissue remodeling.<sup>xviii</sup> Also, no recurrence of the excised lesions (mucocele, granulomatous inflammatory lesion and fibroepithelial hyperplasia) were observed at 3 and 6 months follow up. It has also been well-accepted that laser is an excellent and predictable alternative to traditional scalpel or blade methods for paediatric frenectomies. Compared with traditional surgery scalpels, laser procedures applied for lingual frenectomy are thought to be superior in general, according to the child-patient's perceptions.<sup>xix,xx</sup> Furthermore, these techniques usually require more than 15 minutes to completely perform a lingual frenectomy in children, including the necessary haemostasis and suturing, while laser surgery may be carried out in less than 10 minutes.<sup>xxi,xxii</sup> Rangel *et al.*, in a scoping review concluded that lingual frenectomy by laser surgery provides a more efficient and comfortable treatment for both the child patient and the paediatric dentistry practitioner compared to traditional scalpel/blade methods.<sup>xxiii</sup> Similarly, in the present case, lingual frenectomy was successfully carried out with the help of diode laser which was followed by uneventful healing observed at 1 week follow up.

## Conclusion

Thus, this newer technology of laser is very useful in performing oral surgical procedures in paediatric dentistry, as it involves:

- Reduction in the amount of local analgesia and duration of intervention
- A haemostatic effect that enhances visibility of the surgical area, which is a major advantage in children's small mouths
- Scarring is minimal
- Eliminates the need for suture placement
- Also, reduces post-operative oedema, bleeding, infection, discomfort and thus the use of medication.

**Funding:** None

**Conflicts of interest:** None

## REFERENCES

- <sup>i</sup>Martens LC. Laser-assisted Paediatric Dentistry: Review and Outlook. *J Oral Laser Appl.* 2003;34:203-9.
- <sup>ii</sup>Aoki A, Mizutani K, Takasaki AA, Sasaki KM, Nagai S, Schwarz F, Yoshida I, Eguro T, Zeredo JL, Izumi Y. Current status of clinical laser applications in periodontal therapy. *Gen Dent.* 2008 Nov-Dec;567:674-87.
- <sup>iii</sup>Coluzzi DJ. Lasers in dentistry. *Compend Contin Educ Dent.* 2005 Jun;266A Suppl:429-35.
- <sup>iv</sup>Coluzzi DJ. Fundamentals of lasers in dentistry: Basic science, tissue interaction and instrumentation. *J Laser Dent.* 2008;16Spec Issue:4-10.
- <sup>v</sup>Boj JR, Poirier C, Hernandez M, Espassa E, Espanya A. Review: laser soft tissue treatments for paediatric dental patients. *Eur Arch Paediatr Dent.* 2011 Apr;122:100-5.
- <sup>vi</sup>Martens LC. Laser physics and a review of laser applications in dentistry for children. *Eur Arch Paediatr Dent.* 2011 Apr;122:61-7.
- <sup>vii</sup>Olivi G, Genovese MD, Caprioglio C. Evidence-based dentistry on laser paediatric dentistry: review and outlook. *Eur J Paediatr Dent.* 2009 Mar;101:29-40.
- <sup>viii</sup>G. A. Catone, C. C. Ailing, B. M. Smith. *Laser Applications in Oral and Maxillofacial Surgery.* Implant Dentistry. 1997;63:238.
- <sup>ix</sup>Boj, J.R., Galofré, N., España, A.J., & Espasa, E. *Pain Perception in Pediatric Patients Undergoing Laser Treatments.* *J Oral Laser Applications.* 2005;52:85-9.
- <sup>x</sup>Gontijo I, Navarro RS, Haypek P, Ciamponi AL, Haddad AE. The applications of diode and Er:YAG lasers in labial frenectomy in infant patients. *J Dent Child Chic.* 2005 Jan-Apr;721:10-5.
- <sup>xi</sup>Policy on the Use of Lasers for Pediatric Dental Patients. *Pediatr Dent.* 2018 Oct 15;406:95-97.
- <sup>xii</sup>Tran TA, Parlette HL 3rd. Surgical pearl: removal of a large labial mucocele. *J Am Acad Dermatol.* 1999 May;405 Pt 1:760-2.
- <sup>xiii</sup>Harris DM, Gregg RH 2nd, McCarthy DK, Colby LE, Tilt LV. Laser-assisted new attachment procedure in private practice. *Gen Dent.* 2004 Sep-Oct;525:396-403.
- <sup>xiv</sup>Olivi G, Fred S, Margolis, Maria Daniela Genovese. *Pediatric laser dentistry: a user's guide.* *Spec Care Dentist.* 2012:79-80.
- <sup>xv</sup>Huang IY, Chen CM, Kao YH, Worthington P. Treatment of mucocele of the lower lip with carbon dioxide laser. *J Oral Maxillofac Surg.* 2007 May;655:855-8.
- <sup>xvi</sup>Yagüe-García J, España-Tost AJ, Berini-Aytés L, Gay-Escoda C. Treatment of oral mucocele-scalpel versus CO2 laser. *Med Oral Patol Oral Cir Bucal.* 2009 Sep 1;149:469-74.
- <sup>xvii</sup>Romanos G, Nentwig GH. Diode laser 980 nm in oral and maxillofacial surgical procedures: clinical observations based on clinical applications. *J Clin Laser Med Surg.* 1999 Oct;175:193-7.
- <sup>xviii</sup>Kelman MM, Poiman DJ, Jacobson BL. Laser gingivectomy for pediatrics. A case report. *N Y State Dent J.* 2009 Jun-Jul;754:26-9.
- <sup>xix</sup>Kara C. Evaluation of patient perceptions of frenectomy: a comparison of Nd:YAG laser and conventional techniques. *Photomed Laser Surg.* 2008 Apr;262:147-52.
- <sup>xx</sup>Aras MH, Göregen M, Güngörmüş M, Akgül HM. Comparison of diode laser and Er:YAG lasers in the treatment of ankyloglossia. *Photomed Laser Surg.* 2010 Apr;282:173-7.
- <sup>xxi</sup>Sulijaya B, Sunarto H. The comparison of frenectomy using blade versus laser Nd:YAG: A case report. *Global J Dent Oral Hygiene.* 2015 July;21:59-62.
- <sup>xxii</sup>Kumar G, Rehman F, Chaturvedy V. Soft Tissue Applications of Er,Cr:YSGG Laser in Pediatric Dentistry. *Int J Clin Pediatr Dent.* 2017 Apr-Jun;102:188-192.
- <sup>xxiii</sup>Garrocho-Rangel A, Herrera-Badillo D, Pérez-Alfaro I, Fierro-Serna V, Pozos-Guillén A. Treatment of ankyloglossia with dental laser in paediatric patients: Scoping review and a case report. *Eur J Paediatr Dent.* 2019 Jun;202:155-163.