



ISSN: 0975-833X

Available online at <http://www.ijournalcra.com>

International Journal of Current Research  
Vol. 12, Issue, 08, pp.13007-13011, August, 2020

DOI: <https://doi.org/10.24941/ijcr.39379.08.2020>

INTERNATIONAL JOURNAL  
OF CURRENT RESEARCH

## RESEARCH ARTICLE

### RIDGE AUGMENTATION USING MANDIBULAR SYMPHYSIS BONE GRAFT FOR THE PLACEMENT OF DENTAL IMPLANT - A CASE REPORT

\*Dr. Koyel Bhowal<sup>1</sup>, Prof. (Dr.) Samiran Ghosh<sup>2</sup> and Prof. (Dr.) Soumitra Ghosh<sup>3</sup>

<sup>1</sup>3<sup>rd</sup> Year PGT, Department Of Oral & Maxillofacial Surgery, Guru Nanak Institute of Dental Sciences & Research, Panihati, Kolkata

<sup>2</sup>Professor, Department Of Oral & Maxillofacial Surgery, Guru Nanak Institute of Dental Sciences & Research, Panihati, Kolkata

<sup>3</sup>Professor, Department of prosthodontics and crown & Bridge, Guru Nanak Institute of Dental Sciences & Research, Panihati, Kolkata

#### ARTICLE INFO

##### Article History:

Received 30<sup>th</sup> May, 2020  
Received in revised form  
21<sup>st</sup> June, 2020  
Accepted 10<sup>th</sup> July, 2020  
Published online 30<sup>th</sup> August, 2020

##### Key Words:

Dental Implant,  
Autogenous Bone Graft,  
Symphysis Region,  
Ridge Augmentation.

#### ABSTRACT

After tooth loss, alveolar ridge resorption is a common phenomenon, which alters the size and shape of the host bone available for the dental implant placement. In clinical practice, though patients often demand osseointegrated implants to replace their missing teeth; the deficiency of bone volume is the primary reason for avoiding such treatment options. The solution to such situations lies in the re-establishment of the ridge height consistent with prosthetic design and with suitable load-bearing lamellar bone for implant placement and long-term stability. Despite recent advances in bone grafts and bone-substitute technology, the use of autogenous bone grafts continues to represent the “gold standard” in implant site reconstructive surgery. The mandibular symphysis (chin bone in interforaminal region) is a favorable donor site as it has an excellent risk-benefit ratio. In this article, a case report has been elaborated where a healthy patient with 22 years old having edentulous area with single tooth ridge deformity in maxillary anterior region were treated by using ridge augmentation procedure by using autogenous (symphysis) bone graft followed by implant placement after 6 months. Complete follow up of 6 months post loading had been done in this case.

Copyright © 2020, Koyel Bhowal et al. This is an open access article distributed under the Creative Commons Attribution License, which permits unrestricted use, distribution, and reproduction in any medium, provided the original work is properly cited.

Citation: Dr. Koyel Bhowal, Prof. (Dr.) Samiran Ghosh and Prof. (Dr.) Soumitra Ghosh. 2020. “Ridge augmentation using mandibular symphysis bone graft for the placement of dental implant- a case report”, *International Journal of Current Research*, 12, (08), 13007-13011.

## INTRODUCTION

Successful osseointegration of dental implants requires sufficient bone surrounding the implant. Although bone substitutes and augmentation techniques offer viable prognoses for achieving the required amount of hard tissue augmentation, autologous bone is the gold standard with regard to quantity, quality, and an uneventful healing (Sittitavomwong, 2010). Loss of teeth in the anterior maxilla results in resorption of alveolar bone from the labial aspect, leaving a palatally positioned alveolar ridge. Teeth in the anterior maxilla are also at risk of traumatic loss and there may be concomitant alveolar ridge defect resulting from the trauma or from surgical removal of roots. Such alveolar ridge defects can adversely affect the final aesthetic results of the restoration. Therefore, ridge augmentation become necessary to achieve, harmonious balance amongst functional, biological and aesthetics before rehabilitation of the anterior maxillary region (Puri, 2019).

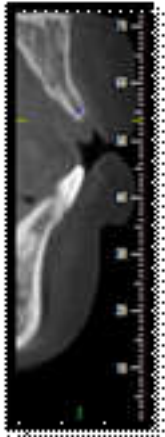
\*Corresponding author: Dr. Koyel Bhowal,  
<sup>3</sup><sup>rd</sup> Year PGT, Department Of Oral & Maxillofacial Surgery, Guru Nanak Institute of Dental Sciences & Research, Panihati, Kolkata.

Symphysis region offers a large amount of cortico-cancellous autograft and easy access among all the intraoral sites. It can be easily harvested in the office settings under local anesthesia on an out-patient basis. Proximity of the donor and recipient sites reduce operative time and cost. Convenient surgical access, low morbidity, elimination of hospital stay, minimal donor site discomfort and avoidance of cutaneous scars are the added advantages (Desai, 2013). The aim of this case report is to describe a method and to assess the success of bone reconstruction of atrophic anterior maxillary alveolar ridge utilizing intraoral bone grafts.

## CASE REPORT

A 22 years old male patient reported to our department with the complain of missing upper anterior tooth. Patient wants fixed tooth prosthesis at upper anterior tooth. On clinical examination showed missing of I1 and labio-palatal ridge defect width was clinically evaluated with the help of the manual Williams graduated periodontal probe. Radiographic examination with the periapical, orthopantomogram and cone-beam computed tomography (CBCT) scan was conducted.

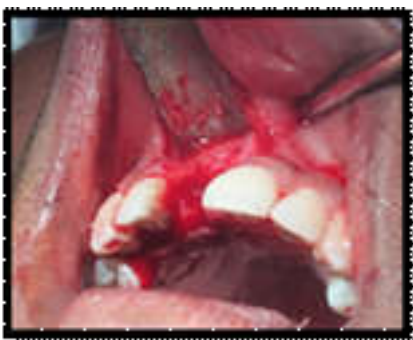Diagnostic cast was prepared to do ridge mapping procedure. Preoperative ridge width was evaluated with cone beam computed tomography and measurement was 2.8mm labio-palatally. Periapical radiograph was done to check periapical pathology if present and also to check the length of the roots of lower anterior tooth. Panoramic view was taken to trace location of the mental foramen and mandibular canal. CBCT scan was done for accurate treatment planning, to determine the quantity and quality of the graft at the donor site and to see the neurovascular components, which can affect the surgical design.



Pre-Operative Cbct

### Surgical Procedure

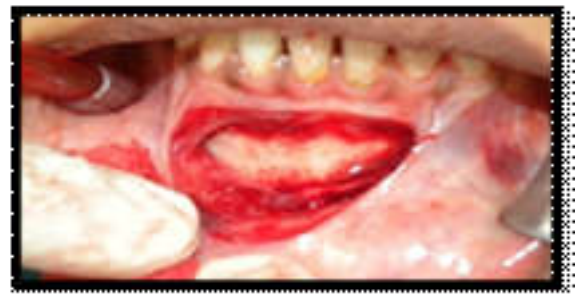**Preparation of Recipient site:-** Briefly after induction of local anaesthesia (block and infiltration with 1:1,00,000 epinephrine) using a Bard Parker Surgical blade # 15, a mid crestal incision was made slightly palatal to the crest of edentulous site. Vertical divergent releasing incisions were made extending to the vestibule. The papillae of the adjacent teeth were included in the flap design to allow maximum exposure of the surgical site enabling controlled placement of bone block and assisting predictable wound closure. Full thickness mucoperiosteal flap was elevated buccally. The bony crest was curetted to remove all soft tissues. A sterilized piece of tin foil was placed over recipient site as a surgical template. It was manipulated, cut and adjusted to the configuration of bony defect and used for harvesting Autogenous bone block of same size from donor site using a small round bur. The labial cortex was perforated to open up the bone marrow cavity to induce revascularization and influx of growth factors and platelets to enhance bone neogenesis.



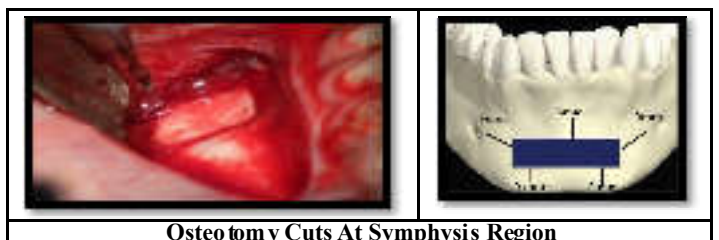
Recipient Site Preparation

**Preparation of Donor site:** Briefly after induction of anaesthesia in the symphysis region by inferior alveolar nerve block/ mental nerve block with local anaesthesia (block and

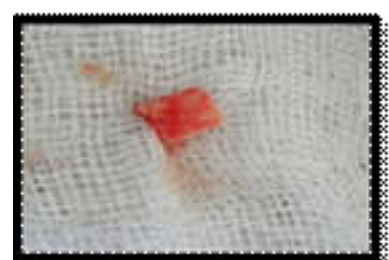
infiltration using 2 % Lidocaine with 1:1,00,000 epinephrine) was made with a Bard Parker blade # 15 apical to the mucogingival line and full thickness flap was reflected to expose the symphysis region. Once the symphysis was exposed, the template was placed over the bony cortex. It was located at least 5 mm away from the inferior border of the mandible, 5 mm from mental foramen, 5 mm from midline spine and 5 mm from the apices of the teeth. The midline spine (protrusion) was preserved to ensure sanctity of the posture of the lower lip and preservation of the labiomental fold. A ½ round, high speed bur under copious irrigation was used to outline the periphery of the template at a right angle to the bone surface, followed by a 701 surgical-length bur to connect the dot. When the outline was completed the osteotomy was deepened into the marrow space. Tactile sense, as well as bleeding from the outline form indicated penetration into the marrow space. Once this communication was completed, Chisel was tapped into the outline with a mallet. During tapping phase, patient was asked to clench the teeth in centric occlusion and chin was supported during the tapping phase, which was started in one of the vertical cuts. The inferior osteotomy was avoided or reserved for last to prevent any danger to the border. If during the tapping, the osteotome refuses to advance, it was probable that the marrow space has not been reached. The osteotome might be too thick. After tactile purchase has been achieved around the entire periphery with the osteotome, it was used as a lever to elevate the graft. When some mobility was noted at the first site same strategy was used on the opposite side. This maneuver was employed at a variety of sites until block became mobile. After elevating the graft from the donor site, it was stored in a mixture of saline and the patient's blood. The sharp bony edges at donor site were smoothed and primary wound closure was accomplished with mattress or single interrupted sutures.



Vestibular Incision

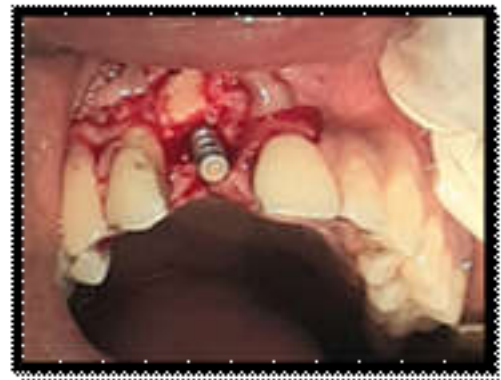


Osteotomy Cuts At Symphysis Region

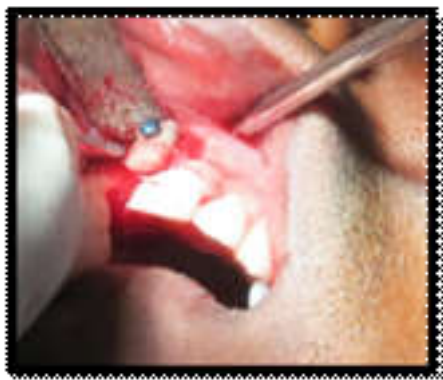

Only Block Bone

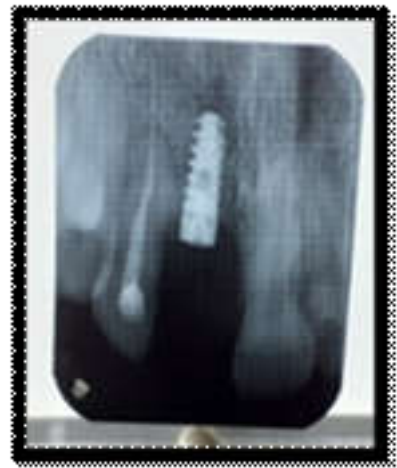**Placement of bone block at the recipient site:** To maximize success, the graft had to be immobilized, and it should be offered adequate blood supply. The bone block was adapted to the defect site morphology. The flap was undermined to adequately cover the newly grafted area of the recipient site. The bone block and the recipient site were modified to fit as closely as possible at the recipient site. Once this is accomplished, with a spiral drill, the holes for the bone block fixation screw were prepared at the recipient site. One screws of diameter 1.5mm were used (1.5mmx8mm, titanium, Orthomax) to stabilize the bone block graft at recipient site. After the graft was secured firmly, voids around the block grafts were filled with cancellous bone graft or bone chips harvested from the donor site. A periosteal releasing incision was made to allow flap mobilization and a tension free primary wound closure. Wound adaptation was accomplished with single interrupted sutures. 7 days later suture removal was done from recipient site.



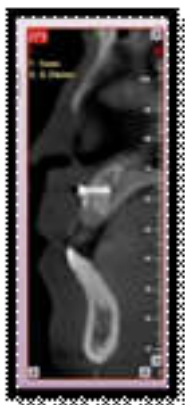
**Implant placed 6 month after bone Augmentation**



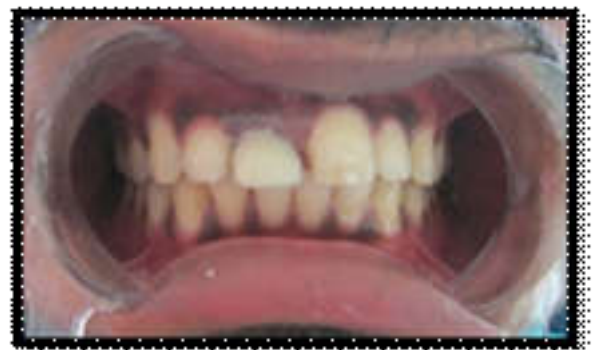**Bone Graft Secured With Titanium Screw At Recipient Site**



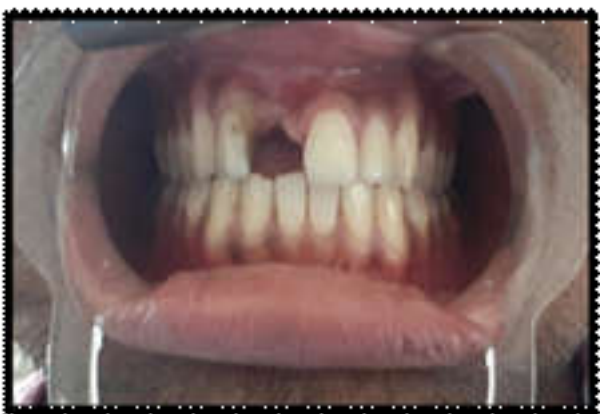**IOPA radiograph**



**6 month post op bone augmentation CBCT**



**Crown placement**



**6 month post op bone augmentation clinical view**

No major complications were observed from donor side. At 6 months all the bone grafts were successfully incorporated at recipient side. No screw exposure was observed. Fixation screws were removed and bleeding from the graft was observed, indicating revascularisation of grafted bone. Dental implant was placed 6 month after bone augmentation procedure . A gain of Labio-palatal ridge was 3.5 mm and apico –coronal gain was 2.1 mm observed after 6 month of bone augmentation procedure.

**DISCUSSION**

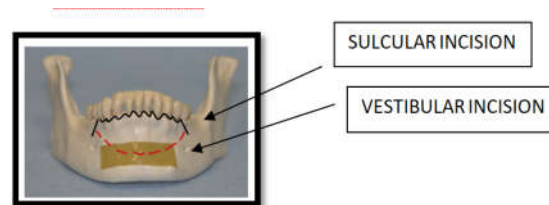
An inadequate alveolar ridge or ridge deformity is frequently encountered that affect esthetics and the restoration outcome. Clinical esthetic problems arise when replacing missing teeth in maxillary anterior region because of exposure of the cervical area of the teeth and the surrounding soft tissue environment.



Therefore, augmentation of alveolar ridge defect becomes more important in terms of aesthetic restoration and to provide sufficient bone volume for the placement of the prosthesis (Puri, 2019). Autogenous bone grafts have the advantage of transferring osteogenic cells to the recipient site. Autogenous donor sites for block grafts include the calvarium, mandible, zygoma, and ilium. Intramembranous bone (calvarium, mandible, and zygoma) has the advantage of decreased rates of resorption compared with endochondral bone (ilium), due to its dense cortical structure and microarchitecture (Louis, 2011). Although cancellous grafts revascularize more rapidly, than cortical grafts, cortical membranous grafts revascularize more rapidly than endochondral bone grafts with a thicker cancellous compartment. This early revascularization of membranous bone grafts is possible explanation for the improved maintenance of graft volume. It may explain why mandibular bone grafts, which are primarily cortical bone and contribute few osteogenic cells, exhibit little volume loss and show good incorporation at shortest healing time (Jensen et al 1994, Smith and Abramson 1974) (Jensen, 2016; Smith, 1974). Others theorize that the improved survival of membranous bone graft is due to their 3 dimensional structures (Manson et al 1994). Alveolar bone grafts for dental implants are indicated when the height of the alveolar crest is usually less than 5 mm or the width is less than 4 mm. The quantity and quality of donor bone site should be considered when selecting the site for bone harvesting.

The limitation of using autologous bone is harvesting adequate bone for reconstruction without exceeding acceptable donor site morbidity. Intraoral bone harvesting has the advantage of being performed in the same operative field and being carried out on an outpatient basis with the patient under local anesthesia. In addition to quick bone harvesting with minimal morbidity, the intraoral bone harvesting techniques do not cause cutaneous scarring (Sittitavornwong, 2010). The mandibular symphysis is the most available source of bone graft. The amount of bone available for harvesting is sufficient for defects measuring up to the width of 3 teeth. Predictability of bone augmentation from the symphysis is up to 6 mm in horizontal and vertical dimensions. There are 2 incision designs for mandibular symphysis harvest. One is sulcular incision and another is vestibular incision. Care must be exercised with regard to proximity of the mental nerves. The sulcular incision is considered in cases with healthy periodontium or no anterior crowns, which could initiate gingival recession. The vestibular incision causes more bleeding from the mentalis muscle but provides less access than the sulcular incision (Sittitavornwong, 2010). Block onlay grafts have been used extensively for reconstruction of mandibular alveolar defects. When a small amount of bone is needed, local grafts harvested from the mandibular symphysis or ramus have been used extensively. A free bone block graft is generally harvested in the form of a corticocancellous bone block (Sittitavornwong, 2010). A study done by Verdugo *et al.* showed approximately 75% of filling of symphysis defect in around 27 months. This fill reached up to 89% in favorable conditions, such as defects (<0.5 cc), larger defects (>0.5 cc) may require longer healing time (Verdugo et al., 2010).

**Healing at the donor site:** A block leaves behind a five-wall defect with good potential to self-repair. Donor-site defects regenerate by a process similar to endosteal fracture healing. During bone wound healing, rapid vascularization of the defect site is paramount for successful neo-osteogenesis.



In the early stages, a vascular proliferation occurs within the medullary cavity. Blood vessels provide pluripotent perivascular cells that have the capability to become osteoblasts. Sides of the blood vessels carry osteoblasts, which help to repopulate the new bone. Monocytes in the blood forms osteoclasts, resorbs devital bone and help to grow the vessels. The normal cascade of physiologic healing events in response to surgical injury, a regionally accelerated process, favors the bone repair at the donor site. This phenomenon was proposed by Frost, which is accelerated process of increased bone turnover in response to noxious stimuli. It causes osteoinduction by osteoclastic secretion of promoter proteins, like bone morphogenetic proteins and osteogenin, that will activate the transformation of pluripotent mesenchymal cells into osteoblasts. Thus, immature bone formation takes place and later a lamellar trabecular osseous structure gradually replaces the internal callus (Desai, 2013; Frost, 1989). The most common postoperative morbidity associated with chin and ramus grafts has been reported as temporary paresthesia. For the chin it ranges from 10% to 50%, and for the ramus, it ranges from 0% to 5%. (Louis, 2011). In the present case, Uneventful healing was observed during the follow-up period and temporary paresthesia was observed for 1 month then gradually resolved.

## Conclusion

The intramembranous transplant like mandibular symphysis is a convenient source and provides a dense quality transplant. The thick cortical layer of the transplant prevents or reduces resorption and the cancellous part help to fasten the regeneration. Proper case selection and accurate surgical planning is the prerequisite for successful graft harvesting. The present case report indicates successful reconstruction of both horizontal & vertical ridge defect using mandibular bone block at the site of single implant placement. Follow up continue in this case to assess the fate of symphysis graft in long term cases.

**Conflict of Interest:** none.

**Consent:** Written informed Consent were obtained from the patients for publication of this case report and accompanying images.

## REFERENCES

- Desai AJ, Thomas R, Kumar AT, Mehta DS. 2013. Current concepts and guidelines in chin graft harvesting: A literature review. *International Journal of Oral Health Sciences*. Jan 1;3(1):16.
- Frost HM. 1989. The biology of fracture healing: an overview for clinicians. Part II. Clinical Orthopaedics and Related Research®. Nov 1;248:294-309.
- Jensen J, Sindet-Pedersen S, Oliver AJ. 1994. Varying treatment strategies for reconstruction of maxillary atrophy with implants: results in 98 patients. *J Oral Maxillofac Surg*. 52(3):210-216; discussion 216-218.

- Louis PJ. 2011. Bone grafting the mandible. *Oral and Maxillofacial Surgery Clinics*. May 1;23(2):209-27.
- Manson PN. 1994. Facial bone healing and bone grafts: A review of clinical physiology. *Clinics in plastic surgery*. Jul 1;21(3):331-48.
- Puri S. 2019. Ridge Augmentation with autogenous bone graft in anterior region: A case series. *Journal of Advanced Medical and Dental Sciences Research*. Aug 1;7(8):37-41.
- Sittitavornwong S, Gutta R. 2010. Bone graft harvesting from regional sites. *Oral and Maxillofacial Surgery Clinics*. Aug 1;22(3):317-30.
- Smith JD, Abramson M. 1974. Membranous vs endochondral bone autografts. *A Otolaryngol*. 99:203-205.
- Verdugo F, Simonian K, D'Addona A, Pontón J, Nowzari H. 2010. Human bone repair after mandibular symphysis block harvesting: a clinical and tomographic study. *Journal of periodontology*. May;81(5):702-9.

\*\*\*\*\*