



ISSN: 0975-833X

Available online at <http://www.journalcra.com>

INTERNATIONAL JOURNAL  
OF CURRENT RESEARCH

International Journal of Current Research  
Vol. 12, Issue, 07, pp.12888-12894, July, 2020

DOI: <https://doi.org/10.24941/ijcr.39255.07.2020>

## RESEARCH ARTICLE

### ENDODONTICALLY TREATED TEETH VS IMPLANTS: A REVIEW ARTICLE

<sup>1</sup>Gursimran Singh Pabla, <sup>2</sup>Akshita Mahajan, <sup>3</sup>Amit Sood, <sup>4</sup>Fatinderjeet Singh, <sup>5</sup>Divya Jakhar, <sup>6</sup>Sadhvi Gupta, <sup>7</sup>Bharti Kataria and <sup>8</sup>Pardeep Mahajan

- <sup>1</sup>Post Graduate Student, Department of Conservative Dentistry and Endodontics, Genesis Institute of Dental Sciences and Research, Ferozepur, Punjab, India
- <sup>2</sup>Post Graduate Student, Department of Conservative Dentistry and Endodontics, Genesis Institute of Dental Sciences and Research, Ferozepur, Punjab, India
- <sup>3</sup>Professor, Department of Conservative Dentistry and Endodontics, Genesis Institute of Dental Sciences and Research, Ferozepur, Punjab, India
- <sup>4</sup>Senior Resident, Department of Conservative Dentistry and Endodontics, Genesis Institute of Dental Sciences and Research, Ferozepur, Punjab, India
- <sup>5</sup>Post Graduate Student, Department of Conservative Dentistry and Endodontics, Genesis Institute of Dental Sciences and Research, Ferozepur, Punjab, India
- <sup>6</sup>Post Graduate Student, Department of Conservative Dentistry and Endodontics, Genesis Institute of Dental Sciences and Research, Ferozepur, Punjab, India
- <sup>7</sup>Post Graduate Student, Department of Conservative Dentistry and Endodontics, Genesis Institute of Dental Sciences and Research, Ferozepur, Punjab, India
- <sup>8</sup>Professor and Head, Department of Conservative Dentistry and Endodontics, Genesis Institute of Dental Sciences and Research, Ferozepur, Punjab, India

#### ARTICLE INFO

##### Article History:

Received 07<sup>th</sup> April, 2020  
Received in revised form  
25<sup>th</sup> May, 2020  
Accepted 21<sup>st</sup> June, 2020  
Published online 30<sup>th</sup> July, 2020

##### Key Words:

Endodontically involved teeth,  
Dental Implants,  
Treatment planning.

#### ABSTRACT

The decision between retention of endodontically involved teeth as opposed to extraction and implant treatment is a clinical decision that requires a careful evaluation of the pre, intra and postoperative factors that may influence the outcome of the proposed treatment. A careful and extensive consideration of indications, contraindications, risks, and benefits of both single-tooth implants and the natural restored tooth is of critical importance if an accurate evaluation of treatment options is to be presented to the patient for their informed consent. From a prosthetic point of view an implant retained prosthetic solution is possible for any kind of edentulous situation. While the selection of cases for endodontic therapy should take into consideration the prognosis of the endodontic, restorative and periodontal procedures. The dentist should consider the strategic value of the tooth to be endodontically treated in relation to the overall function of the dentition. This review aims to highlight different aspects and points that every dentist should keep in mind during arranging treatment plan for their patients: Post-operative pain and discomfort, Duration of the treatment, masticatory forces, cosmetics, success and survival rate of the treatment, costs, quality of life, the need for complementary treatment, specific cases, predicting factors, patients tendency, experience of the practitioner.

Copyright © 2020, Gursimran Singh Pabla et al. This is an open access article distributed under the Creative Commons Attribution License, which permits unrestricted use, distribution, and reproduction in any medium, provided the original work is properly cited.

Citation: Gursimran Singh Pabla, Akshita Mahajan, Amit Sood, Fatinderjeet Singh, Divya Jakhar, Sadhvi Gupta, Bharti Kataria and Pardeep Mahajan. 2020. "Enhancing higher education programs through a graduate survey", *International Journal of Current Research*, 12, (07), 12888-12894.

## INTRODUCTION

One of the fundamental goals of dentistry is the retention of a patient's natural dentition in a disease-free state (Morris, 2009). The decision between retention of endodontically involved teeth as opposed to extraction and implant treatment is a clinical decision that requires a careful evaluation of the

pre, intra and postoperative factors that may influence the outcome of the proposed treatment (Doyle, 2006). Intelligent clinical judgments should be made on the basis of outcomes of alternative treatment modalities, considering the cost to the patient. Recently, many systematic reviews with meta-analysis were published to provide the highest level of current evidence for various dental procedures. These 'best' current evidences can be the basis in the decision-making process. Nevertheless, it is realized that not only is the choice of treatment controversial, but even the criteria for defining a tooth as compromised are controversial and subject to differences in

\*Corresponding author: Gursimran Singh Pabla,  
Post Graduate Student, Department of Conservative Dentistry and Endodontics, Genesis Institute of Dental Sciences and Research, Ferozepur, Punjab, India.

interpretation. However, a careful and extensive consideration of indications, contraindications, risks, and benefits of both single-tooth implants and the natural restored tooth is of critical importance if an accurate evaluation of treatment options is to be presented to the patient for their informed consent (Kim, 2011).

#### Indications of root canal treatment:

- Pain
- Microbial Causes
- presence of pathogenic bacteria
- presence of virulent clonal types
- microbial synergism or additism
- number of microbial cells
- environmental
- Host resistance
- Apical extrusion of debris
- non-microbial cause
- Extrusion of irrigants
- Intracanal Medicaments
- gum tenderness
- restorative procedures
- overdenture construction
- management of discoloured teeth induced by tetracycline staining
- calcific metamorphosis
- Management of invasive cervical resorption
- Root amputation to gain periodontal healing
- Surgical removal of some odontogenic and non-odontogenic bone lesion approximating the root apex.

#### Contraindications of root canal treatment:

- Patient unable to afford fee
- Inability of the dentist
- Insufficient periodontal support
- Canal instrumentation
- Non restorable tooth
- Massive resorption
- Nonstrategic tooth
- Vertical fractures

#### Indications of implants

- Edentulous jaw
- Uni- or bilateral missing teeth at the end of the arch
- Too many teeth missing within the arch
- A single tooth missing
- In the case of so-called 'defect prosthetics' following trauma or tumor resection
- In cases of difficult swallowing and parafunction.
- Verified allergy against prosthetic acrylics
- Hypersensitive mucosa
- In certain diseases: asthma, gastritis, ulcers, epilepsy
- High esthetic demand: actors, speakers, singers.

From a prosthetic point of view an implant retained prosthetic solution is possible for any kind of edentulous situation!!! (Theisen, 1990; Schmitt, 1993)

#### Contraindications of implants:

- General contraindications
- Local contraindications

#### General Surgical Contraindications

- Pregnancy
- Psychological instability
- Physical and mental retardation
- Alcoholism, heavy smoking
- Atypical facial pain
- Age under 14

#### Local Contraindication

- Radiation therapy within 5 years in the region of the planned implant
- Pathological conditions of the local bone and soft tissues
- Malocclusion (deep bite) and parafunction (bruxism) that will overload the implant
- Dental anomalies that have to be treated before implant placement
- Pathological conditions of local bone and soft tissues - osteomyelitis, osteoradionecrosis, large cysts, granuloma, fibrous dysplasia, benign and malignant bone tumors.
- radiclelecta (relict root)
- leukoplakia and the erosive form of lichen
- fibrotic alveolar ridge, papilloma, papillomatosis, fibroma and fibromatosis

#### Temporary Contraindication

- Fever
- Within 3 months after bone and 3 weeks after mucosal inflammations
- In the case of bone grafting of the edentulous ridge (Guided Bone Regeneration)

#### Definite Contraindication

- Drug abuse
- Bad oral hygiene which continues despite of motivating treatment.

#### Benefits of root canal treatment:

- reduces pain
- prevents abscess formation
- prevent bone loss
- saves tooth
- improves oral health
- maintains bite
- maintains confidence and self-esteem
- proprioception of teeth
- cost effective

#### Benefits of dental implants:

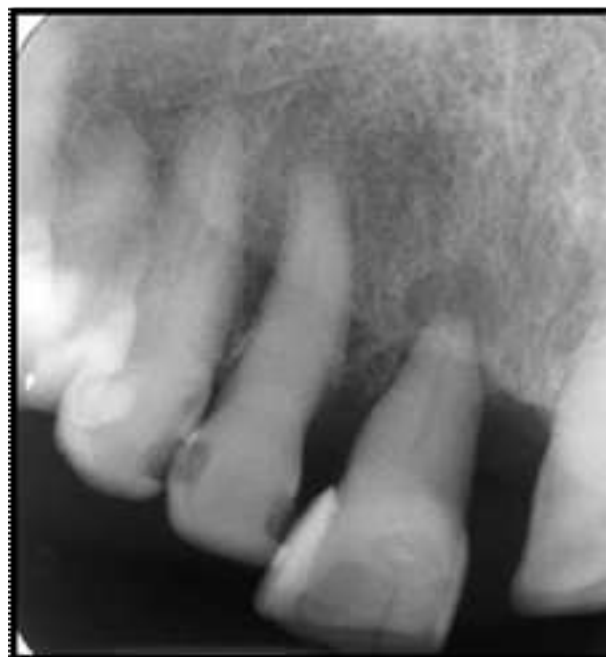- improve appearance
- get immediate results
- restore self-esteem and renew your self confidence
- be comfortable in everyday situations

- Restore your mouth to its most natural state
- keep natural healthy teeth healthy
- Enhance patient overall quality of life
- eliminate health issues common with failing teeth
- care for teeth easily

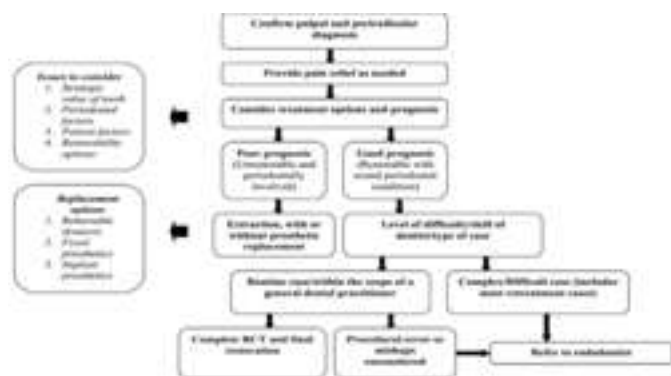
### Treatment planning of root canal treatment:

#### General overview of endodontic treatment planning

The selection of cases for endodontic therapy should take into consideration the prognosis of the endodontic, restorative and periodontal procedures (Friedman, 2004). The flow chart (Fig 1) provides a diagrammatic outline of the decision-making process for treatment planning in endodontics. Once appropriate diagnostic tests have confirmed the pulpal and periradicular diagnosis, immediate treatment of the tooth may be required if relief of painful symptoms is needed. For a patient in pain, the dominating concern by the dentist is whether endodontic treatment will rapidly and predictably eliminate the patient's pain and discomfort (Montgomery, 1986). Following stabilization of the tooth, the dentist should exercise caution in deciding whether the tooth concerned has a good or poor prognosis.



**Fig 2. Tooth 11 presented with extensive periodontal probing and mobility. The tooth was planned for extraction because of poor periodontal prognosis, despite the probability of a favourable endodontic prognosis (Marshall, 1979).**



**Fig 1. Treatment planning flow chart (Montgomery).<sup>7</sup>**

#### Issues to consider when making this judgement include:

- Strategic value of the tooth;
- Periodontal factors;
- Patient factors; and
- Whether the tooth can be restored or are there alternative replacement options.

The dentist should consider the strategic value of the tooth to be endodontically treated in relation to the overall function of the dentition. Insufficient periodontal support (Fig 2) may thus be viewed as a contraindication to root canal treatment. Periodontal management of patients is important to the long-term success of any treatment plan (Marshall, 1979). Conditions which limit a patient's ability to lie supine (e.g., spinal arthritis), to open the mouth wide (e.g., rheumatoid arthritis), or to tolerate rubber dam (e.g., anxiety disorders), may make endodontic treatment more difficult but not impossible (Messer, 1999). Following appropriate explanation of what is planned, the dentist should take into consideration the following questions that may influence the overall treatment plan and management (Pothukuchi, 2006):

- Is endodontic treatment in the patient's best interest?
- What are the patient's expectations?
- Will the patient be able to tolerate the treatment planned?
- Will the patient be able to afford the treatment planned?

The tooth concerned must be assessed for any restorative challenges that would deem the tooth as unrestorable following root canal treatment. Removable partial dentures are often a simple and relatively inexpensive tooth replacement option, but these prostheses tend not to be well tolerated. Conventional bridges can provide an excellent option for tooth replacement, especially when the potential abutment teeth will benefit with full coronal coverage restorations, but the patient's oral hygiene must be excellent. Certain patients may benefit from an implant-supported prosthesis, but it is not the treatment of choice in all situations. The patients must be carefully selected both on clinical grounds and the patients' wishes after they have been fully informed of the procedure and are able to make an informed decision.

#### Prognosis of endodontic treatment

Although dentists would like to give the patient as accurate a prognosis as possible before endodontic treatment is performed, a less than ideal technical standard provided, or procedural errors and/or an inadequate coronal restoration will lead to a reduced prognosis for the tooth. Dentists should be reminded that studies reporting an overall healing frequency (success rate) do not necessarily imply that this particular tooth has the same chance of healing. Quoting a figure or even a range (e.g., 60 per cent or 50–70 per cent chance of healing for a re-treatment case) can be very misleading (Rosenberg, 2002).

**Treatment planning of implant patients:** An accurate diagnosis and proper treatment planning makes implant treatment a long term success.

Clinical examination and mounted cast models give us information about the maxilla-mandibular relationship, available space, occlusion, inter arch distance and relative parallelism. With the help of radiographic examination the critical landmarks such as the mandibular canal, maxillary sinus and roots of adjacent teeth are identified. Based on all these findings a workable treatment plan is formulated for the patient which solves the chief complaint of the patient, provides a good functional and esthetic result and is expected to function for a long duration of time.<sup>13</sup>

#### The general rules that are followed during implant placement are:

- The minimum distance of implant to adjacent tooth should be 1.5 mm to 2 mm.
- The minimum distance between two implants should be 3 mm to 4 mm.
- Buccolingually, implant should be placed at 2 mm to 3 mm distance from the cervical height of contour.
- Coronopically, implant should be placed at 2.5 mm to 3 mm from the buccogingival margin.
- At least 7 mm of interocclusal/interarch space should be available from shoulder of the implant to the occlusal surface of the opposing tooth.
- A buffer zone of 23 mm from the inferior alveolar nerve or the floor of sinus from implant apex should be maintained (Belsler, 1982).

Before we go into the details of the treatment planning let us first discuss the types of fixed and removable prosthesis.

#### Success and survival of endodontically teeth:

- This healing pattern, particularly in teeth with AP at the time of initial treatment, indicates that success rates of RCT (in terms of periapical health) start at 0% and increase overtime. Fristad et al. (2004) found a 95.5% radiographic success rate with retreated teeth recalled 20–27 years postoperatively, whilst the same sample had a 85.7% success 10 years previously. The teeth deemed to be failures radiographically at 10–17 years were still functioning after another 10 years and healing was observed after the extended observation time (Zitzmann, 2009).
- This study not only shows the potential for late healing, but also the inadequacy of a ‘radiographic only’ assessment (Fristad et al. 2004, Wolcott & Meyers 2006). Applying only clinical measures (no signs and symptoms), however, led to an overestimation of favorable outcomes, whilst the radiographic measure (with /without periapical radiolucency) was found to be a better predictor for the outcome of RCT (Kois, 1998).
- The use of cone beam computed tomography with three-dimensional images, has the potential to add further information about the periapical status of endodontically treated teeth.
- The awareness that pulpal and periradicular disease may be managed, but not always entirely eliminated led to an important change in evaluating outcomes. Hence, RCT outcome is better evaluated in terms of ‘healed or healing/ success’, ‘diseased/ survival’ and ‘failure’ rather than just ‘success’ and ‘failure’ (Friedman, 2004).

According to a recent meta-analysis, the pooled outcome of primary RCT was 75% when strict success criteria (absence of periapical radiolucency) were applied, and reached 85% based on loose criteria (reduction in size of radiolucency) (Kois, 1998). Preoperative absence of a periapical radiolucency, root filling with no voids, root filling extending to 2 mm within the radiographic apex and satisfactory coronal restoration were found to improve the outcome of primary RCT significantly (Kois, 1998). In teeth without a periapical radiolucency, initial RCT secured a success rate of 96% after 8–10 years, whilst healing was reduced to 86% in cases with pulp necrosis and periapical radiolucency (Sjogren et al. 1990). Highest success rates exceeding 90% (with periapical health as outcome measure) have been achieved following RCT in teeth with vital pulps (Wennström, 2005). Reasons for persistent or emerging disease associated with root filled teeth are either endodontic in nature, or, more frequently, related to nonendodontic factors:

Endodontic causes include residual intracanal infection in nonaccessible regions of the canal system or periapical infections due to persisting microbiota, vertical root fractures, presence of true cysts, or foreign body reactions, e.g., to overfilled root canals (Kois, 1998). Non endodontic reasons for RCT failure are related to pre-existing factors such as severe periodontal disease, or to post-endodontic factors such as recurrent caries, improper reconstructions with coronal leakage and subsequent reinfection or fracture. RCT teeth not restored with crowns were extracted at a rate 6.0 times greater than teeth crowned after root filling (Foster et al., 2008). In a study evaluating the reasons for failure of RCT teeth, prosthetic reasons (crown fracture, root fracture at the level of a post, traumatic fracture) dominated and explained almost 60% of the failures; 32% failed due to periodontal reasons, whilst pure endodontic failures (vertical root fracture, instrumentation failure, root resorption) were rare and accounted for less than 10%. Chen et al. (2008) reported from an epidemiologic study that extensively decayed or unrestorable teeth were the main reason for tooth extractions (40%). Other causes were tooth fracture (28%), and periodontal disease (23%), whilst endodontic reasons were rare at 9% (Aquilino, 2001). Clinical studies investigating the long-term survival of fixed dental prostheses (FDP) showed that as soon as 1 or more RCT abutments were involved, the survival rate of all restoration at 20 years was reduced to 57% compared with 69% when the FDP comprised abutments with healthy pulps only. According to a multivariate analysis of abutment failures (365 teeth with vital pulps, 122 root filled teeth), additional influencing factors other than RCT were distal terminal position in the FDP, and advanced marginal bone loss as initially assessed from radiographs (Zitzmann, 2010). Several variables were stronger multi variately than bi variately and this indicated that a combination of risk factors is the most detrimental for the longevity of the restorations (Palmqvist & Söderfeldt 1994).

In epidemiological studies investigating the retention of RCT teeth based on data from insurance companies, so called ‘untoward events’ yielding further insurance claims such as extraction, retreatment, or apical surgery were evaluated (Aquilino, 2001). Eight years after initial nonsurgical root canal treatment, 96% of all teeth (almost 1.5 million) were retained without any untoward event; 0.4% required nonsurgical retreatment, in 0.6% apical surgery was performed, and 2.9% were extracted. Extractions occurred mainly within 3 years from completion of the RCT, and

affected primarily those teeth without full coronal coverage. Chen et al. (2007, 2008) also reported a high 5-year tooth retention rate of 93% following nonsurgical RCT in more than 1.5 million teeth. In all, almost 10% were affected by untoward events (6.9% of the teeth were extracted, 2.3% required nonsurgical retreatment, and in 0.5% apical surgery was performed) (Chen et al., 2008).

### Success and survival of implants

- Complications and failures, however, occur either prior to implant osseointegration (early implant loss) or after initially successful osseointegration (late implant loss) and disease manifestation may necessitate several years or even decades of function.
- Whilst initial implant fixation following placement is simply derived from mechanical stabilization, osseointegration with an intimate contact between living bone and the titanium surface requires several weeks.<sup>20</sup>
- Early implant failures occur mainly during the first weeks or months after implant placement and are frequently related to surgical trauma, complicated wound healing, insufficient primary stability and/or initial overload.
- Late implant losses are caused by microbial infection, overload or toxic reactions from implant surface contamination (e.g., acid remnants). Whilst overload leads to a sudden loss of osseointegration with implant mobility, microbial infection initiates peri-implant mucositis that corresponds to gingivitis and may progress into peri-implantitis that corresponds to periodontitis.
- According to the consensus report from the 1st European Workshop on Periodontology, peri-implant mucositis was defined as a reversible inflammatory reaction in the soft tissues surrounding an implant, and peri-implantitis was described as inflammatory reactions associated with loss of supporting bone around an implant in function.
- Hence, peri-implantitis is clinically diagnosed by bleeding on probing (and/or suppuration) in combination with radiographic bone loss. During the first year following implant placement, bone remodeling may cause bone resorption in the marginal area (average 1.3–1.5 mm around implants placed at the bone level).
- Any further bone loss, particularly reaching  $\geq 2.5$  mm, is considered as disease manifestation (Berglundh et al. 2002), and affects at least 28% of subjects (Brugnolo, 1996).
- Despite disease progression, the implant remains nonmobile until the apical portion of implant osseointegration is affected (Listgarten 1997). In the implant literature, the majority of studies report implant survival rates defined as simple retention (Brugnolo, 1996).
- If success criteria are applied, the absence of clinical symptoms, no signs of inflammation and a limited marginal bone loss (e.g., not exceeding 0.2 mm after the first year in function) are frequently mentioned.
- In several studies, however, disease symptoms are not consistently investigated, i.e., probing is not applied, and bone level assessments are made from panoramic radiographs with limited accuracy (Zitzmann, 2001).

According to a review analyzing long-term results of fixed implant restorations, 39% of all patients were affected by complications or failures during a 5-year observation period. The 10-year survival rates reached 93% (implant-FDP) and 94% (single tooth implants, STI) on an implant level, whilst

survival of the implant restorations varied between 87% (implant-FDP) and 90% for the ISC (Pjetursson et al. 2004). It should be noted that implant reconstructions exposed to biological or technical complications were at greater risk of recurrent problems or failures (Aquilino et al., 2001). Similarly, patients who had experienced an implant failure, had a 30% increased risk of further failures (Wenstro, 2000).

Risk factors for developing peri-implant diseases are patient-related (e.g., susceptibility to periodontitis, diabetes), environmental (e.g., cigarette smoking, alcohol consumption), technological (e.g., exposed rough implant surface), or local. These local factors comprise poor personal plaque control, or iatrogenic factors such as insufficient access for oral hygiene due to implant position and/or restoration contour, or excess cement. Limited evidence is available for an association between peri-implant disease and rough implant surfaces or genetic traits (Missika, 1997). Late implant failures due to occlusal overload occur when the load bearing threshold set by the biological phenomenon of osseointegration has been exceeded. Very little is known about this individual threshold and possible influencing factors such as bone quality, implant surface modifications and the type and direction of forces. Whilst clenching exerts mainly vertical forces, bruxism creates excessive lateral forces, which are suggested to be less well tolerated.<sup>26</sup>

**Etiopathogenesis of rct and implant failure:** Myriad of factors have been implicated in the failure of endodontic treatment. The usual factors which can be attributed to endodontic failure are:

- Persistence of bacteria (intra-canal and extra-canal)
- Inadequate filling of the canal (canals that are poorly cleaned and obturated)
- Overextensions of root filling materials
- Improper coronal seal (leakage)
- Untreated canals (both major and accessory)
- Iatrogenic procedural errors such as poor access cavity design
- Complications of instrumentation (ledges, perforations, or separated instruments).

**Peri-implantitis:** The role of bacterial plaque on late failures has attracted much attention, but is indeed still controversial. According to Tonetti & Schmid an imbalance of the host-parasite equilibrium can manifest itself in a series of inflammatory changes leading to two distinct syndromes: a) peri-implant mucositis, which is a lesion confined to the superficial soft tissues; and b) peri-implantitis. The latter involves the deeper soft tissue as well as the peri-implant bone (Zanetti, 1984).

**Overload in relation to bone quality and volume:** Osseointegrated implants can fail due to excessive occlusal load under experimental conditions. However, it remains still difficult to prove a direct relationship between overload and implant failure in humans. As pointed out by Cochran, this is presently due to the almost impossible task of clinically quantifying the magnitude and the direction of bite forces applied by the patient (in particular, for patients who brux or clench) in relation to the biomechanical capacity of the bone (bone quality) and to the lack of adequate control groups. Nevertheless, consensus has been achieved that marginal bone loss around implants can be associated with implant overload (Lindquist, 1988).

The work of (Lindquist et al.) is traditionally referred to as the first published evidence which correlated marginal bone loss to “reported tooth clenching and recorded occlusal wear on the prostheses”. However, no information was presented on how these parameters were actually measured observed a clear correlation between excessive marginal bone loss (>1 mm) after the first year of loading and/or fixture loss with occlusal overload, but not with marginal peri implant mucositis. Further, these authors reported that a higher failure rate was observed with shorter fixtures. In another investigation by the same group, 5 out of 7 implants placed in partially dentate patients, in whom an increase of the vertical dimension was done, failed. Similarly, in patients treated with full-fixed bridges, 7 of 12 late failures were attributed to parafunctions. It was also observed that 8 lost implants were end-abutments and that 4 of the 5 patients who experienced marginal bone loss >1 mm during the 3rd yr of function, had parafunctional activity (Isidor, 1996).

**Combined Hypothesis:** Some failing/failed implants present clinical signs and a histological picture which are difficult to interpret. In fact, it might be hard to clearly allocate such implants into one of the two etiological groups described above (peri-implantitis and overload). However, it is likely that, in some circumstances, both overload and infectious etiologies can overlap, giving rise to a mixed etiology. In those situations, it might be difficult to understand which of the etiologies has played the primary role. For instance, an implant which has lost osseointegration due to overload might be more prone to bacterial infection and epithelial down growth due to its mobility (Quirynen, 1994). In this context, it is likely that the better long-term clinical performance of osseointegrated versus fibrointegrated oral implants may be related to the stability of the former. In fact, the tight bone apposition at the implant surface stabilizes the implanted device, thus preventing the down growth of the junctional epithelium. On the other hand, epithelial down growth in the presence of bacteria might be favoured by the mobility of fibrointegrated implants. It may also be the case that the progressive marginal bone loss, initiated by bacteria, could reach a level at which the supporting bone is not able to sustain habitual loads any longer (Lindquist, 1988).

## Conclusion

This conclusion tries to compare the RCT and implant from different aspects and represents some points that every dentist should keep in mind during arranging treatment plan for their patients:

- Post-operative pain and discomfort
- Duration of the treatment
- Masticatory forces
- Cosmetics
- Success and survival rate of the treatment
- Costs
- Quality of life
- The need for complementary treatment
- Specific cases
- Predicting factors
- Patients tendency
- Experience of the practitioner

## REFERENCES

- Aquilino, SA., Shugars, DA., Bader, JD. & White, BA. (2001). Ten-year survival rates of teeth adjacent to treated and untreated posterior bounded edentulous spaces. *J Prosthet Dent*, Vol.85, No.5, pp.455-60.
- Belser U C. 1982. Esthetic checklist for the fixed prosthesis. Part II: Biscuit bake try in. In Scharer P, Rinn L A, Kopp F R (Eds). Esthetic guidelines for restorative dentistry. pp 188-192. Chicago: Quintessence.
- Brugnolo, E., Mazzocco, C., Cordioli, G. & Majzoub, Z. (1996). Clinical and radiographic findings following placement of single-tooth implants in young patients—case reports. *Int J Periodontics Restorative Dent*, Vol.16, No.5, pp.421-33.
- Chen, SC., Chueh, LH., Hsiao, CK., Wu, HP. & Chiang, CP. (2008). First untoward events and reasons for tooth extraction after nonsurgical endodontic treatment in Taiwan. *J Endod*, Vol.34, No.6, pp.671-4.
- Doyle SL, Hodges JS, Pesun JJ, Law AS, Bowles WR. 2006. Retrospective cross sectional comparison of initial nonsurgical endodontic treatment and single-tooth implants. *J Endod.*, 32(9):822-7.
- Foster, KH. & Harrison, E. (2008). Effect of presentation bias on selection of treatment option for failed endodontic therapy. *Oral Surg Oral Med Oral Pathol Oral Radiol Endod*, Vol.106, No.5, pp.e36-9.
- Friedman S, Mor C. 2004. The success of endodontic therapy – healing and functionality. *J Calif Dent Assoc.*, 32:493-503.
- Isidor F. 1996. Loss of osseointegration caused by occlusal load of oral implants. A clinical and radiographic study monkeys. *Clin Oral Implants Res* 1996; 7: 143–152/453.
- Kim SG, Solomon C. 2011. Cost-effectiveness of endodontic molar retreatment compared with fixed partial dentures and single-tooth implant alternatives. *J Endod.*, 37(3):321-5.
- Kois J C. 1998. Aesthetic extraction site development: The biological variables. *Contemp Aest Rest Pract.*, 2: 10-18.
- Lindquist LW, Rockler B, Carlsson GE. Bone resorption around fixtures in edentulous patients treated with mandibular fixed tissue-integrated prostheses. *J Prosthet Dent* 1988; 59: 59–63.
- Marshall FJ. 1979. Planning endodontic treatment. *Dent Clin North Am.*, 23:495-518.
- Messer HH. 1999. Clinical judgement and decision making in endodontics. *Aust Endod J.*, 25:124-132.
- Missika P, Abbou M, Rahal B. Osseous regeneration in immediate postextraction implant placement: a literature review and clinical evaluation. *Pract Periodontics Aesthet Dent* 1997;(Regeneration Report):165-75.
- Montgomery S, Ferguson CD. 1986. Endodontics. Diagnostic, treatment planning, and prognostic considerations. *Dent Clin North Am.*, 30:533-548.
- Morris MF, Kirkpatrick TC, Rutledge RE, Schindler WG. 2009. Comparison of nonsurgical root canal treatment and single-tooth implants. *J Endod.* 35(10):1325-30.
- Naert I, Quirynen M, van Steenberghe D, Darius P. 1992. A study of 589 consecutive implants supporting complete fixed prostheses. Part II: Prosthetic aspects. *J Prosthet Dent.*, 8: 949-956.
- Patel S, Dawood A, Ford TP, Whaites E. 2007. The potential applications of cone beam computed tomography in the management of endodontic problems. *International endodontic journal*. Oct;40(10):818-30.
- Pothukuchi K. 2006. Case assessment and treatment planning: what governs your decision to treat, refer or replace a tooth

- that potentially requires endodontic treatment? *Aust Endod J.*, 32:79-84.
- Quirynen M, Bollen CML, Eyssen H, Van Steenberghe D. Microbial penetration along the implant components- of the Branemark system. An *in vitro* study. *Clin Oral; Implants Res* 1994; 5: 239–244.
- Rosenberg P. 2002. Case selection and treatment planning. In: Cohen S, Burns R, eds. *Pathways of the Pulp*. 8th edn. St Louis: Mosby Inc, 91-102.
- Schmitt A, Zarb GA. 1993. The longitudinal clinical effectiveness of osseointegrated dental implants for single-tooth replacement. *Int J Prosthodont.*, 6:197-202.
- Theisen FC, Shultz RE, Elledge DA. 1990. Displacement of a root form implant into the mandibular canal. *Oral Surg Oral Med Oral Pathol.*, 70: 24-8.
- Wagnild GW, Mueller K. 2002. Restoration of the endodontically treated tooth. In: Cohen S, Burns R, eds. *Pathways of the Pulp*. 8th edn. St Louis: Mosby Inc, 765-795.
- Wennström, J. L., Ekestubbe, A., Gröndahl, K., Karlsson, S. & Lindhe, J. (2004) Oral rehabilitation with implant-supported fixed partial dentures in periodontitis-susceptible subjects. A 5-year prospective study. *J Clin Periodontol* 31, 713–724.
- Wennström, J.L., Ekestubbe, A., Gröndahl, K., Karlsson, S. & Lindhe, J. 2005. Implant supported single - tooth restorations: a 5-year prospective study. *J Clin Periodontol*, Vol.32, No.6, pp.567-74.
- Zanetti NC, Solursh M. Induction of in limb mesenchymal cultures by disruption of the actin cytoskeleton. *J Cell Biol* 1984; 99: 115–123.
- Zitzmann NU, Krastl G, Hecker H, Walter C, Waltimo T, Weiger R. Strategic considerations in treatment planning: deciding when to treat, extract, or replace a questionable tooth. *The Journal of prosthetic dentistry*. 2010 Aug 1;104(2):80-91.
- Zitzmann NU, Krastl G, Hecker H, Walter C, Weiger R. 2009. Endodontics or implants? A review of decisive criteria and guidelines for single tooth restorations and full arch reconstructions. *International endodontic journal*. Sep;42(9):757-74.
- Zitzmann, N. U., Berglundh, T., Marinello, C. P. & Lindhe, J. (2001) Experimental periimplant mucositis in man. *J Clin Periodontol* 28, 517–523.

\*\*\*\*\*