



ISSN: 0975-833X

Available online at <http://www.journalcra.com>

International Journal of Current Research  
Vol. 11, Issue, 01, pp.795-799, January, 2019

DOI: <https://doi.org/10.24941/ijcr.34124.01.2019>

INTERNATIONAL JOURNAL  
OF CURRENT RESEARCH

## RESEARCH ARTICLE

### PROFILE CHANGES FOLLOWING RETRACTION IN ADULT FEMALES OF DAKSHINA KANNADA

**<sup>1</sup>Dr. Sharath Kumar Shetty, <sup>2</sup>Dr. Mahesh Kumar, Y. \*<sup>3</sup>Dr. Chandrima. A. Sreekumar and <sup>4</sup>Dr. Brijit Alphonsa Gervasis**

<sup>1</sup>Director and Head of the Department, Department of Orthodontics and Dentofacial Orthopedics, K V G Dental College and Hospital, Sullia, D K 574327, India

<sup>2</sup>Professor, Department of Orthodontics and Dentofacial Orthopedics, K V G Dental College and Hospital, Sullia, D K 574327, India

<sup>3</sup>Final year Post Graduate Student, Department of Orthodontics and Dentofacial Orthopedics, K V G Dental College and Hospital, Sullia, D K 574327, India

<sup>4</sup>Senior lecturer, Department of Orthodontics and Dentofacial Orthopedics, K V G Dental College and Hospital, Sullia, D K 574327, India

#### ARTICLE INFO

##### Article History:

Received 16<sup>th</sup> October, 2018  
Received in revised form  
20<sup>th</sup> November, 2018  
Accepted 03<sup>rd</sup> December, 2018  
Published online 31<sup>st</sup> January, 2019

##### Key Words:

Bimaxillary protrusion;  
Cephalometry; lips;  
Face; bicuspid.

#### ABSTRACT

**Objective:** To evaluate the profile changes following treatment in adult female patients with bimaxillary protrusion of Dakshina Kannada region.

**Materials and Methods:** Twenty five Class I bimaxillary protrusive adult female patients treated with MBT appliance after first premolar extraction were included in the sample. Pre and Post treatment lateral cephalometric radiographs were evaluated and the obtained data was compared using Paired t test or Wilcoxon signed rank test.

**Results:** Nasolabial angle showed significant increase of 7.56<sup>0</sup> post treatment (p value 0.001\*) Upper lip thickness and lower lip thickness increased by 0.84mm and 0.12mm (P values 0.030\*, 0.478\* and respectively). Upper lip angle decreased by 7.08<sup>0</sup>(p value 0.001\*)

**Conclusion:** Significant changes in nasolabial angle, upper lip angle and upper lip thickness were noticed post retraction in bimaxillary protrusive adult female patients of Dakshina Kannada region.

**Copyright** © 2019, Dr. Sharath Kumar Shetty et al. This is an open access article distributed under the Creative Commons Attribution License, which permits unrestricted use, distribution, and reproduction in any medium, provided the original work is properly cited.

**Citation:** Dr. Sharath Kumar Shetty, Dr. Mahesh Kumar, Y. Dr. Chandrima. A. Sreekumar and Dr. Brijit Alphonsa Gervasis, 2019. "Profile changes following retraction in adult females of Dakshina Kannada", *International Journal of Current Research*, 11, (01), 795-799.

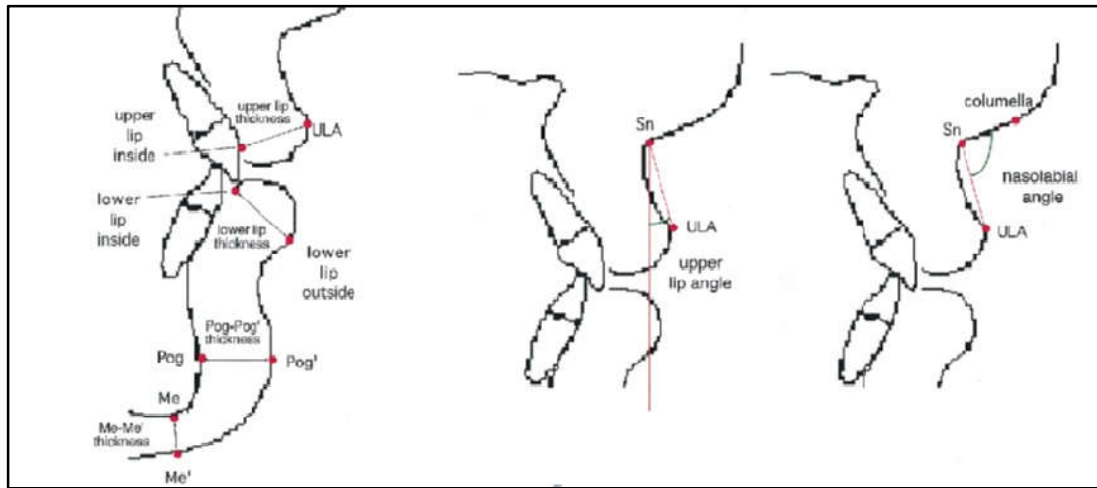
## INTRODUCTION

Facial aesthetics holds at most importance in today's dental practice. Patients, especially females are well aware and concerned about their facial appearance and smile attractiveness. Most of the times lips changes will be noticed more compared to nose and chin (Burcal, 1987). Lower third of face especially the position contour and structure of lips may be altered by orthodontic treatment which involves incisor retraction (Konstantonis, 2012). Bimaxillary protrusion is a common anomaly seen in various ethnic groups especially Asians characterised by flaring of both the upper and the lower anterior teeth resulting in protrusion of the lips and a convex facial profile (Tan, 1995; Kurz, 1997; Bills 2005 and Diels, 1995). A most common treatment modality for this condition involves extraction of all four first premolars and retraction of

anterior teeth to reduce the dental and lip procumbency. Attaining a harmonious profile is one of the prime goals in treatment and hence it is important to evaluate the post treatment profile changes to evaluate the success of orthodontic treatment. The most common and feasible diagnostic aid in orthodontic practice is cephalometric Roentgenology which also be utilized to evaluate treatment changes. Morphological features of bimaxillary protrusion (Lew, 1989) as described by Keating showed significant post treatment reduction of protuberance of soft tissue profile by 4<sup>0</sup> (Keating, 1989). Reidel proposed that the skeletal and dental structures and soft tissue profile were related to each other (Reidel, 1957). Soft tissue cephalometric analysis considered nasolabial angle and upper lip angle as important parameters which were altered by incisor teeth retraction and evaluation of these angles was advised when the treatment involved overjet reduction (Arnett, 1999). This study evaluates profile changes like nasolabial angle, upper lip angle, Pog to Pog', Me to Me', upper lip thickness and lower lip thickness in adult female patients of in Dakshina Kannada region who underwent orthodontic treatment for bimaxillary protrusion.

**\*Corresponding author: Dr. Chandrima. A. Sreekumar**

Final year post graduate student, Department of Orthodontics and Dentofacial Orthopedics, K V G Dental College and Hospital, Sullia, D K 574327, India



**Fig. 1. Nasolabial angle, upper lip thickness, lower lip thickness, upper lip angle, lower lip angle, pog-pog', Me-Me' will be analysed using soft tissue cephalometric analysis**

## MATERIALS AND METHODS

A retrospective study was conducted using Pre and Post treatment Lateral Cephalograms of 25 adult female patients of Dakshina Kannada region. Cephalometric tracing and analysis was done to estimate the changes in profile in bimaxillary protrusive subjects following orthodontic treatment with extraction of all first premolars.

### Inclusion Criteria

**Sample selection criteria included:** Lateral cephalograms of subjects who have undergone orthodontic treatment with the following criteria will be taken from previous case records.

- Class I molar relationship.
- Protrusive upper and lower lips.
- Subjects in the age group of 18- 27 year old females.
- Standardized pre and post treatment lateral cephalometric radiographs with teeth in full occlusions and lips in a natural position with good hard and soft tissue outlines.
- Good quality radiographs were all the soft and hard tissue landmarks were clearly visible.
- Orthodontically treated patients with extraction of four first premolars.

### Exclusion Criteria

- Poor quality lateral cephalograms.
- Skeletal or dental class II, class III cases.
- Patients who have undergone Orthodontic/ Orthopedic/ Orthognathic surgical treatment, splint therapy, dental prosthesis, plastic surgery.
- Patients with history of trauma particularly to orofacial region.
- Patient with temporomandibular joint disorders, systemic syndromes and craniofacial anomalies.
- Patients with obvious/ gross facial or lip deformity.

Routine lateral cephalometric records taken with PLANMECA-9200-Proline XC with Dimax of patients who matched the inclusion criteria were selected.

All lateral cephalograms were carefully traced by the same observer under the same illumination on a matte lacquered poly ester acetate tracing paper of thickness 75  $\mu\text{m}$  using 0.5mm 2B microtip pencil. Following parameters are measured: Nasolabial angle, Upper lip thickness, Lower lip thickness, Pogonion to Pogonion', Menton to Menton' and Upper lip angle will be analysed using soft tissue cephalometric analysis (Reidel, 1957). (Figure 1).

**Error Study:** In order to rule out measurement errors, after the first measurement, randomly selected 50 cephalograms were retraced by the same investigator. Causal errors were calculated according to the Dahlberg's formula ( $Se^2 = \sqrt{\Sigma d^2 / 2n}$ ) where  $Se^2$  is the error variance and 'd' is the difference between two determinations of the same variables (Dahlberg, 1940).

**Statistical Analysis:** After manual tracing and measurement of linear and angular measurements, Data was entered in excel sheets and difference was calculated. Data was analysed using SPSS software for Windows (Statistical Presentation System Software, SPSS Inc.) version 17.0.

Continuous data was represented as mean and standard deviation. Paired t test or Wilcoxon signed rank test was used. Graphical representation of data: MS Excel and MS word. p value (Probability that the result is true) of  $<0.05$  was considered as statistically significant after assuming all the rules of statistical tests.

## RESULTS

Nasolabial angle showed significant increase of  $7.56^\circ$  post treatment with p value 0.001\*. Upper lip thickness and lower lip thickness increased by 0.84mm and 0.12mm and with P values 0.030\*, 0.478\* and respectively. Pogonion-Pogonion' and Menton-Menton' remained almost same post treatment. (Table I, II and III).

## DISCUSSION

Profile changes may or may not be accomplished even after correction of underlying malocclusion (Brodie, 1938). Tweed and later Stoner found that normal occlusion is associated with an acceptable lip position (Tweed, 1954 and Stoner, 1956).

**Table 1. Descriptive details of the Study group in Pre intervention**

Group	N	Mean	Std. Deviation	Minimum	Maximum
POG- POG'	25	9.84	1.344	8	13
ME-ME'	25	6.40	1.581	4	10
ULA	25	20.16	6.149	7	30
ULT	25	10.56	1.557	7	14
LLT	25	12.24	1.535	10	16
NLA	25	97.88	8.918	83	114

**Table 2. Descriptive details of the Study group in Post intervention**

Group	N	Mean	Std. Deviation	Minimum	Maximum
POG- POG'	25	9.80	1.780	6	13
ME-ME'	25	6.28	1.370	5	9
ULA	25	13.08	4.941	6	23
ULT	25	11.40	1.756	9	15
LLT	25	12.36	1.551	10	16
NLA	25	105.44	9.166	88	127

**Table 3. Comparison of change in pre and post intervention of various variables**

Groups	N	Mean	Std. Deviation	Std. Error Mean	P-value	
ULT	Pre	25	10.56	1.557	.311	0.030*
	post	25	11.40	1.756	.351	
LLT	Pre	25	12.24	1.535	.307	0.478
	post	25	12.36	1.551	.310	
NLA	Pre	25	97.88	8.918	1.784	0.001*
	post	25	105.44	9.166	1.833	
ULA	Pre	25	20.16	6.149	1.230	0.001*
	post	25	13.08	4.941	.988	
POG- POG'	Pre	25	9.84	1.344	.269	0.880
	post	25	9.80	1.780	.356	
ME-ME'	Pre	25	6.40	1.581	.316	0.559
	post	25	6.28	1.370	.274	

\*significant at the 0.05 level.

Burstone laid foundation for the studies which highlighted the relationship between soft tissues and dentoalveolar structures and pointed out that varying thickness of soft tissues which overlies the facial skeleton could be the limiting factor in reflecting a corresponding soft tissue change (Subtelny, 1959). Contradictory findings were proposed by Reidel and Subtelny where both agreed on the close relationship of skeletal and dental changes in the soft tissue profile, but later disagreed on direct changes on all parts of the soft tissue profile (Reidel, 1957 and LaMastra, 1981). Difference in opinion regarding this seen in numerous previous studies can be because of various factors like growth status of patient, continued development of nose, variability in lip responses, morphology, tonicity and position which needs to be considered while analysing the post treatment results (Wisth, 1974; Hershey, 1972; Oliver, 1982; Huggins, 1975; Finnöy, 1987; Garner, 1974 and Rudee, 1964). Nasolabial angle increased by 7.65° with the mean post treatment value of 105.44°. According to Drobocky and Smith the proposed ideal range of nasolabial angle is 90-120° and Scheideman et al reported a normal mean nasolabial angle 111.48 (Drobocky, 1989 and Scheideman, 1980). The currently obtained value indicates an esthetically pleasing nose to lip relationship after treatment. Various other studies have shown similar results with increase in nasolabial angle with even higher and lower values. Changes may be attributed to factors like lip thickness and lip strain (Hayashida, 2010). Relaxed lip posture is also an important factor to be taken into account while evaluating lip positions. Changes in nasolabial angle can also be affected by the nasal growth which continues over the treatment time (Fitzgerald, 1992). In this study upper lip angle showed a decrease of 7.08°.

A recent study reported the decrease in upper lip angle of still higher value of 10.34° (Sundareswaran, 2017). Difference may be due to the differences in the method of measurement of upper lip angle in both the studies. According to Oliver, maxillary lip thickness and postural tone might have an effect on changes in soft tissues post retraction of maxillary anterior teeth (Oliver, 1982). In present study post treatment lip thickness increased by 0.84mm and 0.12mm for upper and lower lip respectively. Increase in lower lip thickness was not significant though. Various other authors reported increase in upper lip thickness as a result of maxillary incisor retraction (Talaas, 1987; Chiavini, 1999 and Ricketts, 1960). Konstantonis demonstrated an increase of 2.17 mm of upper lip thickness among patients who underwent extraction (Konstantonis, 2012). Increase in lip thickness up to age of 14 is proven by various authors since current study sample contains patients beyond that age so growth related lip changes can be excluded (Subtelny, 1959; Mamandras, 1988; Nanda, 1990). On the contrary, there are studies by Hershey found 0.71 mm decrease in lip thickness with every one mm of incisor retraction, also Ramos et al noted a 0.7–0.8 mm decrease in lip thickness in class II div1 patients during the course of treatment (Hershey, 1972 and Ramos, 2005). Lamastra reported a 1:1 ratio for decrease in lip thickness with retraction of labial groove (LaMastra, 1981). Brock found both increase and decrease in lip thickness in different parts of the upper lip. Inferior half of the upper lip showed increased thickness and superior half showed vice versa (Brock, 2005). Diels et al reported an increase in lip thickness at labrale superioris in Black females while Oliver found that white females had little or no change in lip thickness measured at superior labial sulcus upon maxillary incisor retraction (Diels,

1995 and Arnett, 1999). Since this study sample selected contains majority of females, the attained result hints that previous studies are reliable in co relating lip thickness with incisor retraction and lip changes following incisor retraction can have ethnic differences. Soft tissue parameters such as pogonion to pogonion' and menton to menton' showed no significant changes intending lack of changes in soft tissue landmarks such as pogonion and menton as a part of orthodontic teeth retraction. Even though retraction of upper and lower dentition causes significant changes in the immediate hard and soft tissues, this cannot reflect a change upon chin region in bimaxillary protrusive patients.

## Conclusion

This study shows conclusive inference on definitive soft tissue changes following treatment in class I bimaxillary protrusive adult females.

- Nasolabial angle was increased by  $7.65^{\circ}$  with the mean post treatment value of  $105.44^{\circ}$  and upper lip angle decreased by  $7.08^{\circ}$ .
- Upper lip thickness increased by 0.84mm post treatment.

## REFERENCES

- Arnett GW, Jelic JS, Kim J, Cummings DR, Beress A, Worley CM, Chung B, Bergman R. Soft tissue cephalometric analysis: diagnosis and treatment planning of dentofacial deformity. *American Journal of Orthodontics and Dentofacial Orthopedics*. 1999 Sep 30;116(3):239-53.
- Bills DA, Handelman CS, BeGole EA. Bimaxillary dentoalveolar protrusion: traits and orthodontic correction. *The Angle orthodontist*. 2005 May;75(3):333-9.
- Brock II RA, Taylor RW, Buschang PH, Behrents RG. Ethnic differences in upper lip response to incisor retraction. *American journal of orthodontics and dentofacial orthopedics*. 2005 Jun 1;127(6):683-91.
- Brodie, A. G., Downs, W. B., Goldstein, A. and Myer, E. (1938). Cephalometric appraisal of orthodontic results. *Angle Orthodontist*, 8: 261-351.
- Burcal RG, Laskin DM, Sperry TP. Recognition of profile change after simulated orthognathic surgery. *J Oral Maxillofac Surg*. 1987;45:666-670.
- Chiavini PCR. Avaliac,ãõ cefalome´ trica das alterac,ões labiais em indivi´duos portadores de Classe II, divisãõ 1a de Angle, tratados com extrac,ãõ dos primeiros pre´molares superiores [dissertac,ãõ]. Araraquara, Brazil: Universidade Estadual Paulista; 1999.
- Dahlberg G. Statistical methods for medical and biological students. New York: Interscience Publication; 1940.
- Diels RM, Kalra V, DeLoach Jr N, Powers M, Nelson SS. Changes in soft tissue profile of African-Americans following extraction treatment. *The Angle orthodontist*. 1995 Aug;65(4):285-92.
- Droboccky OB, Smith RJ. Changes in facial profile during orthodontic treatment with extraction of four first premolars. *American Journal of Orthodontics and Dentofacial Orthopedics*. 1989 Mar 1;95(3):220-30.
- Figure caption -Soft tissue structures: tissue thickness at upper lip, lower lip, Pogonion', and Menton' along with Upper lip angle and nasolabial angle are depicted.
- Finnöy JP, Wisth PJ, Böe OE. Changes in soft tissue profile during and after orthodontic treatment. *The European Journal of Orthodontics*. 1987 Jan 1;9(1):68-78.
- Fitzgerald JP, Nanda RS, Currier RGF. An evaluation of the nasolabial angle and the relative inclinations of the nose and upper lip. *Am J Orthod Dentofacial Orthop*. 1992;102: 328-334
- Garner LD. Soft-tissue changes concurrent with orthodontic tooth movement. *American journal of orthodontics*. 1974 Oct 1;66(4):367-77.
- Hayashida H, Ioi H, Nakata S, Takahashi I, Counts AL. Effects of retraction of anterior teeth and initial soft tissue variables on lip changes in Japanese adults. *The European Journal of Orthodontics*. 2010 Oct 21;33(4):419-26.
- Hershey HG. Incisor tooth retraction and subsequent profile change in postadolescent female patients. *American Journal of Orthodontics*. 1972 Jan 1;61(1):45-54.
- Huggins DG, McBride LJ. The influence of the upper incisor position on soft tissue facial profile. *British Journal of Orthodontics*. 1975 Jul 1;2(3):141-6.
- Keating PJ. Bimaxillary protrusion in the Caucasian: a cephalometric study of the morphological features. *British journal of orthodontics*. 1985 Oct;12(4):193-201.
- Keating PJ. The treatment of bimaxillary protrusion: a cephalometric consideration of changes in the inter-incisal angle and soft tissue profile. *British journal of orthodontics*. 1986 Oct 1;13(4):209-20.
- Konstantonis D. The impact of extraction vs nonextraction treatment on soft tissue changes in Class I borderline malocclusions. *The Angle Orthodontist*. 2012 Mar;82(2):209-17.
- Kurz C. The use of lingual appliances for correction of bimaxillary protrusion (four premolars extraction). *American journal of orthodontics and dentofacial orthopedics*. 1997 Oct 31;112(4):357-63.
- LaMastra SJ. Relationships between changes in skeletal and integumental points A and B following orthodontic treatment. *Am J Orthod*. 1981;79:416-423.
- Leonardi R, Annunziata A, Licciardello V, Barbato E. Soft tissue changes following the extraction of premolars in nongrowing patients with bimaxillary protrusion: a systematic review. *The Angle orthodontist*. 2010 Jan;80(1):211-6.
- Lew K. Profile changes following orthodontic treatment of bimaxillary protrusion in adults with the Begg appliance. *The European Journal of Orthodontics*. 1989 Nov 1;11(4):375-81.
- Mamandras AH. Linear changes of the maxillary and mandibular lips. *Am J Orthod*. 1988;94:405-410.
- Nanda RS, Meng H, Kapila S, Goorhuis J. Growth changes in the soft tissue facial profile. *Angle Orthod*. 1990;60:177-189.
- Oliver BM. The influence of lip thickness and strain on upper lip response to incisor retraction. *American Journal of Orthodontics and Dentofacial Orthopedics*. 1982 Aug 1;82(2):141-9.
- Ramos AL, Tatsuei Sakima M, dos Santos Pinto A, Bowman SJ. Upper lip changes correlated to maxillary incisor retraction—a metallic implant study. *The Angle Orthodontist*. 2005 Jul;75(4):499-505.
- Reidel RA. An analysis of dentofacial relationships. *Am J Orthod*. 1957;43:103-119.
- Ricketts RM. Cephalometric synthesis. *Am J Orthod*. 1960; 46:647-673.

- Rudee DA. Proportional profile changes concurrent with orthodontic therapy. *American Journal of Orthodontics and Dentofacial Orthopedics*. 1964 Jun 1;50(6):421-34
- Scheideman GB, Bell WH, Legan HL, Finn RA, Reisch JS. Cephalometric analysis of dentofacial normals. *Am J Orthod*. 1980;78:404-420.
- Stoner M M, Lindquist J T 1956 A cephalometric evaluation of 57 cases treated by Dr C H Tweed. *Angle Orthodontist* 26: 68-98
- Subtelny JD. A longitudinal study of soft tissue facial structures and their profile characteristics, defined in relation to underlying skeletal structure. *Am J Orthod*. 1959;45: 481-507.
- Sundareswaran S, Vijayan R. Profile changes following orthodontic treatment of class I bimaxillary protrusion in adult patients of Dravidian ethnicity: A prospective study. *Indian Journal of Dental Research*. 2017 Sep 1;28(5):530.
- Talaas MF, Talaas F, Baker RC. Soft-tissue changes resulting from retraction of maxillary incisors. *Am J Orthod Dentofacial Orthop* 1987;91:385-94.
- Tan TJ. Profile changes following orthodontic correction of bimaxillary protrusion with a preadjusted edgewise appliance. *The International journal of adult orthodontics and orthognathic surgery*. 1995 Dec;11(3):239-51.
- Tweed, C. H. 1954. Frankfurt-mandibular incisor angle (FMIA) in orthodontic diagnosis treatment planning and prognosis. *Angle Orthodontist*, 24: 121-169.
- Wisth PJ. Soft tissue response to upper incisor retraction in boys. *British journal of orthodontics*. 1974 Oct 1;1(5):199-204.

\*\*\*\*\*