



RESEARCH ARTICLE

CLINICAL EFFICACY OF *BALA TAILA UTTARBASTI* IN THE MANAGEMENT OF URETHRAL STRICTURE: CASE REPORT

\*Dr. Joyal Patel

Associate Professor, Department of Shalya Tantra, Shree Gulabkunverba Ayurveda Mahavidyalaya, Gujarat Ayurved University, Jamnagar, Gujarat, Pin -361008, India

ARTICLE INFO

**Article History:**

Received 14<sup>th</sup> May, 2018  
Received in revised form  
08<sup>th</sup> June, 2018  
Accepted 20<sup>th</sup> July, 2018  
Published online 31<sup>st</sup> August, 2018

**Key Words:**

Mutramarga Sankocha,  
Urethral Stricture, Urethral Dilatation,  
Uttarabasti.

**Copyright** © 2018, Joyal Patel. This is an open access article distributed under the Creative Commons Attribution License, which permits unrestricted use, distribution, and reproduction in any medium, provided the original work is properly cited.

**Citation:** Dr. Joyal Patel. 2018. "Clinical Efficacy of *Bala Taila Uttarbasti* in the management of Urethral Stricture: Case Report", *International Journal of Current Research*, 10, (08), 73068-73071.

ABSTRACT

Stricture urethra, though a rare condition, still is a rational and troublesome problem in the international society. Major complications caused by this disease are obstructed urine flow, urine stasis leading to urinary tract infection, calculi formation, etc. This condition can be correlated with Mutramarga Sankocha in Ayurveda. Modern medical science suggests urethral dilatation, which may cause bleeding, false passage and fistula formation in few cases. Surgical procedures have their own complications and limitations. Uttarabasti, a para-surgical procedure is the most effective available treatment in Ayurveda for the diseases of Mutravaha Srotas. A male patient of 55 years old consulted to OPD, Shree Gulabkunverba Ayurveda Hospital, Jamnagar, with complaints like hesitancy, intermittency, straining, dribbling, incomplete voiding, and burning micturition was assessed before and after treatment. Retrograde urethrography was done before and after treatment. This case study was treated with *Bala Taila Uttarbasti*. The result of the study was significant on all the parameters.

INTRODUCTION

From the study of ancient surgical text, Sushruta Samhita, it becomes evident that urological problems are an important part of medical sciences even during those days. It may be the reason that a clear and striking picture regarding their classification, symptomatology, complications and management are explained in all the classical texts. The earliest description about the afflictions of urinary tract can be traced back to Atharva Veda. Comprehensive description regarding Mutraghata and its treatment with the use of Loha Shalaka give as an account of knowledge that our ancestors had anatomical, physiological, pathological and therapeutic aspects of the human body (Athavale, 2004). As per Ayurvedic Sharira Rachana, Mutravaha Srotas includes Vrukka (kidney), Gavini (ureter), Mutrashaya (urinary bladder) and Mutramarga (urethra). Ashtanga Hridaya defines that urination is the function of Vata, and its vitiation settles in disturbed urinary functions (Vagbhata, 2007). Sushruta has described 12 varieties of Mutraghata which is classified on the basis of dominance of Doshas, but Vata is the basic Dosha for all varieties of Mutraghata (Sushruta, 2002).

It is a condition in consequence with some kind of obstructive uropathy, mechanical or functional; related either to upper or lower urinary tract resulting into either partial or complete retention of urine as well as oliguria or anuria. The present study is concerned with the Mutramarga Sankocha, a condition afflicting Mutravaha Srotas. In this condition, there is obstructed urine flow, straining, dribbling and prolonged micturition (Sushruta, 2002). In such condition Uttarabasti of medicated oils is the most effective available treatment described by the seers of Ayurveda. Mutramarga Sankocha can be correlated with stricture urethra. Pathologically it becomes narrowed by a fibrotic tissue, which hampers excretion of urine. In modern science, the suggested treatment is urethral dilatation besides surgical treatment. It may cause bleeding, false passage and fistula formation. The surgical intervention like urethroplasty also carries high grade risk of recurrences (Al-Qudah, 2005). Though the science has developed in many directions, it is unable to provide satisfactory treatment to patients without any complications and recurrences. The features of the urethral stricture can be correlated with the feature of mutrasanga (Ambikadutta Shastri, 2001) which is subtype of mutraghata and where chiefly Apanavayu is vitiated; hence Uttarabasti was selected as the treatment of choice to combat the root cause of mutrasanga. Previous researches also highlighted that, Uttarabasti is effective in providing symptomatic relief in urethral stricture without any side effects (Amilkanthwar, 2004; Dudhamal et al., 2010).

\*Corresponding author: Dr. Joyal Patel

Associate Professor, Department of Shalya Tantra, Shree Gulabkunverba Ayurveda Mahavidyalaya, Gujarat Ayurved University, Jamnagar, Gujarat, Pin -361008, India

DOI: <https://doi.org/10.24941/ijcr.32201.08.2018>

### Images of Retrograde Urethrography

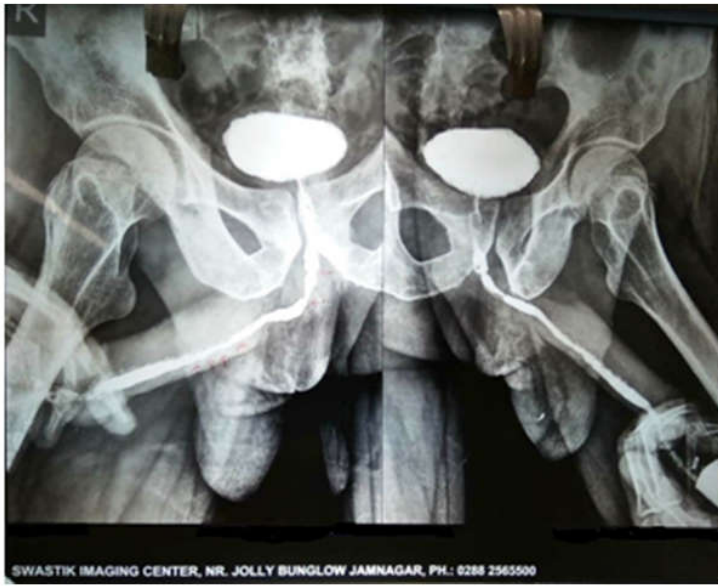


Image.1.1<sup>st</sup> consultation day RUG report (Before treatment)

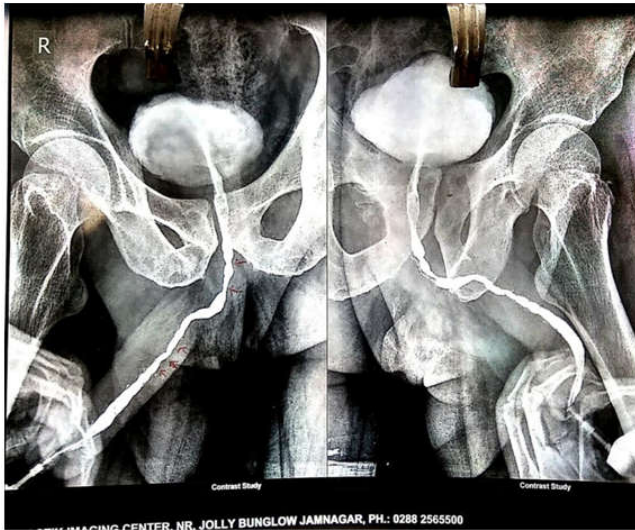

Image 2. After 1 month (During treatment)

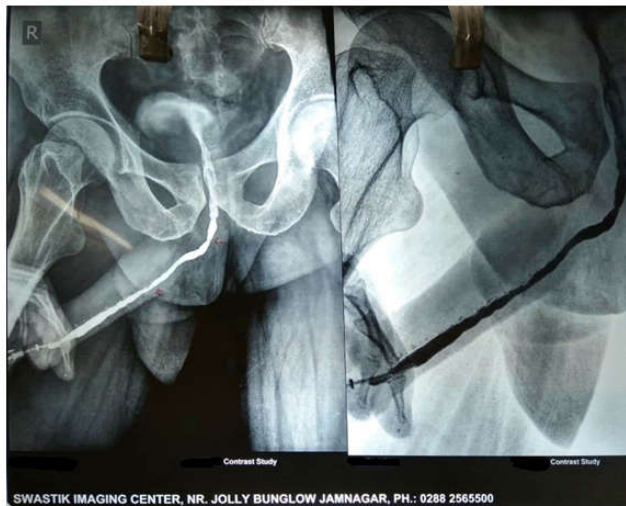


Image 3. After 2 month (After treatment)

This case study Uttarabasti of medicated oil (Bala Taila) showed the good result in the management of urethral stricture and required more no of patients.

**Case Report:** A 55 year old male patient came in OPD of Shalya Tantra at Shree Gulabkunverba Ayurved Hospital on 08/09/2016 with complaints of increased frequency of micturition, nocturia, weak stream, incomplete voiding, dysuria and lower abdominal pain. Patient was suffering from above this complains for 1 year. He had consulted to urologist for this problem but he advised urethoplasty. Patient doesn't want to do surgery, so he come ayurved hospital for treatment.

## MATERIALS AND METHODS

### Material

#### Drugs and their proportions

- Bala Taila-15 ml
- Saindhav-1 gram
- Madhu-4 ml

### Method

**Procedure of Uttarabasti:** Adopted standard procedure of Uttarabasti was followed (Dudhamal, 2010).

### Diagnostic Criteria

**Subjective Parameters:** Diagnosis was based on the clinical signs and symptoms of the disease, which are

- Incomplete emptying
- Frequency
- Weak stream
- Straining
- Nocturia
- Intermittency
- Urgency
- Hesitancy

**Objective Parameters:** Retrograde Urethrography (RUG) & Average Urine flow Rate (AUFR) by manually

## RESULTS AND DISCUSSION

The Basti (urinary bladder) is said to be Vatasthana of Apana Vayu and responsible for normal evacuation of urine, stool, flatus, sperm, etc as quoted in Samhita "Apanoapanagah.... Shukraartava Shakrunmutra garbha niskramana kriyah" The diseases of Mutraghata occur in this region are mainly due to vitiation of Vata Dosha in general and Apana Vayu in particular. Constriction and fibrosis of tissue leads to constriction of urethra due to Khara (rough) and Ruksha (dry) guna of Vata. Due to Chala (movable) guna of Vata, patient had frequent and painful micturation. Hence in case of Mutrotsanga toda (throbbing pain), sankocha (stricture), shosha (dryness), and shoola (pain) occur. In Mutrotsanga Kapha prakopa is also manifested and by the virtue of sthairyga guna (local stasis), gaurava (heaviness in penis), upalepa (narrowing of lumen due to hypertrophied scar tissues), bandha (obstruction to normal flow), and chirkaritva (chronicity) like features occur. Hence combination of vitiation of Vata dosha

+++ and Kapha dosha + were the prime causative factors for urethral stricture. Affected dushya were rasa, rakta and mamsa dhatu because urethral passage is lined by mucous membrane is Shleshmadhara kala which can be considered as updhatu of mamsa that affected mucous membrane which developed the stricture. The one constituent mixture used was Bala Taila in this case study which is made by two ingredients, Tila taila and Atibala at Pharmacy of Gujarat Ayurved University. Tila Taila

(Atridev Gupta, 2005) (Sesame oil) which is Vata shamak (Tailam vatashleshma prashamanam shrestham) produced soothing effect on the tissue at stricture site and also acted as healing agent (Kiran, 2008; Bankole et al., 2007; Charde et al., 2004). It softens tissue, increase elasticity, penetrates up to deep tissues, heales and promotes regeneration. Sesame oil also has properties like vyavayi, sukshma (yasya vivarane shakti), and snigdha (yasya kledane shakti). So it dilates and lubricates the lumen of urethra due to sukshma (micro) and snigdha (oily) gunas respectively. Madhu has the shodhana (purification) and ropana (healing) properties in classic it is quoted that Vranashodhanam ropanam vatalam madhu (Atridev Gupta, 2005) due to antibacterial action (Molan, 1992; Cooper, 2007; Al-Waili, 2004) and Saindhava lavana (rock salt) has lekhana (scraping), margavishodhanakar and shariravayava mridukara properties so both were proven helpful to scrap out the fibrotic tissue and increase the lumen of the urethra. Patient had two strictures in RUG report when patient consulted to Shree Gulabkunverba Ayurved hospital, Jamnagar. (Image.1) After 7 days of treatment it was observed that stream of urination was quite well and passing without straining. It was also noted that 70 % relief in burning micturition and increased frequency. It was also observed that patient got relief in hesitancy and urgency. After 1 month of treatment in RUG report significant resolution of one stricture was observed and patient had got 90% relief from symptoms. (Image.2) After the second sitting of Uttarabasti in second month patient got complete relief from symptoms and one remaining bulbar stricture resolution was observed. (Image.3) There was no adverse effects or complications was found in patient.

## REFERENCES

- Al-Qudah HS, Santucci RA. 2005. Extended complications of urethroplasty. *Int Braz J Urol.*, 31:315-23.
- Al-Waili NS. 2004. Investigating the anti microbial activity of natural Honey and its effects on pathogenic bacterial infections of surgical wounds and conjunctiva. *J. Med. Food.*, 7(2): 210-22
- Ambikadutta Shastri, 2001. Acharya Sudshruta, Sushruta Samhita, Chaukhamba Sanskrita Santhan. p. 425.
- Amilkantwar RH. 2004. Role of Uttarabasti in the management of Mutra Marga Sankoch (urethral stricture). *Indian J Tradit Knowl.*, 3: 177-81.
- Athavale BV. 2004. Urology in Ayurveda. Delhi: Chaukhamba Sanskrit Prakashana; p. 212.
- Atridev Gupta, Acharya Vagbhatta, Astang Haridayam, 2005. Chaukhamba Sanskrita Santhan; p. 47.
- Atridev Gupta, Acharya Vagbhatta, Astang Haridayam, 2005. Chaukhamba Sanskrita Santhan; p. 46.
- Bankole, MA., Shittu, LAJ., Ahmed, TA., Mn Bankole, RK. Shittu, K. Terkula, OA. Ashiru. 2007. Synergistic antimicrobial activities of phytoestrogens in crude exratcts of Two Sesam species against some common

- pathogenic microorganisms. *African journal of Traditional and Complementary medicine*. 4(4), 427-33
- Charde MS., Hemke AT., Fulzele SV., Satturwar PM., Kasture AV., Dorle AK. 2004. Investigation on the wound healing activity of the Tilvadi Ghrita: a herbal formulation. *IJTK*. 3(3): 247-52.
- Cooper R. 2007. Honey in the wound care: Antibacterial properties. *GMS Krankenhhyg Interdiszip*. 2(2): 51
- Dudhamal TS., Gupta SK., Bhuyan C. 2010. Case report: Management of urethral stricture with Uttara Basti. *Anc Sci Life.*, 30:51-3.
- Kiran K., Asad M. 2008. Wound healing activity of Sesamum indicum L. seed and oil in rates; *Indian J Exp Biol.*, 46: 77782
- Molan P C. 1992. The antibacterial activity of Honey. 2. Variation in the potency of the anti bacterial activity. *Bee World*. 73: 59-76
- Sushruta, Sushruta Samhita, 2002. Ayurved Tatvasandipika Hindi Commentary, Uttar Tantra, 58/15-16. Varanasi: Chaukhamba Sanskrita Santhan. p. 425.
- Sushruta, Sushruta Samhita, 2002. Ayurveda Tatvasandipika Hindi Commentary, Uttara Tantra 58/3-4. Varanasi: Chaukhamba Sanskrita Santhan. p. 423.
- Vagbhata, Asthanga Hridaya, Vidyotini Tika, 2007. Sutra Sthana 12/9. Varanasi: Chaukhamba Sanskrita Santhan;. p. 90.

\*\*\*\*\*