



RESEARCH ARTICLE

PRIMARY ANGIOSARCOMA OF BREAST: A RARE CASE REPORT AND ITS MANAGEMENT

^{1,*}Dr. Hemish Kania, ²Dr. Amit Inamdaar and ³Dr. Shashank Bansal

¹Postgraduate Fellow in Surgical Oncology, Dr B Borooah Cancer Institute

²Postgraduate Fellow in Medical Oncology, Dr B Borooah Cancer Institute

³Postgraduate Third year resident in Radiation Oncology, Dr B Borooah Cancer Institute

ARTICLE INFO

Article History:

Received 20th April, 2018

Received in revised form

03rd May, 2018

Accepted 06th June, 2018

Published online 30th July, 2018

Key Words:

Angiosarcoma Breast - Primary,
Secondary,
Sarcoma, Breast Tumours.

ABSTRACT

Mammary sarcomas are a heterogeneous group of malignant neoplasms that arise from the mammary stroma (Farrokh *et al.*, 2006). Angiosarcomas, one of the most common forms of mammary sarcoma, are developed from the endothelial lining of the blood vessels. Angiosarcoma of the breast is an exceedingly rare disease that may occur as a primary neoplasm or as a complication of radiation therapy after breast conservation. Only about 20% of angiosarcomas are primary sarcomas. The incidence of primary breast angiosarcoma is about 17 new cases per million women. Primary angiosarcoma of the breast is exceedingly rare, and represents around 0.04% of malignant breast neoplasms. Its incidence among breast sarcomas varies from 2.7% to 9.1%. Breast angiosarcoma is more frequent in young women (20 to 50 years) like in our case with no previous cancer history or other known risk factors. We present a case of a 42-year-old woman, with a painful slowly growing mass in her left breast over a period of one year which on investigation came out to be primary angiosarcoma of breast.

Copyright © 2018, Hemish Kania *et al.* This is an open access article distributed under the Creative Commons Attribution License, which permits unrestricted use, distribution, and reproduction in any medium, provided the original work is properly cited.

Citation: Dr. Hemish Kania, Dr. Amit Inamdaar and Dr. Shashank Bansal, 2018. "Primary Angiosarcoma of Breast: A rare case report and its management", *International Journal of Current Research*, 10, (07), 71175-71177.

INTRODUCTION

Mammary sarcomas are a heterogeneous group of malignant neoplasms that arise from the mammary stroma (Farrokh *et al.*, 2006). Angiosarcomas, one of the most common forms of mammary sarcoma, are developed from the endothelial lining of the blood vessels (Yang, 2007). Angiosarcoma of the breast is an exceedingly rare disease that may occur as a primary neoplasm or as a complication of radiation therapy after breast conservation. Only about 20% of angiosarcomas are primary sarcomas. The incidence of primary breast angiosarcoma is about 17 new cases per million women (Monroe, 2003). Primary angiosarcoma of the breast is exceedingly rare, and represents around 0.04% of malignant breast neoplasms. Its incidence among breast sarcomas varies from 2.7% to 9.1% (Myerowitz, 1978). Breast angiosarcoma is more frequent in young women (20 to 50 years) like in our case with no previous cancer history or other known risk factors (Agarwal, 1977). Radiologic findings are often non specific and may appear completely normal in one-third of cases with primary angiosarcoma.

While Mammogram frequently miss these lesions, USG and MRI shows promise as imaging modalities. Immunohistological panel including CD31, CD34, CK, vimentin should be used to distinguish from lesions with similar histomorphology to reach the final diagnosis. The prognosis is usually poor because of the high rates of local recurrence and early development of metastasis. Surgical removal followed by adjuvant chemotherapy seems improve the prognosis.

Case summary: We present a case of a 42-year-old woman, with a painful slowly growing mass in her left breast over a period of one year. She had no personal or family history of breast or ovarian cancer. Except the suspect mass, she was in good health.

- The physical examination showed an important asymmetry at the expense of the left breast lower area and it was a blackish skin lesion measuring 2 cm in the lower-medial quadrant. The mass was firm and appears to be fixed to the skin. It measures 13 × 12 cm. No axillary lymphadenopathy was palpated.
- An ultrasound showed a diffuse and ill delimited hyperechogenic infiltration in the inferior portion of the

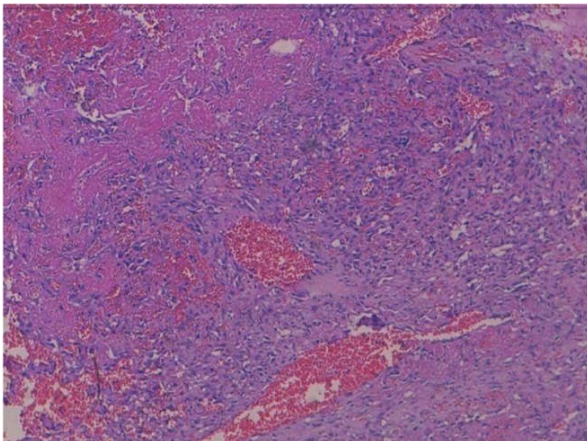
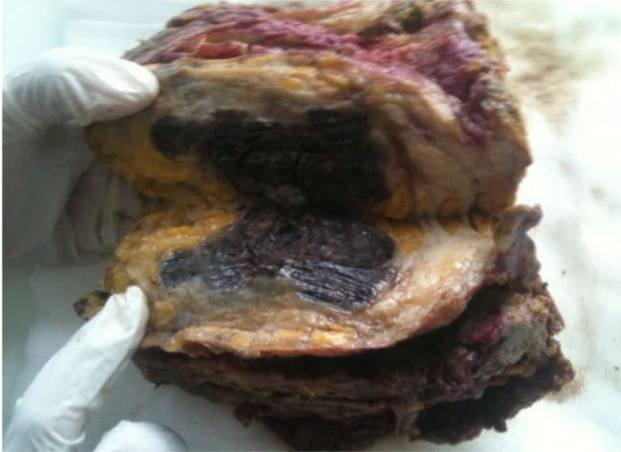*Corresponding author: Dr. Hemish Kania,

Postgraduate Fellow in Surgical Oncology, Dr B Borooah Cancer Institute.

DOI: <https://doi.org/10.24941/ijcr.31334.07.2018>

right breast which is hypervascular on doppler sonography.

- Mammography showed a non specific and diffuse density area of about 12 cm. There was no microcalcification or distortion. The conclusion of radiologist was malign finding.
- A core needle biopsy (CNB) was performed and showed non atypical vascular lesion; this was interpreted as a benign capillary hemangioma. This discrepancy between radiological finding and



- histological results led to the necessity of a macro biopsy.
- However, as the mass was so large and highly vascular at Doppler sonography, macrobiopsy was difficult to perform.
- As consequence, radical mastectomy became more appropriate.
- At gross examination, the mastectomy measured 16 × 12 cm. The tumor entirely replaces the lower quadrants. It was blackish, hemorrhagic and measures 9,2 cm in the greatest dimension . There were mastopathy lesions with cystic in the upper quadrant.(As Shown In Figure)
- Histologically, the tumor was made by papillary formations and vascular structures lined by atypical cells with hyperchromatic nucleus and eosinophilic cytoplasm
- There were solid areas made of spindle cell mostly devoid of vascular formations . Areas of hemorrhage, known as “blood lakes” and necrosis are also seen. The tumor invades the skin and causes its ulceration. Tumor cells are stained with CD31 and CD34 . Cytokeratin AE1/AE3 was negative in solid areas.

- The diagnosis of grade III angiosarcoma of the breast was made.
- The surgical margins were free of tumor.No evidence of Lymphovascular invasion by tumour.
- Whole body Cect did not reveal any metastasis.
- Post operative treatment consisted of adjuvant chemotherapy with paclitaxel on days 1 , 8 and 15 of a 4 week cycle for three cycles
- Followed by radiation therapy 50Gy in 25#
- Patient had completed adjuvant treatment and is doing well.

DISCUSSION

Pathologically, these tumors are subdivided into three groups according to the classification proposed by Donnel and *et al.* Grade I (well differentiated) contains open anastomosing vascular channels that proliferate within dermis, subcutaneous tissue or breast tissue. A single layer of endothelial cells lines these channels, which dissect through the stroma, causing distortion but little destruction of the preexisting lobules and ducts. The endothelial cells are usually flat; the nuclei may be hyperchromatic and contains small nucleoli. Solid and spindle cell foci, blood lakes, and necrosis are not present. Intermediate-grade angiosarcoma differs from low-grade by containing additional cellular foci of papillary formations and/or solid and spindle cell proliferation. The greater part of the tumor, however, is still composed of low-grade histology. Slightly increased mitotic activity is observed.

In Rosen's study, intermediate-grade angiosarcomas behave more like low-grade sarcomas. In grade III endothelial tufting and papillary formations are prominent. Conspicuous solid and spindle cell areas, mostly devoid of vascular formations, are present as well. Mitoses may be brisk, especially in more cellular areas. Areas of hemorrhage, known as “blood lakes,” and necrosis are also seen. Diagnosis prior to surgery, either by FNA (Fine needle aspiration) or NCB, is always difficult. Chen and *et al.* reported a percutaneous biopsy false-negative rate of 37% (Myerowitz, 1978). The final diagnosis in doubtful cases was made by excisional biopsy or was based on the patient's clinical course, which is characterized by episodes of tumor recurrence (Myerowitz, 1978).

- In our case, Biopsy showed a benign hemangioma but at radiology the tumor was ill defined and seemed more aggressive than a simple hemangioma. So Large-core macrobiopsy was mandatory. But as the tumor was highly vascular at doppler sonography, even macrobiopsy was very difficult to perform, consequently the mastectomy was done.
- In most cases, tumor size at diagnosis is larger than 4 cm. Angiosarcomas larger than 5 cm are associated to a shorter disease-free survival than angiosarcomas smaller than 5 cm. Indeed, tumors smaller than 5 cm are usually associated to a better prognosis, even in the presence of worsening factors.
- Surgery is the principal mode of treatment for primary angiosarcoma of the breast and generally consists of a total mastectomy. Hematogenous dissemination is the rule, making axillary lymph node dissection unnecessary. Chemotherapy is observed to be beneficial in high-grade lesions and in the metastatic setting. Preoperative radiotherapy is not indicated in the treatment of angiosarcoma.

- The degree of differentiation has a significant prognostic value, with regard to both local failure and metastases. Well-differentiated tumors (grade I) have a better prognosis and a higher survival with lower metastatic rate. The prognosis for cases of moderate differentiation is not clear due to the limited number of cases. Other characteristics of the tumor which are of lower prognostic value include: cellular appearance, infiltration of the border, number of mitoses and stromal atypia.

Conclusion and Learning Points

- Young woman presenting with highly vascular breast lesion at the time of biopsy should be considered for malignancy until proved otherwise
- High degree of clinical suspicion and adequate immunohistochemistry is required to accurately diagnose and differentiate it from other form of malignancies
- Total mastectomy with adequate negative margins is the mainstay of treatment and axillary dissection is not recommended
- The role of radiotherapy has been supported by studies
- Although there are no chemotherapy regimes our case shows good response to the chemotherapy regimes

REFERENCES

- Monroe AT, Feigenberg SJ, Mendenhall NP. Angiosarcoma after breast-conserving therapy. *Cancer*. 2003 Apr 15;97(8):1832-40.
- Farrokh, D., Hashemi, J., Zandi, B., Angiosarcoma of the Breast; Report of a Case and Literature Review. *Iranian Journal of Radiology*, Winter 2006, 3(2)
- Yang, WT. Mammary Angiosarcomas: Imaging Findings in 24 Patients. *Radiology* 2007;242:725-734. Greene FL, Page DL,
- Fleming ID, *et al.* American Joint Cancer Committee cancer staging manual. 6th ed. New York, NY: Springer-Verlag, 2002; 221–240.
- May DS, Stroup NE. The incidence of sarcomas of the breast among women in the United States, 1973–1986. *Plast Reconstr Surg*, 1991;87:193–194.
- Myerowitz RL, Pietruszka M, Barnes EL. Primary angiosarcoma of the breast. *JAMA* 1978;239:403.
- Agarwal PK, Mehrotra R. Haemangiosarcoma of the breast. *Indian J Cancer*, 1977; 14: 182–185
