



RESEARCH ARTICLE

RADIX ENTOMOLARIS IN MANDIBULAR FIRST MOLAR: CLINICAL APPROACH IN ENDODONTICS

¹Dr. Jagvinder Singh Mann, ²Dr. Sonal Maurya, ²Dr. Ashok Suman and ²Dr. Sunakshi Sharma

¹Associate Professor and Head of Dept., Govt. Dental College and Hospital, Patiala

²PG student, Govt. Dental College and Hospital, Patiala

ARTICLE INFO

Article History:

Received 17th February, 2018
Received in revised form
22nd March, 2018
Accepted 03rd April, 2018
Published online 23rd May, 2018

Key words:

Anatomical variations,
Endodontic treatment,
Mandibular molar,
Radix entomolaris.

Copyright © 2018, Dr. Jagvinder Singh Mann. This is an open access article distributed under the Creative Commons Attribution License, which permits unrestricted use, distribution, and reproduction in any medium, provided the original work is properly cited.

Citation: Dr. Jagvinder Singh Mann, Dr. Sonal Maurya, Dr. Ashok Suman and Dr. Sunakshi Sharma, 2018. "Radix entomolaris in mandibular first molar: clinical approach in endodontics", *International Journal of Current Research*, 10, (05), 69107-69110.

ABSTRACT

The root canal treatment of a mandibular molar with aberrant canal configuration can be diagnostically and technically challenging (1). Normally the permanent mandibular first molar has two roots, mesial and distal. However it may sometimes have an additional root located lingually (the radix entomolaris) or buccally (the radix paramolaris). This case report discusses endodontic treatment of a mandibular first molar with a Radix Entomolaris (RE), which poses an endodontic dilemma for the clinician with respect to diagnosis and subsequent treatment. Clinicians should be aware of these unusual root morphologies in the mandibular first molar which needs strategic treatment as unfilled canals remain a nidus for infection and can compromise treatment outcome (2).

INTRODUCTION

The prevention or healing of endodontic pathology depends on a thorough chemomechanical cleansing and shaping of the root canals before a dense root canal filling with a hermetic seal. An awareness and understanding of the presence of unusual root and its root canal morphology can thus contribute to the successful outcome of root canal treatment (Calberson, 2007). It is known that the mandibular first molar can display several anatomical variations. Carabelli in 1844 first mentioned a major anatomical variant of the two rooted mandibular first molar; a tooth with a third root that is a distolingual root named as the Radix Entomolaris (RE). If this root is placed buccally then it is called Radix Paramolaris (Carabelli, 1844; Calberson, 2007 and Carlsen, 1991), which is even a rarer entity described by Bolk (Bolk, 1915). When found, complete diagnosis and treatment are necessary just like other canals (Pattanshetti, 2008). In this report three such cases are presented. The prevalence, external morphological variations and internal anatomy of the radix entomolaris are described. The clinical approach to diagnosis and endodontic treatment are also discussed and illustrated (Calberson, 2007).

*Corresponding author: Dr. Jagvinder Singh Mann

Associate Professor and Head of Dept., Govt. Dental College and Hospital, Patiala

CASE REPORTS

Case 1: A 16yr old female patient reported to the Department of Conservative Dentistry and Endodontics, Govt. Dental College, Patiala with a chief complaint of throbbing pain in the left lower back tooth region for the past one month. Pain was of intermittent type, aggravated on taking cold foods and persisted even after removal of the stimulus. On examination the left mandibular first molar displayed deep dental carious lesion. Radiographically, a carious lesion was seen encroaching on the pulp space (Fig. 1). A diagnosis of symptomatic irreversible pulpitis was made. Access preparation was done with an endo access bur no.1 (Dentsply Switzerland). The first distal canal has been found slightly away from the centre (buccally), and indicating that the other canal will be on the lingual side. As such the access cavity preparation was modified from a triangular shape to a trapezoidal form and the fourth canal was located (Fig. 2). The root canals were located with DG-16 explorer and patency of canals was made with ISO size #15 (Mani Japan). Working length was determined radiographically (Fig 3 and 4). Cleaning and shaping was done with ProTaper (Dentsply, USA) instruments in a step down manner. Adequate irrigation was performed using 5.25% sodium hypochloride, EDTA and normal saline. Obturation was done using AH plus sealer and corresponding ProTaper gutta percha points (Fig 5 and 6). Access preparation was then restored with composite resin.

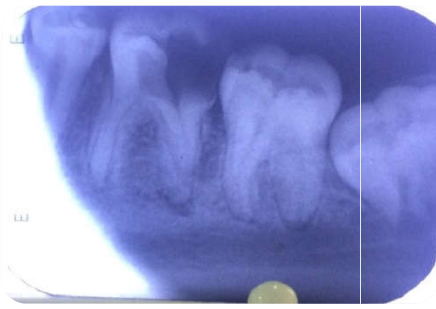

Fig. 1. Preoperative radiograph

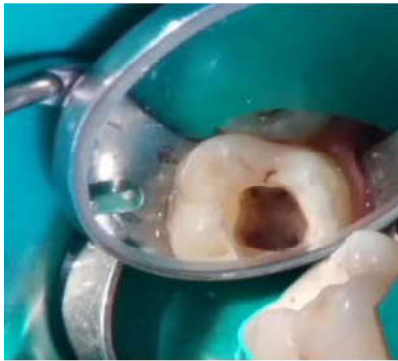

Fig. 2. Access opening

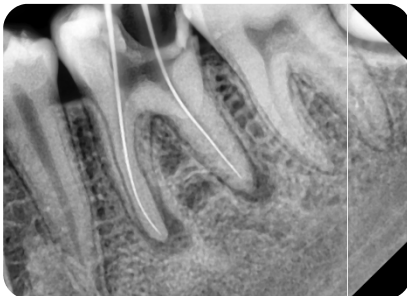

Fig. 3. Working length radiograph

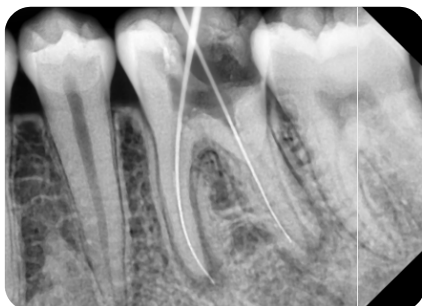

Fig. 4. Radiograph taken with a more mesial angulation

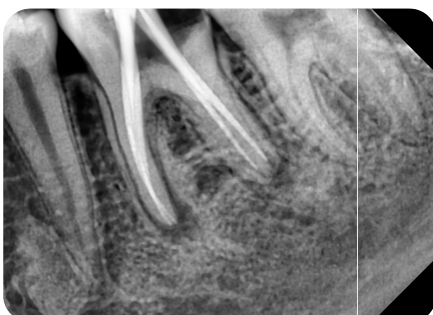


Fig. 5. Master cone radiograph revealing the presence of additional root distolingually

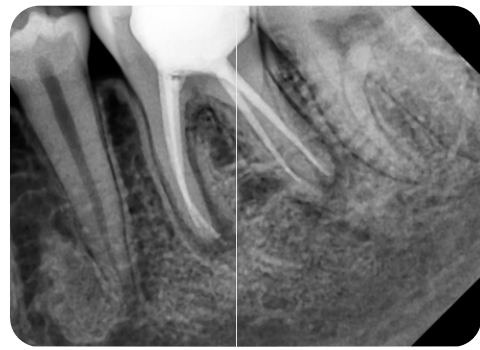


Fig. 6. Post obturation radiograph

Case 2

A 32yr old male patient reported to the Department of Conservative Dentistry and Endodontics, Govt. Dental College, Patiala with a chief complaint of tooth decay in the left lower back tooth. Clinical examination revealed a deep carious lesion of the left permanent first mandibular molar. The tooth was free of symptoms and at the periapical X-ray there was no periapical lesion. The diagnostic radiograph showed radiolucency closed to pulp. On keen observation, there appears to be an additional root between the mesial and distal root radiographically (Fig 7). 2% Local anesthesia was administered and the tooth was isolated under rubber dam. Access opening was done with Endo access bur. Three canals were located but the dentinal map seems to be slightly extending in a distolingual direction. The fourth canal was explored with DG 16 explorer. Working length was determined radiographically (Fig 8), cleaning and shaping was performed with ProTaper instruments. The same irrigation regimen was followed as mentioned in the case report 1. Obturation was done using AH plus sealer and corresponding Pro Taper gutta percha points. Access cavity was restored with composite resin (Fig 9 and 10).

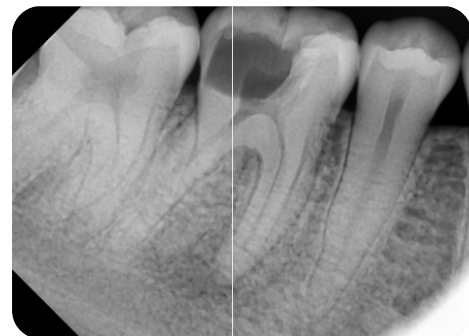


Fig. 7. preoperative radiograph

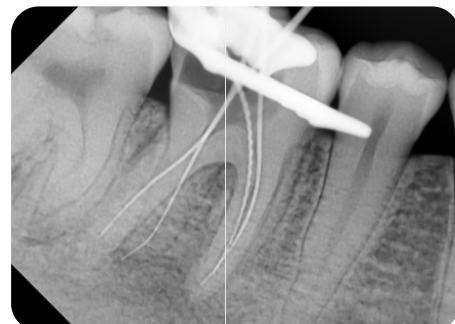


Fig. 8. Working length radiograph

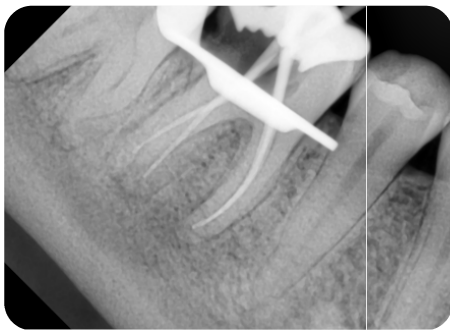


Fig. 9. Martercone radiograph

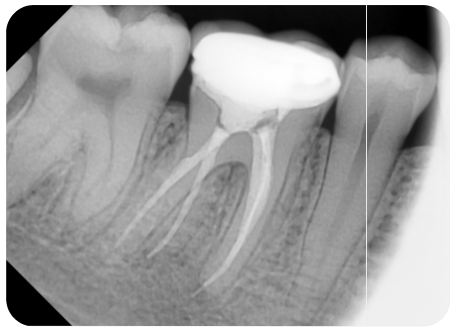


Fig. 10. Post obturation radiograph

Case 3

A 35yr old female patient reported to the Department of Conservative Dentistry and Endodontics, Govt. Dental College, Patiala with a chief complaint of severe pain in the left lower back tooth region for the past four days. Pain was of continuous type and with disturbed sleep. Pain aggravated on taking hot substances and even on mastication. On examination the left mandibular first molar displayed mesioproximal carious lesion closed to pulp. The involved tooth showed a delayed response upon electric pulp testing (Digitest, zeta dental, UK). Thermal testing with cold application (Endo Ice) induced pain that persisted for 5min. Radiograph also revealed an indistinct root canal outline in the middle of the two roots. Inferior alveolar nerve block anesthesia (2% Lignocaine with 1:200000 epinephrines) was given and access cavity preparation was done via endo-access bur and canal orifices were found with a DG 16 endodontic explorer. The access cavity which was triangular in shape was modified into a more trapezoidal cavity in order to locate the fourth orifice distolingually. The canal lengths were determined radio-graphically with K file ISO size #15 (Fig 11 and 12).

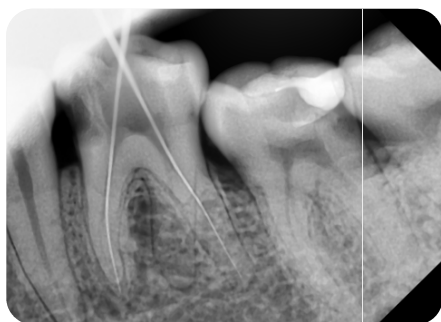

Fig. 11. Working length radiograph

Cleaning and shaping was done with ProTaper instruments in a step down manner. The same irrigation regimen was followed as mentioned in the case report 1. Obturation was done using

AH plus sealer and corresponding ProTaper gutta percha points. Access cavity was restored with composite resin (Fig 13 and 14).

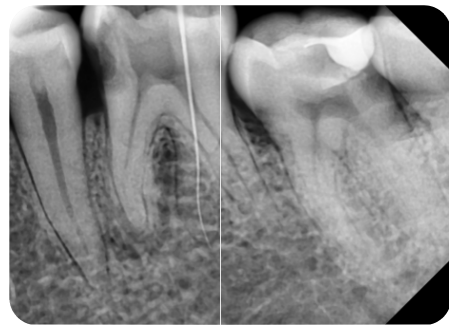


Fig. 12. Radiograph with RE in the middle

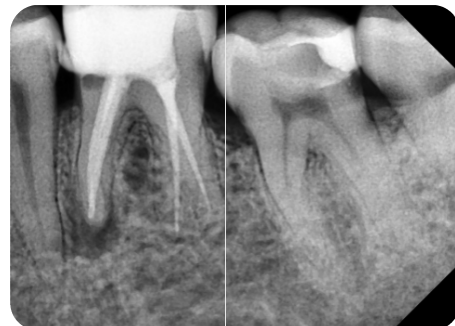

Fig. 13. Post obturation radiograph

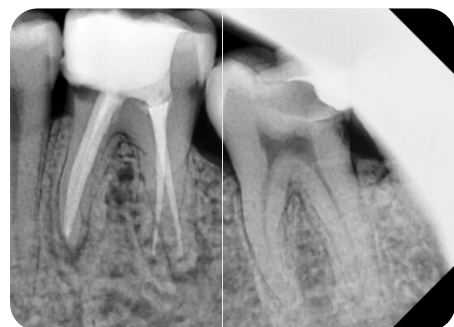

Fig. 14. Radiograph 6months postoperatively

DISCUSSION

A thorough knowledge of root canal morphology and the configuration of the teeth play an important role in the success of endodontic therapy (Kamat, 2015). The presence of a separate RE in the first mandibular molar is associated with certain ethnic groups. In African populations a maximum frequency of 3% is found, while in Eurasian and Indian populations the frequency is less than 5%. In populations with Mongoloid traits reports have noted that the RE occurs with a frequency that ranges from 5% to more than 30%. Because of its high frequency in these populations, the RE is considered to be a normal morphological variant (eumorphic root morphology). In Caucasians the RE is not very common and with a maximum frequency of 3.4 to 4.2%, is considered to be an unusual or dysmorphic root morphology (Tratman, 1938). Bilateral occurrence of the RE ranges from 50 to 67% (Calberson, 2007). The etiology behind the formation of the RE is still unclear. In dysmorphic, supernumerary roots formation could be related to external factors during odontogenesis, or to penetrance of an atavistic gene or

polygenetic system. In eumorphic roots, racial genetic factors influence the more profound expression of a particular gene that results in the more pronounced phenotypic manifestation (Reichart, 1981). RE can be classified into four different types depending on the location of its cervical part (Carlsen, 1990).

- Type A: the RE is located lingually to the distal root complex, which has two cone-shaped Macrostructure.
- Type B: the RE is located lingually in the distal root complex, which has one cone-shaped Macrostructure.
- Type C: the RE is located lingually to the mesial root
- Type AC: the RE is located lingually between the mesial and distal root complexes.

A careful inspection of the radiograph can sometimes reveal the presence of a “hidden” RE as indicated by an unclear view or outline of the distal root contour or the root canal. An accurate diagnosis of these supernumerary roots can avoid complications or a ‘missed canal’ during root canal treatment. Because the RE is mostly situated in the same buccolingual plane as the distobuccal root, a superimposition of both roots can appear on the preoperative radiograph, resulting in an inaccurate diagnosis. To reveal the RE, a second radiograph should be taken from a more mesial or distal angle (30 degrees). This way an accurate diagnosis can be made in the majority of cases. An extra cusp (tuberculum paramolare) or more prominent occlusal distal or distolingual lobe, in combination with a cervical prominence or convexity, can indicate the presence of an additional root. The orifice of the RE is located disto to mesiolingually from the main canal or canals in the distal root. An extension of the triangular opening cavity to the (disto) lingual results in a more rectangular or trapezoidal outline form. Once relocation and enlargement of the orifice of the RE are done, initial root canal exploration with small files (size 10 or 8) should be done along with radiographic assessment of root canal length and curvature determination (Sperber, 1998 and Weine, 2004).

Conclusion

Clinicians should be aware of these unusual root morphological variations of the radix entomolaris in terms of root inclination and root canal curvature. The initial diagnosis of a radix entomolaris or paramolaris before root canal treatment is important to facilitate the endodontic procedure, and to avoid ‘missed’ canals. Preoperative periapical radiographs exposed at two different horizontal angles are required to identify these additional roots.

The initial diagnosis of radix entomolaris is important to facilitate the procedures during treatment and avoid the mislocation of any canal. Root inclination and root canal curvature demand careful, adapted clinical approach to avoid procedural errors during endodontic therapy.

REFERENCES

- Bolk L. Bemerkungen über Wurzelvariationen am menschlichen unteren Molar-en. *Zeitung für Morphologie und Anthropologie* 1915; 17: 605–10.
- Calberson, F.L., De Moor, R.J., Deroose, C.A. 2007. The Radix Entomolaris and Paramolaris: Clinical Approach in Endodontics. *J Endod.*, 33(1): 58–63.
- Calberson, F.L., De Moor, R.J., Deroose, C.A. 2007. The radix entomolaris and paramolaris: clinical approach in endodontics. *J Endod.*, Jan; 33(1):58–63.
- Carabelli, G. 1844. *Systematisches Handbuch der Zahnheilkunde*, 2nd ed. Vienna: Braumüller und Seidel, 1844:114.
- Carlsen, O., Alexandersen, V. 1990. Radix entomolaris: identification and morphology. *Scand J Dent Res.*, 98(5):363–373.
- Carlsen, O., Alexandersen, V. 1991. Radix paramolaris in permanent mandibular molars: identification and morphology. *Scand J Dent Res* 1., 99:189–95.
- Kamat, U., Sheth, H., Mohan, N., Reddy, D. 2015. Endodontic management of radix entomolaris: case reports. *Int J of Applied Dent Sci.*, 2(1): 15–19.
- Pattanshetti1, N., Gaidhane1 M, Al Kandari A. M. 2008. Root and canal morphology of the mesiobuccal and distal roots of permanent first molars in a Kuwait population – a clinical study. *IntEndod J.*, 41:755–62.
- Reichart, P.A., Metah, D. 1981. Three-rooted permanent Mandibular first molars in the Thai. *Community Dent Oral Epidemiol*, 9: 191–192.
- Sarangi, P., Uppin, V.M. 2014. Mandibular First Molar with a Radix Entomolaris: An Endodontic Dilemma. *J of Dent.*, 11(1): 118–22.
- Sperber, G.H., Moreau, J.L. 1998. Study of the number of roots and canals in Senegalese first permanent mandibular molars. *IntEndod J.*, 31:117–22
- Tratman, E.K. 1938. Three-rooted lower molars in man and their racial distribution. *Br Dent J.*, 64: 264 –74.
- Weine, F.S. 2004. Access cavity preparation and initiating treatment. In: Weine FS, ed *Endodontic Therapy*, 6th edition. St. Louis, USA; The C. V. Mosby Company. p.104–63.
