



CASE REPORT

A SILENT EMBOLIZATION OF ATRIAL SEPTAL DEFECT OCCLUDER DEVICE INTO THE RIGHT VENTRICLE

*^{1,2}Vishwanath Hesarur, ^{1,2}Suresh V Patted, ^{1,2}Sanjay Porwal,
^{1,2}Sameer Ambar and ^{1,2}Prasad M.R.

¹Department of Cardiology, Jawaharlal Nehru Medical College, KLE Academy of Higher Education and Research, Deemed to be University, Belagavi, Karnataka, India

²KLES Dr Prabhakar Kore Hospital and Medical Research Centre, Belagavi, Karnataka, India

ARTICLE INFO

Article History:

Received 07th December, 2017
Received in revised form
23rd January, 2018
Accepted 24th February, 2018
Published online 30th March, 2018

Key words:

Atrial septal defect,
Septal occluder device, Embolization,
Migration, Transthoracic echocardiography

ABSTRACT

Percutaneous transcatheter closure is considered alternative to surgery which is technically simple, with shorter procedure time and hospital stay, no median sternotomy scar and faster recovery with comparable rates of complications. Percutaneous transcatheter device closure of ostium secundum atrial septal defect (ASD) was first performed in 1976 by King and Mills. However, this method of closure is associated with infrequently rare early and late complications like device embolization, air embolism, cardiac tamponade, arrhythmias and thrombotic complications. Here we report a rare complication of silent embolization of the ASD occluder device into the right ventricle after 24 hours of successful device closure.

Copyright © 2018, Vishwanath Hesarur et al. This is an open access article distributed under the Creative Commons Attribution License, which permits unrestricted use, distribution, and reproduction in any medium, provided the original work is properly cited.

Citation: Vishwanath Hesarur, Suresh V Patted, Sanjay Porwal, Sameer Ambar and Prasad MR., 2018. "A silent embolization of atrial septal defect occluder device into the right ventricle", *International Journal of Current Research*, 10, (03), 67192-67194.

INTRODUCTION

Atrial septal defect (ASD) is a common congenital heart defect which accounts for 10–15% of all cardiovascular malformation¹. Open heart Surgery is considered to be the gold standard treatment of ASD since the late 1960s with good long term postoperative results². Percutaneous transcatheter closure is considered alternative to surgery which is technically simple, with shorter procedure time and hospital stay, no median sternotomy scar and faster recovery with comparable rates of complications. Percutaneous transcatheter device closure of ostium secundum atrial septal defect (ASD) was first performed in 1976 by King and Mills³. However, this method of closure is associated with infrequently rare early and late complications like device embolization, air embolism, cardiac tamponade, arrhythmias and thrombotic complications. Here we report a rare complication of silent embolization of the ASD

occluder device into the right ventricle after 24 hours of successful device closure.

Case report

A 16 year-old female patient presented with dyspnoea on exertion since one month with past history of recurrent respiratory tract infections in the childhood.

On examination: BP 100/70 mmHg, PR 86/min. No signs of anemia and jaundice. Clinical examination revealed a fixed split second heart sound and a grade 2/6 systolic ejection murmur heard best at the left upper sternal border. The respiratory system, per-abdominal and neurological examination was unremarkable

Investigations: Her electrocardiography revealed sinus rhythm with rsr' in lead V1. 2D transthoracic echocardiography (TTE) showed situs solitus d-loop ventricle, acyanotic congenital heart disease with large ostium secundum ASD measuring 22-23 mm with left to right shunt, superior margin-8 mm, inferior margin-10 mm and retroaortic margin 7 mm, RA/RV dilated, grade I TR with PPG of 36 mmHg, mild PAH, good

*Corresponding author: Vishwanath Hesarur,

Department of Cardiology, Jawaharlal Nehru Medical College, KLE Academy of Higher Education and Research, Deemed to be University, Belagavi, Karnataka, India.
KLES Dr Prabhakar Kore Hospital and Medical Research Centre, Belagavi, Karnataka, India.

biventricular function. Transesophageal echocardiography (TEE) confirmed the findings.

Procedure: The procedure was performed under local anesthesia with TTE guidance. A 30-mm ASD septal occluder device (life tech Heart-R Occluder) was deployed with fluoroscopic and transthoracic echocardiographic guidance. There was no significant residual shunt, no mitral regurgitation or tricuspid regurgitation. Before releasing the device, fluoroscopy and the “Minnesota tug technique” were also used to confirm its position (Figure 1).

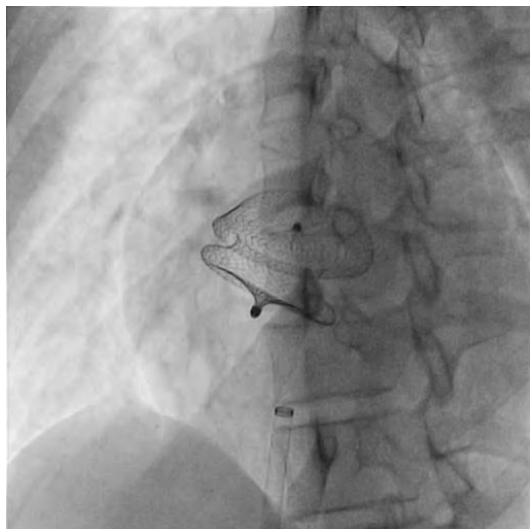


Figure 1. Successful transcatheter ASD device closure with 30 mm ASD occlude device

After 24 hours post device closure, patient complained of dyspnoea and palpitations. On clinical examination, a fixed split second heart sound and a systolic ejection murmur was heard in left upper sternal border. Immediately TTE echo showed ASD device was embolized into the right ventricle partially obstructing tricuspid valve with tricuspid regurgitation. Chest roentgenogram showed the ASD closure device in the right ventricle (Figure 2).

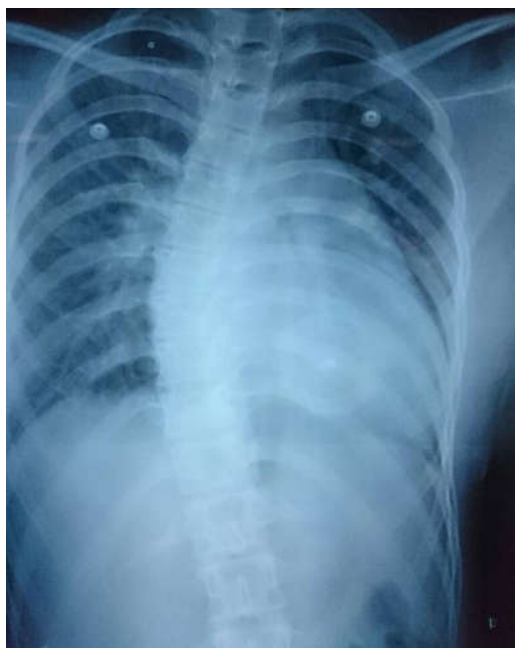

Figure 2. Chest Xray showing the device in right ventricle

It was decided to retrieve the device immediately by a surgical operation, patient was referred for surgical retrieval of the device and closure of the defect, and underwent median sternotomy under general anesthesia, while cardiopulmonary bypass was performed by aorta-bicaval cannulation. The aorta was cross clamped. ASD closure device was removed out of the right ventricle and secundum type ASD primary closure operation was performed through the right atriotomy. Following surgical retrieval, the device was macroscopically intact (Figure 3). Postoperative period was uneventful.

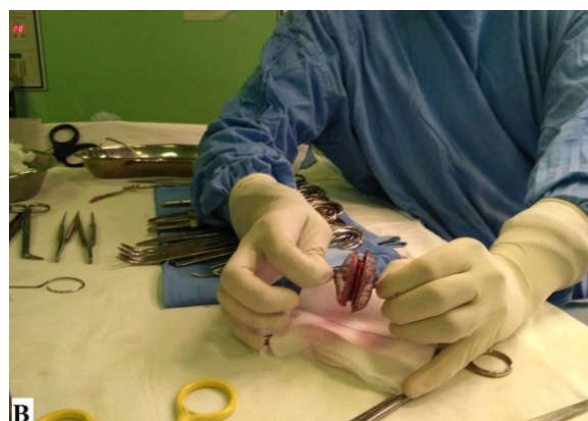
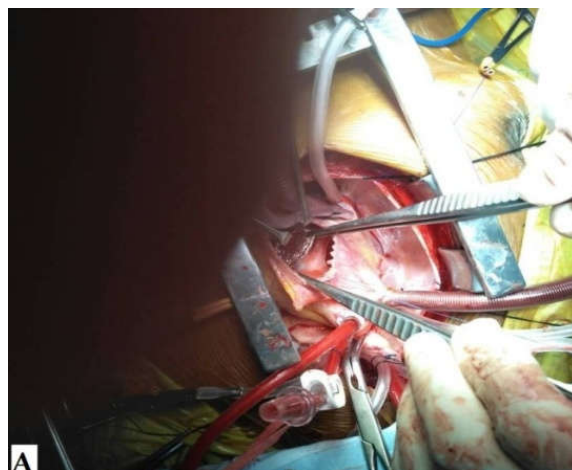


Figure 3. Intraoperative photograph of the retrieved device

DISCUSSION

Percutaneous transcatheter closure of ASD is an alternative treatment to surgical closure. However, it is associated with rare early and late complications such as migration or embolization of the device, pericardial effusion, arrhythmias, thrombus formation on the device, and mitral regurgitation and vascular injury (Berdar *et al.*, 2000; Chessa *et al.*, 2002; Sinha *et al.*, 2004). The most frequent complication is device embolization with incidence ranging from 4% to 21%⁷. Embolization of the device may occur in intra-cardiac (left atrium, right atrium, left ventricle or right ventricle) or extra-cardiac sites such pulmonary and aortic arteries which can cause serious damages. Device embolization usually occurs within 24 hours and after that, it is rarely seen. Factors relating to device embolization are associated with the type of device used, larger size of defect, thin rim of atrial tissue, mobility of device post implantation, use of undersized device and deficiency or absence of aortic rim (Berdar *et al.*, 2000; Chessa *et al.*, 2002; Sinha *et al.*, 2004; Misra *et al.*, 2007).

The aortic rim is very important and a margin <5 mm may predispose to both early and late device embolization⁸. Several studies report that larger ASD (> 20 mm) and device size (> 24 mm) were the most predictor factors related to device embolization which were seen in our patient (Wu *et al.*, 2013). Clinical presentation depends on the site of embolisation. In the majority of cases, device embolization is asymptomatic. In our case, the clinical manifestation was dyspnoea with palpitations could be a ventricular arrhythmia because of the location in the right ventricle partially obstructing the tricuspid valve. Another potential cause of device embolism is acute change in intracardiac pressure due to physical strain. A sudden increase in afterload to the left heart in conjunction with diminished right heart filling (Valsalva) may have favored the migration of the device to the right and subsequently to the right ventricle (Mashman *et al.*, 2005). All patients who undergo device closure are advised to avoid heavy lifting for 3 months post procedure. Mashman *et al.* (2005) also recommended 6 months of avoidance from strenuous exercise for decreasing embolic risk. If the device is embolized, percutaneous or surgical removal of the device is indicated (Mashman *et al.*, 2005). In our case, percutaneous treatment was not considered because of the orientation of the device in the right ventricle, which precluded snaring the device. We subsequently referred the patient to the surgeon.

Conclusion

Device embolization is a rare but potentially fatal complication of transcatheter ASD closure. Surgical removal might be preferred to percutaneous retrieval. Clinical presentations vary greatly depending on localization and orientation of the embolic device. Rarely, the patients with device embolism can be asymptomatic. This case underlines the importance of proper patient selection and routine follow-up after the procedure

Conflict of Interest

The author(s) declare(s) that there is no conflict of interest regarding the publication of this paper.

Informed Consent

Written informed consent was obtained from parent for publication of this case report and accompanying images.

Acknowledgements: None.

REFERENCES

- Van der Linde, D., Konings, EE., Slager, MA., Witsenburg, M., Helbing, WA., Takkenberg, JJ. *et al.* 2011. Birth prevalence of congenital heart disease worldwide: a systematic review and meta-analysis. *J Am Coll Cardiol.*, 58 :2241–2247.
- Tanghøj, G., Odermarsky, M., Naumburg, E. and Liuba, P. 2017. Early Complications After Percutaneous Closure of Atrial Septal Defect in Infants with Procedural Weight Less than 15 kg. *Pediatr Cardiol.*, 38; 255-263.
- King, TD., Thompson, SL., Steiner, C. and Mills, NL. 1976. Secundum atrial septal defect. Nonoperative closure during cardiac catheterization. *JAMA*, 235: 2506–2509.
- Berdat, PA., Chatterjee, T., Pfammatter, JP., Windecker, S., Meier, B. and Carrel, T. 2000. Surgical management of complications after transcatheter closure of an atrial septal defect or patent foramen ovale. *J Thorac Cardiovasc Surg.*, 120:1034-9.
- Chessa, M., Carminati, M., Butera, G. *et al.* 2002. Early and late complications associated with transcatheter occlusion of secundum atrial septal defect. *J Am Coll Cardiol.*, 39:1061-5.
- Sinha, A., Nanda, NC., Khanna, D. *et al.* 2004. Morphological assessment of left ventricular thrombus by live three-dimensional transthoracic echocardiography. *Echocardiography*, 21:649-55.
- Chiappini, B., Gregorini, R., Di Eusanio, M. *et al.* 2008. Embolization of an Amplatzer atrial septal closure device to the pulmonary artery. *J Card Surg.*, 23:164-7.
- Misra, M., Sadiq, A., Namboodiri, N. and Karunakaran, J. 2007. The 'aortic rim' recount: embolization of interatrial septal occluder into the main pulmonary artery bifurcation after atrial septal defect closure. *Interact Cardiovasc Thorac Surg.*, 6:384-6.
- Wu HC, Wang CC, Fu YC, Jan SL, Wei HJ, Lin YK *et al.* Surgical Management for Complications during Closure of Atrial Septal Defect with Amplatzer Device. *Acta Cardiol Sin* 29 (2013): 557-561.
- Mashman, WE., King, SB., Jacobs, WC. and Ballard, WL. 2005. Two cases of late embolization of Amplatzer septal occluder devices to the pulmonary artery following closure of secundum atrial septal defects. *Catheter Cardiovasc Interv.*, 65:588-92.
