



ISSN: 0975-833X

Available online at <http://www.journalcra.com>

International Journal of Current Research
Vol. 10, Issue, 01, pp.64707-64714, January, 2018

INTERNATIONAL JOURNAL
OF CURRENT RESEARCH

RESEARCH ARTICLE

COMPARATIVE EVALUATION OF ORBITAL LESIONS BY ULTRASONOGRAPHY AND COMPUTED TOMOGRAPHY

¹Dr. Kulvinder Singh and ²Dr. Digish U. Vaghela

¹Senior Consultant, Health Map Diagnostics Pvt Ltd, BPS Government Medical College for Women, Khanpur Kalan, Snoepat

²Associate Professor, Radiodiagnosis, B.J Medical College, Ahmedabad

ARTICLE INFO

Article History:

Received 22nd October, 2017
Received in revised form
21st November, 2017
Accepted 22nd December, 2017
Published online 31st January, 2018

Key words:

Orbital,
Ultrasonography,
Computed Tomography,
Pseudotumor.

ABSTRACT

Introduction: Ultrasonography has proved its accuracy in orbital imaging by virtue of its high frequency probes and b mode imaging. The CT extends privilege of perfect anatomical images and better delineation using intravenous contrast. The current study evaluated clinical and radiological presentation of various orbital lesions; and compared diagnostic accuracy of USG and CT.

Material and methods: A prospective observational study was planned at a tertiary teaching institute on 100 patients referred to radiology department for ultrasonography and computed tomography of orbit. Patients with lesions arising primarily from orbit or spread from adjacent structures were included in the study.

Observations: Majority of patients were pediatric; common etiology being retinoblastoma and infection. The central orbital space was most predisposed in inflammatory and vascular lesions: and, peripheral orbital space in neoplastic, trauma, congenital, lacrimal gland and fossa lesions. The diagnostic sensitivity of USG in evaluation of orbital lesions was found to be 93.6 % as against 100% with CT. Diagnostic specificity of CT was higher than USG when single specific diagnosis was given (93% vs 68% respectively), as well as when final diagnosis was given as second differential (96% vs 78.7% respectively).

Conclusion: Orbital vascular lesions and Retinoblastoma can be diagnosed easily on both USG and CT. Both USG and CT failed to differentiate between aspergillosis, mucormycosis and sino-nasal malignancies extending to orbit. CT is more sensitive and specific than USG and should be the preferred modality for suspected orbital lesions.

Copyright © 2018, Dr. Kulvinder Singh and Dr. Digish Vaghela. This is an open access article distributed under the Creative Commons Attribution License, which permits unrestricted use, distribution, and reproduction in any medium, provided the original work is properly cited.

Citation: Dr. Kulvinder Singh and Dr. Digish U. Vaghela, 2018. "Comparative evaluation of orbital lesions by ultrasonography and computed tomography", *International Journal of Current Research*, 10, (01), 64707-64714.

INTRODUCTION

In the present era, imaging the orbit includes a wide variety of techniques. B mode imaging is preferred method of assessment for intraocular lesions and screening modality for extra orbital lesions. The use of high frequency probes has been found to be cost effective, safe, convenient, non-invasive technique providing accurate diagnosis without requirement of sedation (Hemang *et al.*, 2013; Aironi *et al.*, 2009). On the other hand, drawbacks of USG include its operator dependence and inability to define periorbital structures. The introduction of CT provided a more perfect image of orbit, bony encasement with direct soft tissue visualization. Intravenous contrast administration further helps in better tissue characterization and better outlining of tumor margins. Moreover, it provides a road map for the surgeon in assessment of anatomy, vascularity,

tissue invasion and extent of lesion preoperatively. Main disadvantages are ionizing radiation and need for intravascular ionizing contrast media; lesions limited to eyeball are not readily picked up by CT and occasional difficulty in differentiation of inflammatory tissue from neoplastic lesions. The more developed technologies, spiral CT and MRI permit rapid volumetric data acquisition, reconstruction of image, better contrast resolution and multiplanar capabilities. However, main disadvantages are limited accessibility and high cost. Therefore, a study was planned to study demographic, clinical and radiological presentation of various orbital lesions; and, correlate imaging diagnosis of USG and CT with histopathological and/or clinical diagnosis.

MATERIALS AND METHODS

A prospective observational study was planned at a tertiary teaching institute over a period of 2 years after written informed consent and ethical committee approval.

Corresponding author: Dr. Kulvinder Singh,
Senior Consultant, Health Map Diagnostics Pvt Ltd, BPS Government Medical College for Women, Khanpur Kalan, Snoepat.

Convenience sample of 100 consecutive patients referred to radiology department for CT of orbit were taken up for this study. This includes lesions primarily arising from orbit or spread from lesions originating from adjacent structures. Patients with polytrauma who came in golden hour and those with lesions limited to eyeball only were excluded from this trial. Patients who came for CT of orbit were primarily screened by B- mode ultrasonography by author KS: CT was reported by author DV. Both the investigators were blinded to assessment performed using the other modality. USG was performed on "AU3 Partner Esaote Biomedica" with 7.5 and 10 MHZ linear array probes utilizing transocular and par ocular approaches with a combination of transverse, longitudinal and axial views. Both eyes of patient were closed and scanned in supine position. Dynamic study was also done to localize, to know the extent and for exploring lesion's motility. Lesion was considered motile when it moves independently of surrounding normal structures and non motile when it is attached to globe, optic nerve, muscle or bone, either does not move or moves in conjunction with normal structures.

CT of orbit was performed using "SHIMADZU SCT-6800 TX" single slice spiral, 3rd generation scanner, with acquisition of scans at kV- 140 and m A- 60. For axial imaging, patient was placed in supine position; scan plane was drawn with the scan lines parallel to the infraorbital-meatal line, determined by obtaining a lateral digital scout view. Contiguous axial scans of 3mm thickness with 3mm interval were taken. For coronal imaging: patients were placed in prone position with neck extended to the maximum position. Scan plane was obtained roughly perpendicular to the infraorbital-meatal line. Contiguous coronal scans of 3 mm thickness with 3 mm interval were taken by obtaining a lateral digital scout view. Contrast enhancement was done only in patients who posed difficulty in diagnosis. Delayed scans were taken in patients suspected of vascular lesions. Patients were assessed for age, clinical symptoms, orbital spaces involved, echogenicity on USG, NECT density pattern, pattern of contrast enhancement, changes in bony orbit and involvement of adjacent structures. After confirmation of the diagnosis, sensitivity and specificity of each modality was calculated.

Observations

In our study, maximum numbers presented in first decade of life; sex proportion being equal. Majority of the orbital lesions were unilateral (88%); most frequent clinical symptom was proptosis (70%) (Table-1). The inflammatory lesions presenting as painful proptosis and motility dysfunction constituted bulk of patients (36%). Extraconal space is involved in most of orbital lesions constituting 56% of patients and most lesions were neoplastic or inflammatory (Table-2). USG was done in 94% of cases and it was found to be normal in 6% of cases. Most of the lesions (26%) on USG appear hypoechoic like pseudotumors, cellulitis, neural gliomas and other neoplasms. Hyperechogenicity appears to be second most common appearance (21%) seen on USG, most high reflective lesion on USG were lymphoma, cavernous hemangiomas, benign lacrimal tumors and foreign bodies. Lesions isoechoic to EOMs were 14%, mainly graves disease and pseudotumors. Soft tissue density lesions were seen in 64 patients on NECT study, lesions with higher than soft tissue density were seen in 24 patients and mainly include lymphoma and fungal infections. Fat density was seen in only three cases and all three were dermoid cysts.

Further, contrast study was done in 89 cases, out of them homogeneous pattern of contrast enhancement was seen in 54 cases and heterogeneous pattern in another 26. Heterogeneous enhancement was most commonly seen in infective and neoplastic lesions. Non enhancing lesions were mainly congenital and developmental. Further, orbital involvement was seen in around one-third cases, most common involvement pattern was expansion, which was seen in 13 cases (13%) observed with dermoids, pseudotumors and lymphomas. Bony erosion was seen in 10 cases contributed by fungal infections and neoplasms. Bony defects seen in 4 cases among which 2 were neurofibromatosis and 2 were frontal encephalocele. Soft tissue involvement was seen in 11 cases with most lesions being inflammatory. Sino-nasal involvement was seen in 10 cases and lesions were either infective or neoplastic (Table-3). In present study, ultrasonography was not possible in 6 cases: and, in another 6, it failed to demonstrate pathology. Out of 94 cases, it was possible to reach a single specific diagnosis corresponding with final diagnosis in 64 cases; and another 10, as proposed second diagnosis.

The diagnostic sensitivity of USG in evaluation of orbital lesions was found to be 93.6 %.Diagnostic specificity of USG in evaluation orbital lesions when single specific or first possible diagnosis was given, found to be 68 % and 78.7% when a final diagnosis was given as second possible diagnosis. The lesions were identified on CT study in all 100 cases. Among these, it was possible to reach a single specific diagnosis corresponding with final diagnosis in 93 cases and 3 other cases when a second diagnosis was also given. Diagnostic sensitivity of CT was found to be 100 %.Diagnostic specificity of CT when single specific or first possible diagnosis was given, found to be 93% and 96% when a final diagnosis was given as second possible diagnosis.

DISCUSSION

Congenital and developmental anomalies: On both USG and CT, fat-fluid levels and calcification are pathognomonic of orbital dermoids; additionally, scalloped bony orbit and globe contour abnormality being observed in CT (Smirniotopoulos, 1995; Chawada, 1999). The differentiation between orbital dermoids (Figure-1) and epidermoids was not possible on USG and or CT in our study; specificity of USG found to be 80%.Congenital cystic eye, a relatively rare diagnosis was also seen in one case with no identifiable ocular structure and rudimentary EOMs. Optic nerve glioma or orbital plexiformneurofibromafrequently are associated with bony orbital deformity; later associated with orbital-bone changes in four patterns (Jacquemin *et al.*, 2003). In our cases of neurofibromatosis, bony defect, bilateral optic nerve glioma, plexiformneurofibroma and pulsatile exophthalmos with hernia ion brain parenchyma were noted. Among theencephalocele cases, defect in frontal bones bilaterally and in yet another, unilateral sphenoid bone was observed. Another case of Crouzon's disease presented with bilateral exorbitism; USG was normal but CT was diagnostic.

In evaluation of orbital infections, CT has been recommended as imaging modality of choice; USG for monitoring treatment response (David, 1982). Nonetheless, a more recent sonography trial on pediatric patients reinforced its advantages as being reliable in differentiation between pre- and postseptal infection, portability and availability; and, above all, that itdoes not require an anesthetic (Mair *et al.*, 2002).

Table 1.

	Proptosis	Pain	DOV	LOV	MD
Inflammatory Pseudotumor (7)	6	4	3	-	5
Graves ophthalmopathy (9)	8	3	2	-	6
Infective (16)	8	16	6	-	11
Vascular lesions (11)	6	4	5	-	3
Trauma (8)	3	7	2	2	6
Neural tumors (7)	7	5	1	1	-
Other neoplastic lesions (22)	18	11	13	2	12
Congenital & developmental (13)	9	1	3	2	7
Lacrimal gland & fossa lesions except lymphoma (5)	3	3	-	-	2
Others (2)	2	2	2	-	1
Total	70	56	37	7	55

Clinical feature of various orbital lesions. DOV- dimness of vision; LOV – Loss of vision; MD- motility disorder

Table 2.

	Intra ocular	Pre septal	Intraconal		Extraconal	
			Tenons space	Central orbital space	Peripheral orbital space	Sub-periosteal
Inflammatory	-	7	2	16	11	4
Vascular	-	3	-	10	4	-
Trauma	1	1	1	2	6	1
Neoplastic other than vascular	7	1	2	8	14	3
Congenital & Developmental	3	3	1	2	8	-
Lacrimal gland and fossa lesions	-	-	-	1	5	-
Total (%)	11	15	6	39	48	8

Orbital spaces involved by various orbital lesions

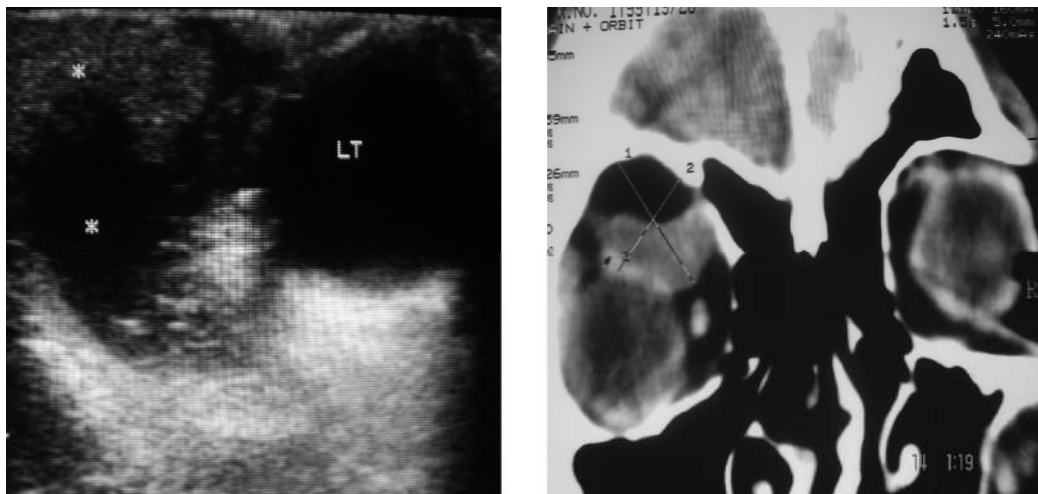

Figure 1. Well defined extraocular orbital dermoid with fluid, fatty and soft tissue attenuation on USG (left) and CT (right)

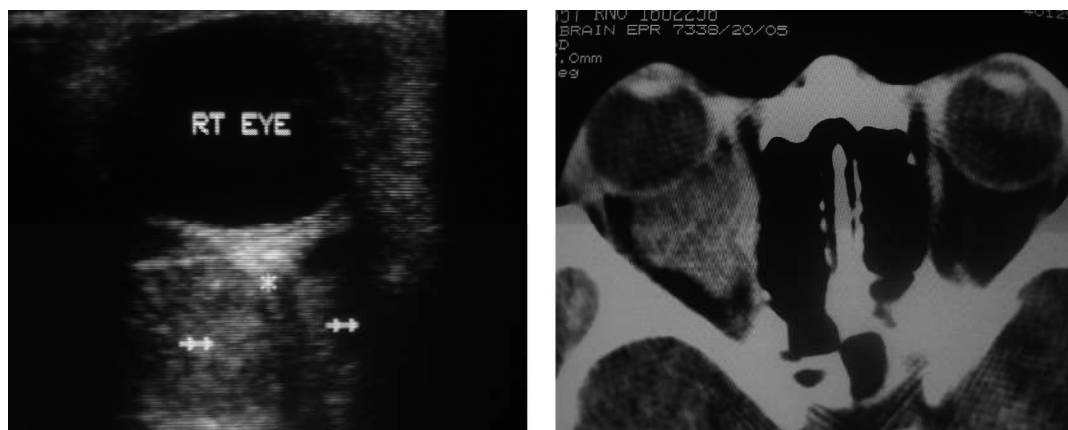


Figure-2: Orbital pseudotumor with bulky extraocular muscles compressing central optic nerve on USG (left) and inhomogeneous soft tissue mass on CT (left)

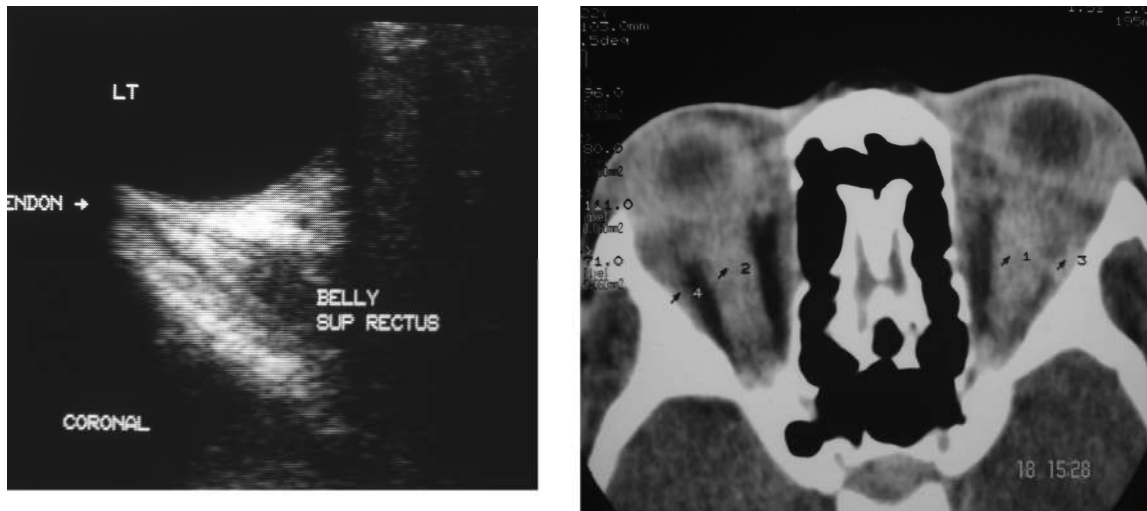


Figure 3. Graves's ophthalmopathy – bulky extraocular muscles on both sides with normal appearing tendon on USG (left) and on CT (right)

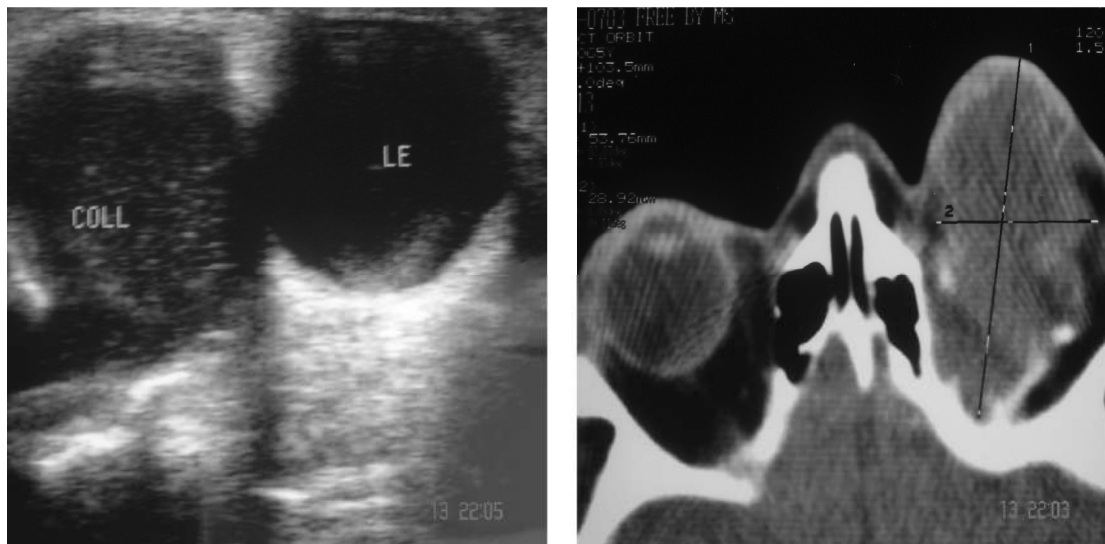


Figure-4: Frontal mucocele – Showing extraocular cystic lesion with internal echoes and bony defect on USG (left) and CT (right)

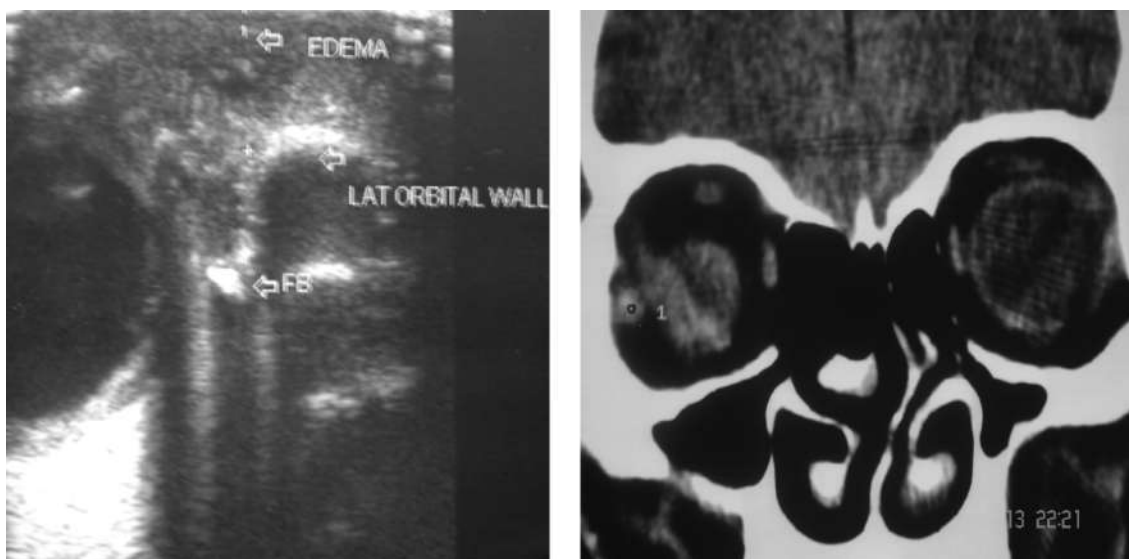


Figure-5: Intraorbital non radio-opaque foreign body with overlying soft tissue edema on USG (left) and CT (right)

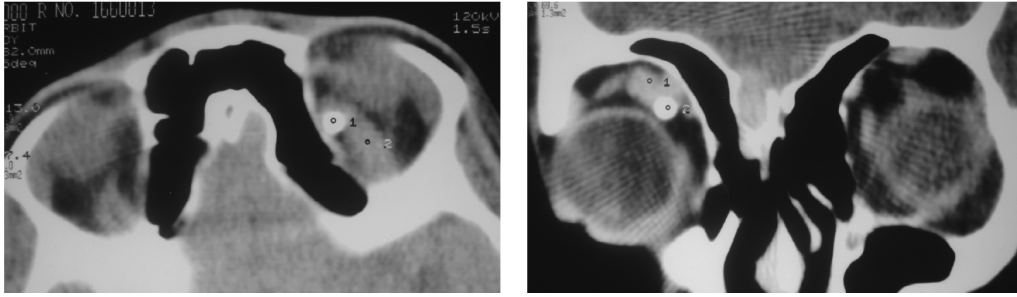


Figure-6. Orbital hemangioma with phlebolith on CT

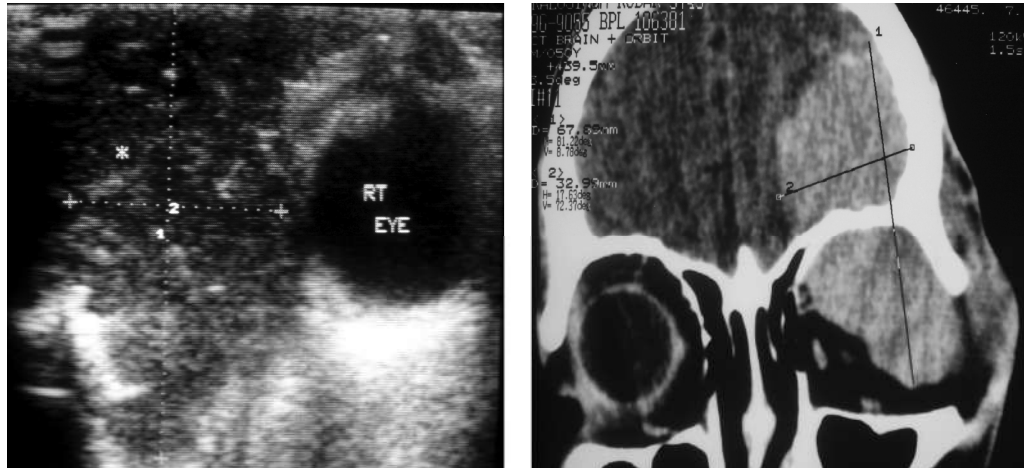

Figure 7. Orbital lymphoma – large lobulated hypoechoic (USG) and homogeneously enhancing (CT) soft tissue mass lesion with intra-orbital extension

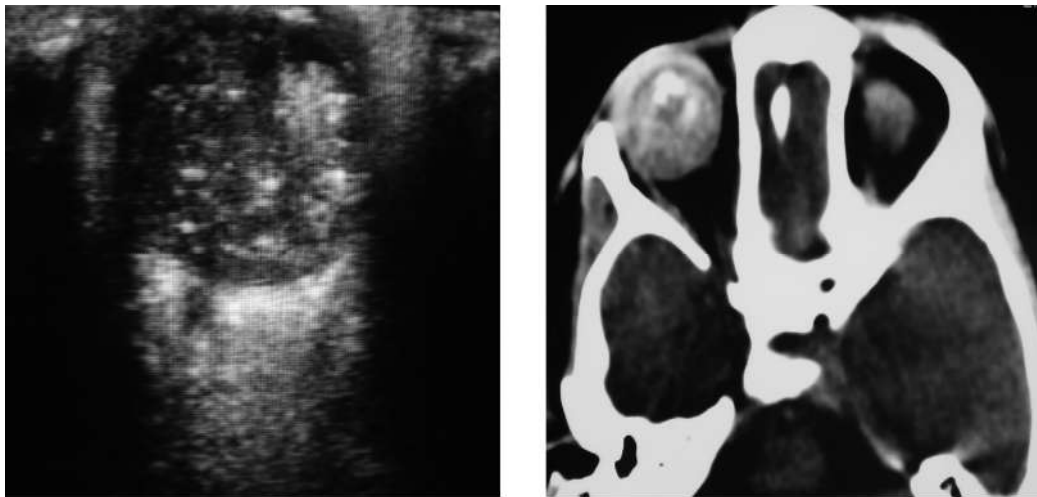


Figure 8. Retinoblastoma – Intra-ocular soft tissue mass lesion with foci of calcifications on USG (left) and CT (right)

In our study, USG was normal in two cases, while CT was diagnostic in all cases with homogeneous enhancement pattern in 5 cases (42%) and ring enhancement was seen in 7 cases (57%). Associated paranasal sinuses involvement, small subtle subperiosteal abscess and extension in soft tissue was better delineated with CT. Association of sinusitis was found in 75% of the cases. Commensurate to our study, literature suggests that on imaging findings, both modalities fail to differentiate between aspergillosis and mucormycosis; invasive fungal infection should be ruled out before giving a diagnosis of sino-nasal malignancy (Mafee, 2003). CT is accurate in identifying extensions of lesion. Orbital myositic pseudotumors can be differentiated by the typical CT findings of enlargement of EOMs, which extend to involve tendon insertions; ragged fluffy

borders of involved muscles; infiltration and obliteration of fat in peripheral orbital space and an inward bowing of medial contour of muscle belly, forming a shoulder as it passes behind the globe (Mafee, 2003; Nugent, 1981). The classical CT findings is contrast enhancing uveal-scleral thickening (Dubey *et al.*, 2003). USG was specific in 4 cases (57%), lesions were predominantly hypoechoic and homogeneous in echo texture. On CT specific diagnosis of pseudo tumor was given in 5 cases (71.4%) with homogeneous contrast enhancement in most of the cases (Figure-2). Graves' ophthalmopathy: CT has been found valuable in detecting early changes in recti muscles, diagnosis in absence of clinical and laboratory evidence and results of orbital decompression surgery (Dubey, 2003; Nugent *et al.*, 1990).

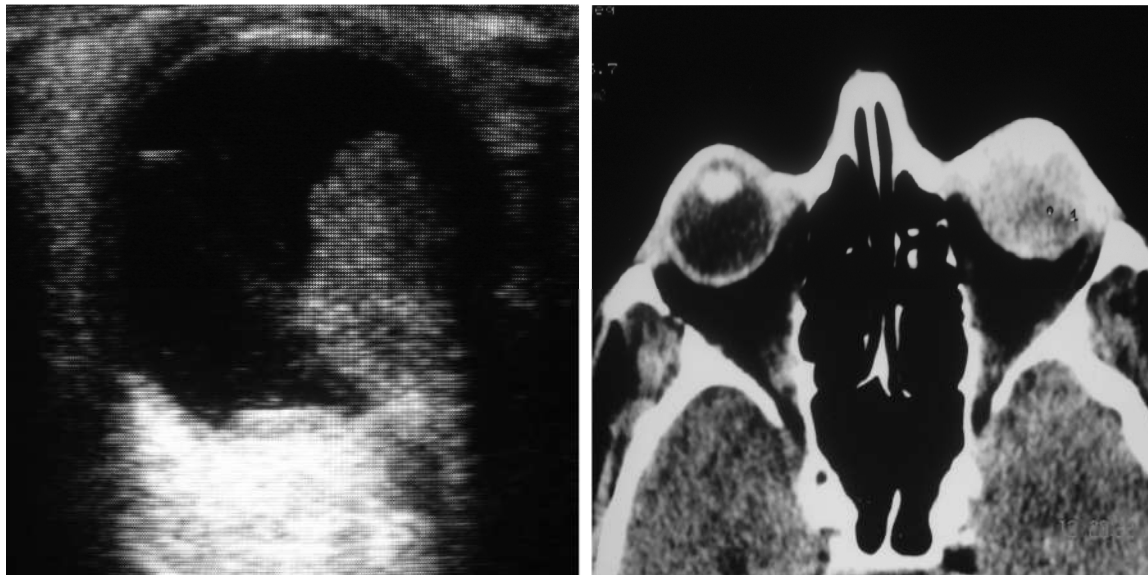


Figure 9. Choroidal melanoma- Eccentric lobulated intraocular soft tissue mass lesion with vitreous hemorrhage appearing hyperdense on CT (right)

In our study, the pattern was commensurate, showing predominantly soft tissue density on NECT and mild to moderate enhancement on CECT. (Figure-3) The enlarged muscles appeared isoechoic to hypoechoic on USG; 6 cases (67%) could be identified on USG, while it failed to detect any changes in 2 cases.

Table 3.

	Number of patients	Percentage
Sino-nasal cavity	10	10%
Pterygo-palatine fossa	4	4%
Intra-cranial	5	5%
Infra-temporal fossa	2	2%
Periorbital soft tissue	11	11%

Involvement of extra-orbital spaces by orbital lesions

Mucocele is well circumscribed, avascular, no compressible lesion usually involving medial or superomedial regions of orbit (Hesslink, 1980). In present study, 2 patients of frontal mucocele presented with proptosis; density higher than soft tissue, with minimal or no enhancement on post contrast study, bony expansion and intraorbital extension (Figure-4). Intracranial extension was seen in one patient by dehiscence of posterior wall of frontal sinus. In imaging of orbital trauma, CT defines the extent of soft tissue injury, bony abnormalities, fractures of orbital apex and fragments of blow out fractures.^{6,10} Its role is indispensable when MRI contraindicated in the presence of intraorbital metallic foreign bodies or when USG examination is not feasible in the acute setting (Kandpal *et al.*, 2006). On the other hand, USG has been shown to be superior to CT in demonstration of intraocular damage associated with intraocular foreign bodies with commonest finding being vitreous hemorrhage and retinal detachment (Hemang, 2013; McNicholas, 1995). Also, the foreign bodies like metal, glass or reflective material show posterior reverberation artifact: surgical material like silicone may show hyper echoic area with acoustic shadowing (Aironi, 2009; Lorente-ramos, 2012; Sharma, 2005). In our experience, radio-opaque foreign body and intraocular hematoma were found with displacement of globe on USG, however, metallic artifacts if present obscured the findings. In non radio-opaque foreign bodies with dislocation of intraocular lens, USG and CT both were effective (Figure-5).

Both CT and USG are sensitive for orbital vascular lesions; specificity of USG is increased with color doppler study. Diagnostic findings on Ultrasonography showed good sound transmission with moderate internal reflectivity and CT scanning demonstrated a well-circumscribed, homogeneously dense mass without bony erosion (Dubey, 2003; Yan, 2012; Harris, 1979). In present study, the lesions were intraconal in central orbital space, in one case lesions were also extending in extraconal space in peripheral orbital compartment. On US all lesions were well defined predominantly hyper echoic and on CT, homogeneous with moderate to intense enhancement; bony expansion was seen in one case. It was possible to make diagnosis in all cases on US and CT (Figure-6). Lymphangiomas are poorly defined with irregular margins, they typically cross anatomic boundaries, more commonly are extraconal but may be intraconal or both. On CT they appear as inhomogeneous lesions of soft-tissue attenuation with variable degrees of inhomogeneous enhancement after administration of contrast material (Dubey *et al.*, 2003; Graeb *et al.*, 1990; Tunc, 1999). In our study, on CT all three cases were diagnosed while on US it was possible to give clear diagnosis in 2 cases only.

In present study USG was 100% sensitive for optic nerve tumors, however, it was not possible to differentiate optic nerve meningioma from optic glioma on two occasions (27%). CT was 100% sensitive and specific in diagnosing optic nerve meningioma and glioma in present study. "Tram tract" sign and optic nerve calcification when seen are diagnostic of optic nerve meningioma, were found in 20% and 40% of the meningioma cases in present study (Kanamalla, 2003). The CT allows correct localisation of lymphoma with involvement superior-lateral quadrant: superior rectus muscle, lateral rectus muscle, lacrimal gland and eyelid (Priego, 2012; Weber, 1986). In our experience, USG demonstrated homogeneous pattern with well defined and iso to hypoechoic in texture. On NECT mean HU density was in range of 65-75 with mild to moderate enhancement seen on post contrast study (figure-7). Bony expansion was seen in two cases and in one intracranial extension was seen through superior orbital fissure. On both the imaging modalities, six cases (86%) of lymphoma were thought as the only diagnosis, while in two cases it was not possible to differentiate it from inflammatory pseudotumor.

Retinoblastoma can be diagnosed easily on both US and CT, due to presence of calcification, lesion involving or evolving from globe, heterogeneous attenuation on both US and CT. However, intraorbital or retro orbital extension is better evaluated with CT (Aironi, 2009; Arrigg, 1983; Hedges, 1984). In present study, patients presented with leukocoria and calcification. It was possible to make sure diagnosis on both US and CT, with CT being more favourable for evaluating per orbital extension (figure-8). Choroidal melanoma, appears as a lenticular-shaped mass arising from the choroid on USG which to assess scleral erosions and extra ocular extension into orbital fat. (figure-9)CT has been found superior in diagnosis, identification of the retinal detachment, depiction of extrascleral tumor extension and retro bulbar extension (Aironi, 2009; Peyster *et al.*, 1985). In our series, diagnosis was aided with both modalities, over and above MRI orbit and CECT thorax was also done in one case of recurrent malignant melanoma with multiple pulmonary cannon ball metastasis. Primary orbital rhabdomyosarcoma mimicks orbital cellulitis clinically; majority of the tumors are extraconal. USG findings are well circumscribed heterogenous mass of low to medium echogenicity; insensitive for depicting intracranial spread (Chung, 2007). CT shows moderately well defined to ill-defined margins, irregular shape, and mild-moderate contrast enhancement; bony destruction, globe distortion and extension to the paranasal sinuses may occur (Khan, 2012). CT plays an important role in the preoperative evaluation, evaluating recurrent and residual diseases on follow-up (Mahmood, 1998). In our study, USG was inconclusive in one case of orbital rhabdomyosarcoma and infective etiology was suggested in other. CT was diagnostic in both cases. Metastasis is the first manifestation of the disease, with skeletal metastases being more common (Ruppert, 1989). In present study, one of the cases was metastasis of squamous cell carcinoma of oesophagus, with orbital lesion invading the sinonasal cavity and PP fossa; on CT, however, a diagnosis of fungal infection was thought.

Majority of cases with orbital involvement have monostotic fibrous dysplasia, with the frontal bone followed by the sphenoid (as in our study): ethmoid being most commonly affected. Radiologic ally, fibrous dysplasia distorts and expands bone, with the degree of radiolucency varying with the ratio of mineralized to fibrous tissue. A pagetoid appearance is most frequent but there may also be cystic and more sclerotic or "ground glass" areas (Selva, 2004).Lacrimal Gland And Fossa Lesions: Dacryocystitis is usually diagnosed clinically however imaging study is required to rule out orbital abscess, on CT it appears as enlarged lacrimal sac centered around lacrimal fossa (Kassel, 2003; Hornblass, 1984). Among the lacrimal gland masses, benign cases showed enlargement of lacrimal fossa without destruction. The malignant cases present with pressure changes, bony destruction and calcification to variable degree (Stewart *et al.*, 1979). In our cases, dacryocystitis presented CT as soft tissue density partially cystic lesion, with septal and peripheral enhancement located in lacrimal fossa, no evidence of orbital infection seen in either case. The limitation of our study include limited sample size and low external validity of demographic data. For future research, the role of MRI can be evaluated in terms of its diagnostic accuracy in orbital lesions. Also, prospective studies planned on specific orbital lesions may provide more insight into the diagnostic challenge posed by each lesion.

Conclusion

Maximum number of patients were pediatric; common etiology being retinoblastoma and infection. Pain and motility disturbance is more indicative of inflammatory lesion; proptosis with motility disturbance suggests likelihood of neoplastic diseases. The central orbital space was most predisposed in inflammatory and vascular lesions: and, peripheral orbital space in neoplastic, trauma, congenital, lacrimal gland and fossa lesion. CT should be modality of choice in case of orbital infections, orbital traumatic lesions and optic nerve tumors. Both USG and CT failed to differentiate between aspergillosis, mucormycosis and sino-nasal malignancy. Orbital vascular lesions and retinoblastoma can be diagnosed easily on both USG and CT. CT is more sensitive and specific than USG and should preferred modality for suspected orbital lesion.

REFERENCES

- Aironi VD, Gandage SG. 2009. Pictorial essay: B-scan ultrasonography in ocular abnormalities. *The Indian Journal of Radiology and Imaging*. 19 (2):109-115.
- Arrigg PG, Hedges TR 3rd, Char DH. 1983. Computed tomography in the diagnosis of retinoblastoma. *Br J Ophthalmol*. 67(9):588-91.
- Chawada SJ, Moseley IF. 1999. Computed Tomography of Orbital Dermoids: A 20-years Review. *Clinical Radiology*: 54:821-825.
- Chung EM, Smirniotopoulos JG, Specht CS, Schroeder JW. 2007. Pediatric Orbit Tumors and Tumor like Lesions: Nonosseous Lesions of the Extraocular Orbit1. *Radiology Graphics*., 27:1777-99.
- David LH, Quencer RM, Abrams GW. 1982. Computed tomography and ultrasound in evaluation of orbital infection and pseudotumor. *Radiology*., 142:395-401.
- Dubey RB, Tara NP, Sisodiya KN. 2003. Computerised tomographic evaluation of orbital lesions: Pictorial essay. *Indian J Radiol Imaging*. 13:261-70.
- Graeb DA, Rootman J, Robertson WD, Lapointe JS, Nugent RA, Hay EJ. 1990. Orbital lymphangiomas: clinical, radiologic, and pathologic characteristics. *Radiology*: 175(2): 417-21.
- Harris GJ, Jakobeik FA. 1979. Cavernous hemangioma of the orbit. *J Neurosurg*., Aug;51(2):219-28.
- Hedges, TR. Retinoblastoma. 1984. CT diagnosis. 91(11):1347-50
- Hemang DC, Gurudatt NT, Gandhi VS, Darji PJ. 2013. Role of ultrasonography in evaluation of orbital lesions. *Gujarat Medical Journal*; 68(2):73-78.
- Hesselink KR, Davis JR, Weber AL, Davis JM, Taveras JM. 1980. *Radiological evaluation of orbital metastases, with emphasis on computed tomography*. *Radiology*; 137(2): 363-6.
- Hornblass A, HerschornBJ, Stern K, Grimes C. 1984. Orbital abscess. *Surv Ophthalmol*: 29:169-178.
- Jacquemin C, Bosley TM, Svedberg H. 2003. Orbit Deformities in Craniofacial Neurofibromatosis Type 1. *Am J Neuroradiol*: 24:1678-1682.
- Kanamalla US. 2003. The Optic Nerve Tram-Track Sign. *Radiology* 227:718-719.
- Kandpal H, Vashisht S, Sharma R, Seith A. 2006. Imaging spectrum of pediatric orbital pathology: a pictorial review. *Indian J Ophthalmol*., 54(4):227-36.
- Kassel EE, Schatz CJ. 2003. Lacrimal apparatus. *Head and Neck imaging*, 4th edi. Missouri, Mosby: 529-645

- Khan SN, Sepahdari AR. 2012. Orbital masses: CT and MRI of common vascular lesions, benign tumors, and malignancies. *Saudi Journal of Ophthalmology.*, 26(4):373-383.
- Lorente-ramos RM, Armán JA, Muñoz-hernández A, Gómez JM, De la torre SB. 2012. US of the eye made easy: a comprehensive how-to review with ophthalmoscopic correlation. *Radiographics.* 32(5):E175-200.
- Mafee MF. 2003. Head and Neck imaging, 4th ed. Missouri, Mosby: 529-645.
- Mahmood F. 1989. Mafee, Eugene Pai, Binu Philip: Rhabdomyosarcoma of the orbit: Evaluation with MR Imaging and CT. *Radiology Clinics* 1998;36(6):1215-27.
- Mair MH, Geley T, Judmaier W, Gassner I. 2002. Using Orbital Sonography to Diagnose and Monitor Treatment of Acute Swelling of the Eyelids in Pediatric Patients. *Am J Roentgenol.*, 179(6):1529-34.
- McNicholas MM, Brophy DP, Power WJ, Griffin JF. 1995. Ocular trauma: evaluation with US. *Radiology.m* 195(2): 423-7.
- Nugent RA, Belkin RI, Neigel JM, Rootman J, Robertson WD, Spinelli J, 1990. Graeb DA Graves orbitopathy: correlation of CT and clinical findings. *Radiology:* 77(3): 675-82.
- Nugent RA, Rootman J, Robertson WD, Lapointe JS, Harrison PB. 1981. Acute orbital Pseudotumors: Classification and clinical features. *Am J Roentgenol.*, 137:957-62.
- Peyster RG, Augsburger J, Shields J, Satchell TV, Markoe A, Clarke K, Haskin ME. 1985. CT of Choroidal Melanoma: A Comparison with Ultrasound and Clinical Evaluation. *Radiology.*, 156:675-680.
- Priego G, Majos C, Climent F, Muntane A. 2012. Orbital lymphoma: imaging features and differential diagnosis. *Insights into Imaging.*, 3(4):337-344.
- Ruppert D, Neela L. The many faces of neuroblastoma. *Radiographics:* 9 (5):859-882
- Selva D, White VA, O'Connell JX, Rootman J. 2004. Primary Bone Tumors of the Orbit. *Survey of ophthalmology:* 49(3) : 328-342
- Sharma OP. 2005. Orbital sonography with it'sclino-surgical correlation. *Ind J RadiolImag* 2005; 15(4):537-554
- Smirniotopoulos JG, Maria VC. 1995. Teratomas, Dermoids and Epidermoids of head and neck. *Radio Graphics.*, 15:1437-1455.
- Stewart WB, Krohel GB, Wright JE. 1979. Lacrimal gland and fossa lesions: an approach to diagnosis and management. *Ophthalmology:* 86:886-895.
- Tunç M, Sadri E, Char DH 1999. Orbital lymphangioma: an analysis of 26 patients. *Br J Ophthalmol.*, 83:76-80.
- Weber AL, Darrow RL, Oot RF. 1986. Computed tomography of lymphoproliferative disease of the orbit. Report of 50 patients. *ActaRadiolSuppl.*, 369:333-6.
- Yan J, Wu Z. 2004. Cavernous hemangioma of orbit: analysis of 214 cases. *Orbit.*, 23(1):33-40.
