



ISSN: 0975-833X

Available online at <http://www.journalcra.com>

International Journal of Current Research  
Vol. 10, Issue, 01, pp.64702-64706, January, 2018

INTERNATIONAL JOURNAL  
OF CURRENT RESEARCH

## RESEARCH ARTICLE

### PENETRATING EYE INJURY: A CASE STUDY

**\*Dr. Sachin Agrawal**

Indira Gandhi Government Medical College, Nagpur

#### ARTICLE INFO

##### Article History:

Received 17<sup>th</sup> October, 2017  
Received in revised form  
21<sup>st</sup> November, 2017  
Accepted 22<sup>nd</sup> December, 2017  
Published online 31<sup>st</sup> January, 2018

##### Key words:

Penetrating,  
Eye injury,  
Iron nail.

#### ABSTRACT

Ocular trauma resulting eye injuries are a frequent threat to vision worldwide. The causes of eye injury are diverse, but the risk and type of injury is often correlated with age, gender, and race. While a focused history and prompt ocular examination are essential to immediate management, patient education regarding safety precautions and risk reduction help to prevent future recurrences.

This article describes a case of penetrating eye injury in a 25-year-old male. The case discussion will review the initial examination and management decision. A suggested approach to the management of patients with ocular trauma will be discussed.

Copyright © 2018, Dr. Sachin Agrawal. This is an open access article distributed under the Creative Commons Attribution License, which permits unrestricted use, distribution, and reproduction in any medium, provided the original work is properly cited.

Citation: Dr. Sachin Agrawal. 2018. "Penetrating Eye Injury: A Case Study", *International Journal of Current Research*, 10, (01), 64702-64706.

## INTRODUCTION

Intact binocular vision plays an important role in development, independence, quality of life, and personal safety. Ocular injury is a frequent and preventable cause of visual impairment. The lifetime prevalence of sustaining any type of ocular trauma approaches 19.8% (Wong). Eye injury covers a broad range of severity, from a small corneal epithelial abrasion to the more severe penetrating and globe rupture injuries. The pediatric age group accounts for 8-14% of all eye injuries. Pediatric ocular injury is usually accidental and uniocular (Scribano, 1997; Takvam, 1993). In contrast, adult ocular injury is usually the result of intentional assault. Males are more often affected than females, at a rate approximating 4:1, and suffer injury at a younger age (Wong; Dannenberg et al.; Dannenberg). Patients with a prior history of ocular trauma have a threefold increase in recurrence risk in a five-year period compared to those without prior injury (Wong). Prompt evaluation and appropriate management of ocular injuries are paramount in the preservation of vision. Visual acuity, presence of an afferent pupillary defect, the type of injury, the location, and extent of penetrating injury, type of lens damage, presence and severity of vitreous hemorrhage, presence of and composition of intraocular foreign bodies mostly contribute to the final visual outcome in patients suffering penetrating ocular injuries (DeJuan, 1983). In this article, we describe the evaluation and management of penetrating injury in a 25-year-old male.

## Case report

25-year-old male patient who presented to emergency department with history of sudden fall of something from the roof into the right eye. Following which he started complaining of sudden severe pain in right eye and a visible foreign body in right eye. He was a centring worker by occupation. There were no complaints related to the left eye. He denied wearing any protective or prescription glasses at the time. He had no past history of ocular trauma, ocular surgery and glasses. Past medical history was unremarkable, and he was not on any medications. Family history was noncontributory. On examination 25-year-old male in acute ocular distress. On examination, his vision was light perception in the right and 6/6 in the left eye. The flashlight examination revealed no facial abnormalities. The right eye had a penetrating Iron nail in the center of cornea and hanging outside the globe. (Fig. 1) The right pupil was very difficult to evaluate due to the presence of foreign body in the eye. The right eye anterior chamber was irregular in depth with blood clots. Visualization of the lens was obscured by the foreign body. (Fig. 2) The left eye pupil was round, about 3.5 mm in diameter constricting to about 2.5 mm on direct light exam. The pupil also reacted normally to accommodation. Examination of the anterior and posterior segments of the left eye was normal without signs of trauma. Given the extent of the penetrating eye injury, the ocular examination was terminated and the patient was prepared for surgery. A pre-surgical X Ray of the orbits revealed a single Iron nail about 5.5 cm in length penetrating the right globe (Fig. 3).

\*Corresponding author: Dr. Sachin Agrawal,  
Indira Gandhi Government Medical College, Nagpur.




Fig. 1.

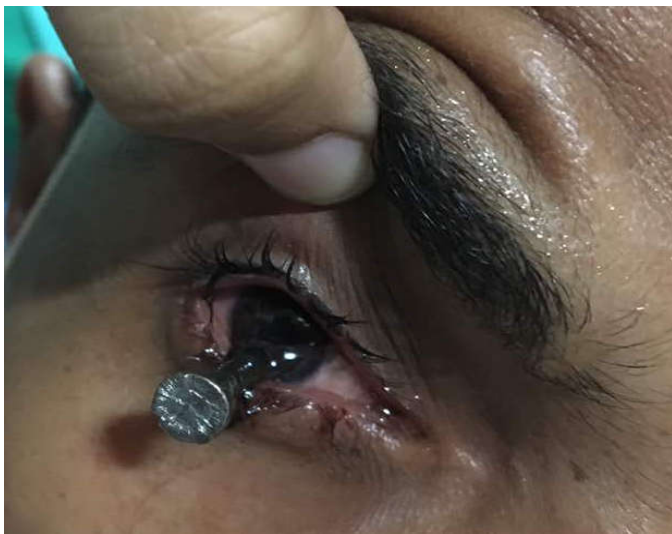

Fig. 2.

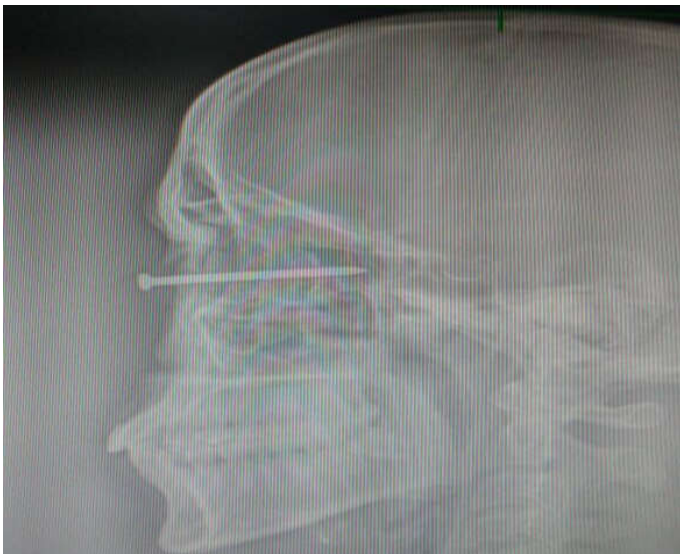

Fig. 3.

Otherwise, all the other orbital structures were normal. The diagnosis of penetrating eye injury with iron nail in situ was made. The patient was given analgesic for pain control, and informed guarded consent was obtained from the relatives. The patient was prepared for surgery under sedation with peribulbar anesthesia.

In the operative suite the right eye was carefully prepared with 5% Betadine and a sterile eye drape was placed. Examination under anesthesia revealed a single long iron nail penetrating the right globe perpendicularly from the center of the cornea and the pupil inside the eye. (Fig. 4) So, the further plan of action was decided to remove the foreign body and do the primary repair of the wound. Attempt of removal of the foreign body by simple pulling failed, because of severe fibrinous adhesions. So with the help of artery forceps a forceful attempt to pull out the foreign body was made and a single large metallic nail was removed in a single piece. (Fig. 5)

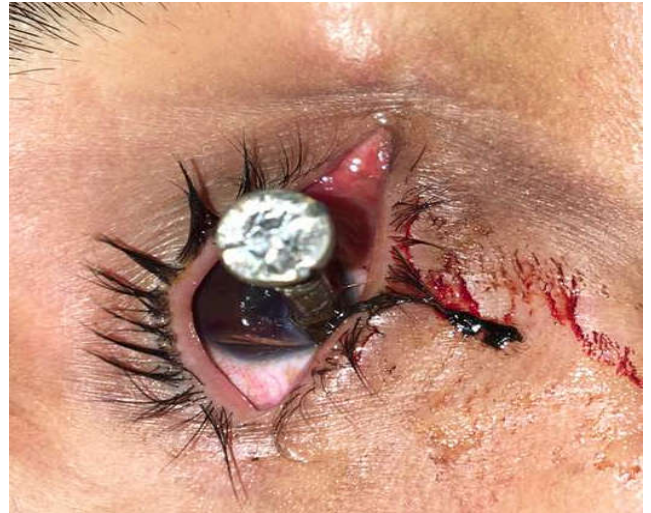

Fig. 4.

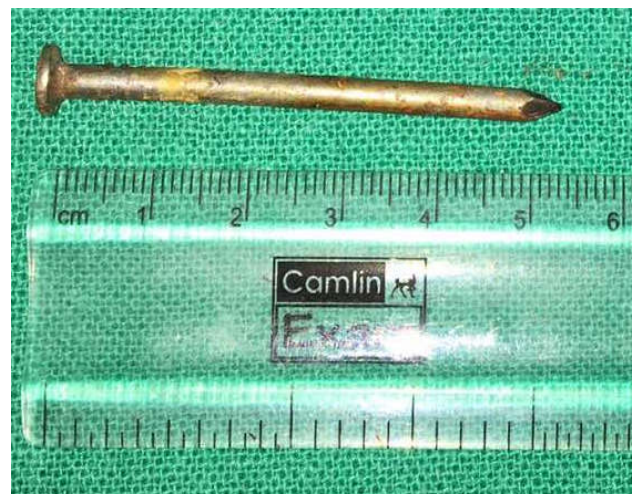


Fig. 5.

Then the extent of injury was judged. Six interrupted 10-0 nylon sutures were placed to reapproximate the corneal wound. The hyphema was aspirated and the anterior chamber was formed with air bubble. (Fig. 6) Subconjunctival injections, including 100 mg of cefazolin and dexamethasone 2 mg, were given inferiorly. At the end of the procedure topical 1% atropine, prednisolone acetate 1% and Moxifloxacin were administered and eye was padded. He was then taken to the recovery area and later admitted in stable condition. On day two of admission right eye of patient was quiet with intact suture in the cornea and well-formed anterior chamber. (Fig. 7) Patient was started with topical Moxifloxacin and prednisolone acetate hourly with atropine ointment three times a day. Patient was also administered intravenous Cefotaxim 1gm BD and analgesic.



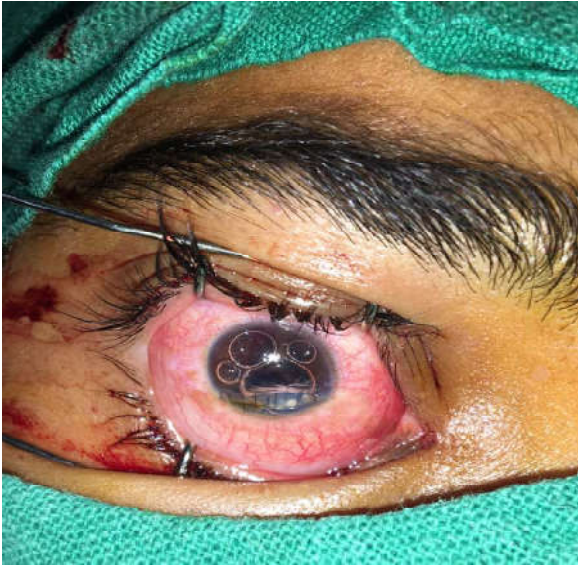

Fig. 6.

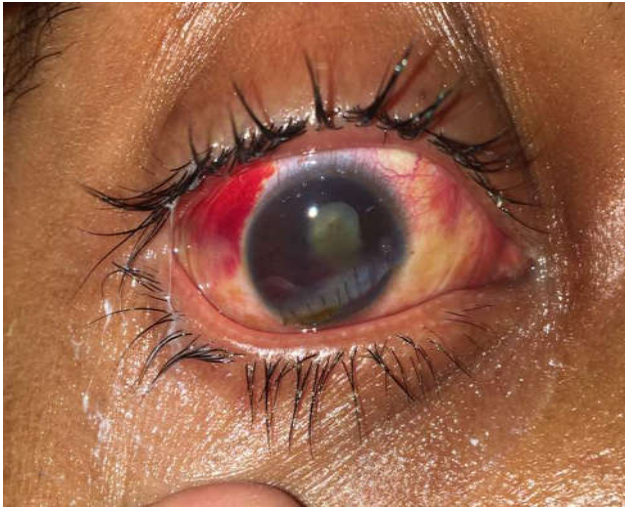

Fig. 7.

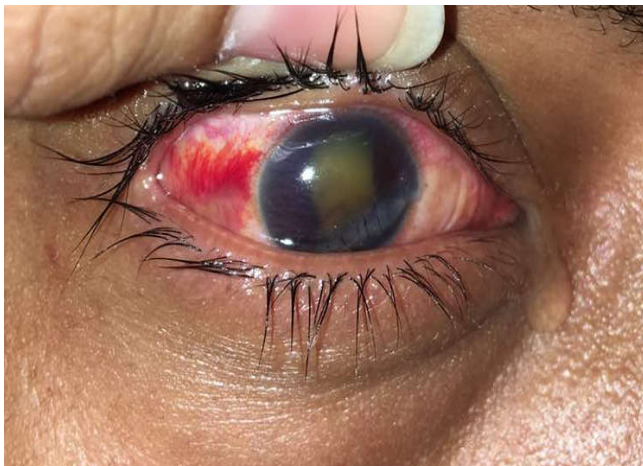

Fig. 8.

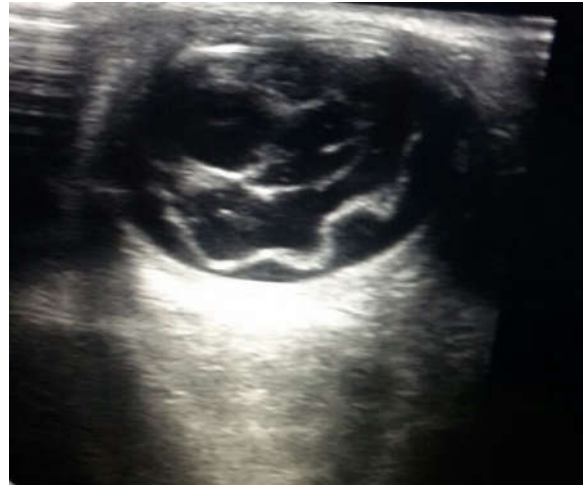

Fig. 9.

## DISCUSSION

Ocular injury is classified into blunt or penetrating, depending on the causative factor. Blunt ocular trauma can be defined using the basic physics concept of energy exchange. Energy is transferred between the injurious object and periocular or globe structures without intrusion of the injured tissue by the offending object ([www.doh.wa.gov/hsqa/emstrauma/OTEP/bluntrauma.ppt](http://www.doh.wa.gov/hsqa/emstrauma/OTEP/bluntrauma.ppt). Accessed 8/30/08.). Penetrating injury involves intrusion into the injured tissue by the offending agent. Blunt trauma can produce a very different clinical scenario and pattern of tissue injury when compared to that of penetrating injury. Classifying the injury as blunt or penetrating early in the patient interaction will facilitate a more focused and effective exam, reducing the time required to provide definitive management. Initial evaluation and identification of penetrating ocular injuries is important in minimizing further ocular complications. Once the diagnosis of open globe is made, immediate referral for surgical exploration and repair should be made to the eye specialist. The eye should be protected with a fox metal eye shield while awaiting definitive treatment. Baseline exam findings and visual acuity are important in advising patients and family members on the prognosis and final visual outcomes.

Findings supporting a favorable outcome include a normal lens at presentation and an anterior segment location of intraocular foreign body. However, more discouraging findings for final visual outcome are afferent pupillary defect, visual acuity of light perception or, worse, prolapse of uveal tissue and foreign bodies posterior to the lens (Ehlers, 2008). If there is a poor view of the fundus, one should consider B-scan ultrasonography to examine integrity of posterior tissues. Orbital radiographs or computed tomography (CT) scanning should be done if a foreign body may be present. Magnetic Resonance Imaging (MRI) is contraindicated in cases involving a suspected metallic foreign body. If a metallic intraocular foreign body is present, its prompt removal has been shown to be important in attaining the best visual outcome possible (Soheilian et al., 2004). Antibiotics are generally started postoperatively in traumatic cases with open globes. Subconjunctival injections of vancomycin, ceftazidime or gentamycin, and dexamethasone postoperatively are recommended. Recommended topical antimicrobial therapy includes fourth generation fluoroquinolones, such as moxifloxacin and gatifloxacin, alternatively, fortified vancomycin and ceftazidime.

The patient was discharged from the hospital on day three with a clinic visit scheduled for the following days. The following day vision in the right eye remained at light perception with complain of pain and watering (Fig. 8) So, a gentle ultrasonography of the right eye was done which revealed multiple dense membranes in the vitreous cavity suggestive of endophthalmitis. (Fig. 9) So, the patient was referred to Vitreoretinal surgeon for further management.

Inflammation is managed with 1% prednisolone acetate ophthalmic solution. Cycloplegic agents, such as 1% atropine, twice daily will help in maintaining the depth of the anterior chamber and may enhance patients' comfort while facilitating the examination of the fundus. Broad spectrum intravenous antibiotics, like vancomycin, ceftazidime or fluoroquinolone, are commonly given preoperatively and discontinued after four to seven days (Kaiser et al., 2004). The intravitreal injection of antibiotics has been shown to be an effective method of reducing the risk of post-traumatic endophthalmitis, a devastating intraocular infection (Soheilian et al.). The risk of endophthalmitis is increased in cases of ruptured globe injuries with or without retained intraocular foreign body.

The most common organisms in post-traumatic endophthalmitis include *Staphylococcus epidermidis* and *Bacillus* species. The Seidel test confirms or rules out cases of full thickness injuries to the anterior segment. Partial thickness corneal lacerations require topical broad-spectrum antibiotic coverage and a cycloplegic agent for relief of photophobia and pain associated with ciliary spasm. A bandage contact lens may also be helpful for structural or tectonic support. Full thickness corneal lacerations, require surgical exploration and repair with postoperative administration of antibiotic and steroids. Thus, in all cases of penetrating ocular injury, close daily follow-up is required to monitor progress and identify any sign of complications. The patient with severe penetrating injuries should be followed closely for potential complications like endophthalmitis, recurrence of hyphema, ocular siderosis, and sympathetic ophthalmia (Newman, 1998).

### Classifying Ocular Injury

Eye injury can be anatomically classified into anterior segment, posterior segment, adnexal, and orbital trauma. Ocular trauma can be described as penetrating or perforating. In a penetrating injury only one surface of an ocular structure is damaged (i.e. an entrance wound without an exit wound). Perforating injuries are defined as "double penetrating" injuries, creating both entry and exit wounds.<sup>10</sup> Blunt trauma can result in hematoma and contusion of periocular structures and globe ruptures. A rupture is a full thickness injury of the tissue that makes up the external boundaries of the globe. Ocular structures that are vulnerable to rupture injury include the limbus, areas of scleral thinning just posterior to rectus muscle insertions, and previous surgical incision sites. The Ocular Trauma Classification Group provides a classification scheme for mechanical ocular trauma based upon the type and mechanism of injury, grade of injury based on visual acuity at presentation, and absence or presence of an afferent pupillary defect (Rowe; Pieramici).

### Management

A thorough history will help identify and detail the cause of injury. The history should include when, where, and how the injury occurred in the patient's own words. The reporting and documentation of the history and physical exam often have medicolegal consequences, as many are work-related or a result of assault. The physician should inquire into any previous treatments for the current injury and the events occurring from the time of injury until the time of presentation. Past medical history including eye injuries, ocular surgeries, or history of amblyopia, medications, allergies, family history, social history, and date of last tetanus vaccination complete the highlights of the eye injury history.

The examination should start with an assessment of visual acuity. Counting fingers, hand movement, light perception, or no light perception should be documented, if the patient is unable to read the largest line on the visual acuity chart. The examination of the eye should be comprehensive and must follow a logical sequence. A common practice among eye specialists is to examine the eye from the external and anterior structures to those more posterior. Examination of the traumatized eye thus begins with examination of the external structures and bony orbit. Palpation of the orbital rim detects fractures and or crepitus. The eyelids are evaluated for laceration, noting any involvement of the lid margins or lacrimal system. Examination of the pupils for their shape, size, symmetry, direct, and consensual responses to light should be noted. The pupillary exam is especially important in cases where intracranial injury is possible. The pupils should not be pharmacologically dilated until mental status has been assessed and neurologic status deemed stable. Evaluation of the extraocular muscle function in all directions of gaze may identify a restriction of gaze attributable to muscle entrapment within an orbital fracture or traumatic cranial nerve injury.

Slit lamp examination of the globe allows classification of conjunctival hyperemia, subconjunctival hemorrhage, hyphema, corneal opacities and edema, foreign bodies, traumatic iris tears, and lens location and stability. Fluorescein strips can be used to delineate corneal abrasions and to detect any active aqueous leakage from the anterior chamber using the Seidel test. Intraocular pressure should be measured in all cases of ocular trauma, except those with an obvious open-globe injury, in which case manipulation of the globe should be minimized until evaluation and surgical repair is considered by an ophthalmologist. Dilated fundus exam provides a view of the retina, macula, optic disc, and ocular vasculature. The red reflex is evaluated for brightness, shape, and symmetry between the two eyes. The ocular media is then checked for opacities, foreign body, or hemorrhage. Finally, the retina is evaluated for signs of choroidal rupture, commotio retinae, subretinal hemorrhage, and traumatic retinal tears and detachments. Depending on the type of injury, various forms of imaging modalities may be pursued. Radiographs, ultrasonography, CT, or MRI may be ordered. MRI is always contraindicated when a metallic foreign body is suspected. If perforating injury is suspected, imaging should be performed, both eyes patched, and immediate ophthalmology referral made for further evaluation and probable surgical repair.

### Conclusion

While surgical treatment modalities continue to improve, the most effective approach to ocular trauma is a proactive approach to prevention. Primary prevention of ocular injury is firmly based in improving patient education, proper safety equipment and practices, risk reduction, and close supervision of all high-risk activities. Prevention of ocular trauma, like all types of trauma, remains an ongoing battle.

### REFERENCES

- Dannenberg, AL., Parver, LM., Brechner, RJ., Khoo, L. Penetration eye injuries in the workplace. The National Eye Trauma System Registry. *Arch Ophthalmol* 110: 843-848.
- Dannenberg, AL., Parver, LM., Fowler, CJ. Penetrating eye injuries related to assault. The National Eye Trauma System Registry. *Arch Ophthalmol* 110: 849-852.

- DeJuan, E., Sterneberg, P., Michels. RG. 1983 Penetrating ocular injuries. Types of injuries and visual results. *Ophthalmology* 1983; 90:1318-22.
- Ehlers, JP., Kunimoto, DY., Ittoop, S. et al. 2008. Metallic Intraocular Foreign Bodies: Characteristics, Interventions, and Prognostic Factors for Visual Outcome and Globe Survival. *Am J Ophthalmol.* Jul 7.
- Forsyth. Blunt Trauma. Washington State Department of Health Presentation. [www.doh.wa.gov/hsqa/emstrauma/OTEP/blunttrauma.ppt](http://www.doh.wa.gov/hsqa/emstrauma/OTEP/blunttrauma.ppt). Accessed 8/30/08.
- Kaiser, P., Freidman, N., Pineda. R. 2004. The Massachusetts Eye and Ear Infirmary Illustrated Manual of Ophthalmology, 2nd Edition. Saunders, Philadelphia PA. 112-13 and 152-153.
- Newman TL, Russo PA. Ocular sequelae of BB injuries to the eye and surrounding adnexa. *J Am Optom Assoc.* 1998 Sep;69(9):583-90.
- Pieramici, DJ., Sternberg, JP., Aaberg, TM et al. The Ocular Trauma Classification Group. A system for classifying mechanical injuries of the eye (globe). *American Journal of Ophthalmology.*
- Rowe, J. and Kosoko-Lasaki. O Review of ocular trauma. *Archives of Ibadan Medicine*, Vol 7, 1: 47-50.
- Scribano, PV., Nance, M., Reilly, P. et al. 1997. Paediatric nonpowder firearm injuries: Outcomes in an urban paediatric setting. *Paediatrics* 100:E5.
- Soheilian, M., Abolhasani, A., Ahmadi, H. et al. 2004. Management of magnetic intravitreal foreign bodies in 71 eyes. *Ophthalmic Surg Lasers Imaging.* Sep-Oct;35(5):372-8.
- Soheilian, M., Rafati, N., Mohebbi, M. et al. Prophylaxis of Acute Posttraumatic Bacterial Endophthalmitis: A Multicenter, Randomized Clinical Trial of Intraocular Antibiotic Injection, Report 2. *Arch Ophthalmol* 125: 460-465.
- Takvam, JV., Midelfort. A 1993. Survey of eye injuries in Norwegian children. *Acta Ophthalmol (Copenh)*; 71:500-5.
- Wong, T., Dlein, BE., Klein. R. The prevalence and 5-year incidence of ocular trauma. The Beaver Dam Eye Study. *Ophthalmology* 107(12): 2196-202.

\*\*\*\*\*