



ISSN: 0975-833X

Available online at <http://www.journalcra.com>

International Journal of Current Research
Vol. 9, Issue, 12, pp.62638-62642, December, 2017

INTERNATIONAL JOURNAL
OF CURRENT RESEARCH

CASE REPORT

PRESURGICAL ORTHOPEDICS IN CLEFT LIP AND PALATE

Dr. Sharath Kumar Shetty, Dr. Vijayanda Kumar, M., *Dr. Ershad Haris and
Dr. Mahesh Kumar, M.

KVG Dental College, India

ARTICLE INFO

Article History:

Received 15th September, 2017
Received in revised form
18th October, 2017
Accepted 24th November, 2017
Published online 27th December, 2017

Key words:

Presurgical
Orthopedics.

ABSTRACT

Child with this anomaly not only suffers for poor dental development but also deprived from breast feeding due to improper oral seal, swallowing and nasal regurgitation, other associated problems are hearing difficulties due to abnormalities in the palatal musculature, and speech difficulties due to nasal escape and articulation problems. The principle objective of presurgical orthodontics is to reduce the severity of the initial cleft deformity easy breast feeding, swallowing and nasal regulation. Despite the differing opinions about the long-term success of NAM, the immediate success of the therapy facilitates cleft surgery immensely. Although lip closure can always be achieved surgically regardless of the cleft width, preoperative narrowing of the lip and alveolar segments, nasal shaping and columella lengthening help to reduce tissue tension and therefore improve surgical outcome by minimizing wound healing disturbances and scarring. For treatment success, a high compliance and active participation of the patient's parents is however indispensable.

Copyright © 2017, Dr. Sharath Kumar Shetty et al. This is an open access article distributed under the Creative Commons Attribution License, which permits unrestricted use, distribution, and reproduction in any medium, provided the original work is properly cited.

Citation: Dr. Sharath Kumar Shetty, Dr. Vijayanda Kumar, M., Dr. Ershad Haris and Dr. Mahesh Kumar, M. 2017. "Presurgical orthopedics in cleft lip and palate", *International Journal of Current Research*, 9, (12), 62638-62642.

INTRODUCTION

Child with this anomaly not only suffers for poor dental development but also deprived from breast feeding due to improper oral seal (Papadopoulos, 2005), swallowing and nasal regurgitation, other associated problems are hearing difficulties due to abnormalities in the palatal musculature, and speech difficulties due to nasal escape and articulation problems (Haug *et al.*, 2012). The principle objective of presurgical orthodontics is to reduce the severity of the initial cleft deformity easy breast feeding, swallowing and nasal regulation. This enables the surgeon and the patient to enjoy the benefits associated with repair of cleft deformity that is of minimal severity.

History

To address the issues of wide cleft surgery, several non-surgical techniques to minimize the surgical repair have been attempted for many decades. In 1686 Hoffman described the use of a head cap with arms extended to the face to retract the premaxilla and narrow the cleft (Grayson, 2004). Now there is many modification to this method of using the head as extraoral anchorage, (Millard, 1977), and it is used today to retract the maxilla (Berkowitz, 1996).

Intra oral presurgical orthopedic techniques have also changed significantly when compared with those described by early proponents of the technique.^{7,8} The most well known appliance was designed by Georgiade and Latham in 1975. This device expanded collapsed lateral segments while actively retracting the premaxilla in bilateral cleft lip and palate infants⁹ In response to controversy associated with active retraction of the premaxilla, Hotz described the use of a passive orthopedic plate to slowly align the cleft segments.¹⁰ All of these appliances were designed to correct the alveolar cleft only, despite the fact that the cleft nasal deformity remains the greatest esthetic challenge (Grayson, 2004). Grayson and Cutting were among the first to combine the concepts of presurgical orthopedics and preoperative treatment of cleft lip nasal deformity. They developed the concept of naso alveola molding, which combined a nasal molding stent with a passive, presurgical molding appliance in treating infants with cleft lip and palate (Grayson, 1999) active molding and repositioning of the nasal cartilages take advantage of the plasticity of the cartilage in the newborn infant. The objectives of the treatment include the active molding and repositioning of the deformed nasal cartilages and alveolar processes, as well as the lengthening of the deficient columella (Grayson, 1999). Therefore nasoalveolar molding is defined as the nonsurgical, passive method of bringing the alveolus and lip together by redirecting the forces of natural growth. It also allows for correction of the flattened nose before

*Corresponding author: Ershad Haris,
KVG Dental College, India.

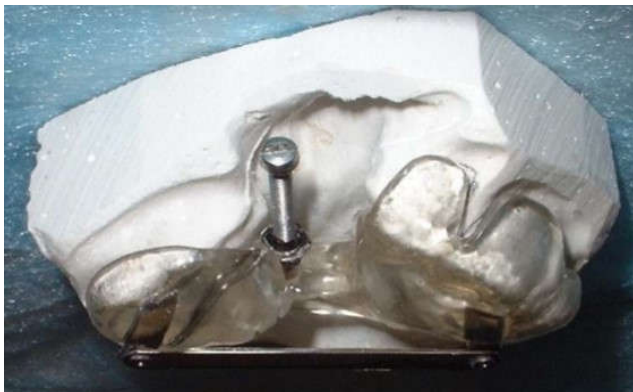surgery and facilitates nose repair at the time of lip repair (Yang, 2003).

Pre-Procedure Planning

Children with cleft deformities require a multidisciplinary approach to reconstruction. A team approach to treatment is the standard of care. Close cooperation of the surgeon with the orthodontist is necessary to achieve desirable outcomes with presurgical orthopedic therapy.

Latham appliance

The Latham appliance was popular for expanding and aligning the maxillary segments of the patient with a cleft palate (Georgiade, 1975). It is a pin-retained device that is inserted into the palate with acrylic extensions onto the alveolar ridges. A screw mechanism is then used to manipulate the segments as desired. The Latham appliance is a surgically placed fixed active intraoral device to expand the maxillary segments and retract a displaced premaxilla without external strapping.¹⁴ It consists of 2 hard acrylic caps covering the palatal processes joined with a midline screw and an acrylic labial cap covering the premaxillary fragment. Retraction of the premaxilla is achieved with power chain. (Figure 2) The parents have to activate the screw on a regular base. The decrease in the overall length of the palate and retraction of the premaxillary segment facilitated definitive cleft repair (Georgiade, 1975).



Advantages

- Inter-canine width and intertuberosity width increases (Latham, 1976)
- The palatal length and intercanine arch length decreases (Millard, 1990).

Disadvantages

- Additional costs associated with use of an operating wing and surgeon
- Bony fixation with screws or pins could interfere with the developing teeth and the midfacial growth
- Requires general anaesthetics for application of the device (Georgiade, 1975).
- For every millimetre decrease in distance achieved, there is an increase in deviation of 4° of the premaxillary segments relative to the vomer (Latham, 1976).
- Patient and parental compliance is not assured (Millard, 1990).

In long-term study, more anterior open bites and posterior crossbites were found in unilateral and bilateral cases compared to non-orthopedics and periosteoplasty group (Chan, 2003). In the study of Chan *et al.*, in which they evaluated active appliances longitudinally, dental models of patients with unilateral cleft lip and palate (UCLP) were assessed using the Goslon Yardstick. GPP and lip adhesion were performed both in non-orthopedic and in orthopedic groups. No significant differences were found in Goslon scores between the two groups. The authors concluded that Latham procedures did not affect dental arch relations in preadolescent children with UCLP (Allareddy, 2014). Similarly, Allareddy *et al.* stated that, outcomes are predictable without any major adverse events or complications by using Latham device (Romero, 2003). Besides, it was stated that Latham device could be useful in unusual cleft cases (Dürwald, 2007). McNeil Method: McNeil was the first in aligning presurgically the alveolar parts in cleft lip and palate patients (Allareddy, 2014) He suggested the use of serial appliances to approximate cleft alveolar segments. By molding the palatal segments into the correct position using a series of acrylic plates, McNeil believed that this would produce a normal maxilla, while reducing the alveolar and palatal cleft at the same time. McNeil and Burston claimed that soft tissues overlying the hard palate were stimulated to grow, and they also added that neonatal maxillary orthopedics could control and modify the postnatal development of the maxilla (McNeil, 1950). In addition, the use of a series of acrylic plates may be favorable for patients who have to travel long distances and are unable to visit the orthodontics clinic weekly. Another advantage may be foreseeing the final position of the alignment arches.

Nasoalveolar molding for infants born with clefts objectives

The principle objective of presurgical NAM is to reduce the severity of the initial cleft deformity. This enables the surgeon to enjoy the benefits associated with repair of an infant that presents with a minimal cleft deformity. These goals include lip segments that are almost in contact at rest, symmetrical lower lateral alar cartilages, and adequate nasal mucosal lining, which permits postsurgical retention of the projected nasal tip (Grayson, 1999). Additional objectives of NAM include reduction in the width of the alveolar cleft segments until passive contact of the gingival tissues is achieved. As reduction of the alveolar gap width is accomplished, the base of the nose and lip segments achieves improved alignment. Tapes that actively bring the lip segments together are used in conjunction with the molding plate and nasal stent. Taping the lips together helps to upright the inclined columella along the midsagittal plane. As reduction of the alveolar gap width is accomplished, the base of the nose and lip segments achieves improved alignment. As the alveolar ridges and lower maxilla improve in relation to each other, the overlying soft tissues improve. The alar rim, which was initially stretched over a wide alveolar cleft deformity, shows some laxity, which enables it to be elevated into a symmetrical and convex form. The nasal tip on the cleft side is over-corrected in its forward projection. This is achieved through the use of a nasal stent, an intraoral molding plate, and surgical tape. In the infant with bilateral clefts of the lip alveolus and palate, the objective of

presurgical NAM includes the nonsurgical elongation of the columella, centering of the premaxilla along the midsagittal plane, and retraction of the premaxilla in a slow and gentle process to achieve continuity with the posterior alveolar cleft segments. Additional objectives include a reduction in Width of nasal tip, improved nasal tip projection and a decrease in the nasal alar base width (Grayson, 1999).

Procedure

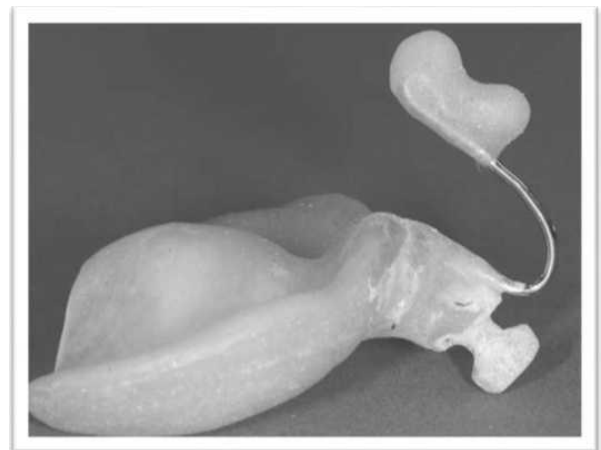
According to descriptions by Grayson¹ (history refence) the procedure is started as soon after birth as possible in order to take advantage of the plasticity of the cartilage.

Impression technique: Initial impression of the cleft lip and palate infant is obtained within the first week of birth. A heavy-bodied silicone impression material is used to take the initial impression. The impression can be taken in a clinical setting that is prepared to handle airway emergency, if at all encountered. A surgeon is always present during the impression process. The infant is held upside down by the surgeon and the impression tray is inserted into the oral cavity. The infant is held in an inverted position to prevent the tongue from falling back and to allow fluids to drain out of the oral cavity. The tray is seated until the impression material adequately covers the anatomy of the upper gum pads. Once the impression material is set, the tray is removed, and the mouth is examined for residual impression material. The impression is then poured with dental stone to obtain an accurate cast.

It is made of hard clear acrylic and is lined with a thin layer of soft denture material. Parents are instructed to keep the plate in full time and to take it out for cleaning as needed, at least once a day. The appliance is secured extra-orally to the cheeks and bilaterally by surgical tapes, which have an orthodontic elastic band at one end. The elastics loop over a retention arm extending from the anterior flange of the plate. The retention arm is positioned approximately 40° down from the horizontal to achieve proper activation and to prevent unseating of the appliance from the palate. The tapes are changed once a day. Weekly visits are required to modify the molding plate to guide the alveolar cleft segments into the desired position. Closure of the alveolar gap brings the lip segments together, reduces the nasal base width, and introduces laxity of the alar rim. In the unilateral cleft, only one retention arm is used. To determine its location on the labial border of the molding plate, the cleft lip segments are pulled together while centering the philtrum and columella. A pencil mark is placed at the junction of the cleft lip segments, and the retention arm is attached at this point. The vertical position of the retention arm should be at the junction of upper and lower lips at rest. This allows for approximation of the cleft lip segments and does not interfere with the resting position of the lower lip. When the retention arms are engaged by the tape elastic system, the elastics (inner diameter 0.25 inch, wall thickness—heavy) should be stretched approximately two times the resting diameter for proper activation force (2 oz). The amount of force may vary depending on the clinical objective and the mucosal tolerance to pressure. Retraction of the premaxilla requires greater elastic traction force than is required for closure of a unilateral alveolar gap. When the cleft alveolus is reduced to 5 mm or less, the nasal stent is added. The stent is made of 0.036-gauge round stainless

steel wire and takes the shape of a “swan neck” In the patient with bilateral clefts, there is a need for two retention arms and nasal stents. Each nasal stent originates from the molding plate at the base of a retention arm. After the nasal stents are added, attention is focused on nonsurgical lengthening of the columella. To achieve this objective, a horizontal band of soft denture material is added to join the left and right lower lobes of the nasal stents, spanning the base of the columella.

This band sits at the nasolabial junction and defines this angle as the nasal tip continues to be lifted and projected forward. Tape is adhered to the prolabium underneath the horizontal lip tape and stretches downward to engage the retention arms with elastics. This vertical pull is a counter-stretch to the upward force applied to the nasal tip by the nasal stent. Taping downward on the prolabium helps to lengthen the columella and vertically lengthens the often small prolabium. The horizontal lip tape is added after the vertical prolabial tape is in place. Primary surgical closure of the lip and nose is performed from 3 to 5 months of age. Because the alveolar segments are in approximation, a gingivoperiosteoplasty is simple for the surgeon to perform, avoiding extensive dissection and not affecting growth of the midface. The surgical technique for primary cleft lip and nose repair must be modified in a way that takes advantage of the NAM preparation.



Nasal stent added to the intraoral molding plate

Indication (Grayson, 1999; Grayson, 2001 and Grayson, 2004)

- Unilateral or bilateral cleft lip with or without Nasal deformity and asymmetry
- Short and/or deviated columella
- Alveolar segments malposition
- Neonatal cleft patients
- Co-operative parents or caregivers

Contraindication (Rattanayatikul, 2001 and van der Heijden, 2013)

- Sick or unwell baby
- Position of lip and alveolar ridge is in close to normal position –
- Patient cannot adapt to NAM appliance –
- Non-cooperative parents and caregivers –

- Long distance with costs for parents to bring child to clinic –
- Non-availability of specialist services for preparing for and making the NAM appliance
- The disadvantages include - The appliance is complex - Time consuming - Expensive - Burden on the parents and caregivers

Complication

There are few serious complications associated with NAM. The most common is irritation of the oral mucosal or gingival tissue. Intraoral tissues may ulcerate from pressure or rubbing. Common areas of breakdown are the frenum attachments, the anterior premaxilla, or the posterior fauces as the molding plate is retracted. The infant should be checked at each visit, and the molding plate should be properly relieved in all areas that are exerting excessive pressure. The intranasal lining of the nasal tip can become inflamed if too much force is applied by the upper lobe of the nasal stent. Notching along the alar rim can occur if the lower lobe is not positioned or shaped correctly. The area under the horizontal prolabium band can become ulcerated if the band is too tight (Rattanayatikul, 2001 and van der Heijden, 2013). The most common area of soft tissue irritation is the cheeks. The tapes should be removed slowly and carefully to avoid skin irritation.

Tape removal solvents or warm water can facilitate the removal of tapes. If the tissue remains irritated, a skin barrier such as Tegaderm can be used as a base on which the tape-elastic retraction system can be attached. It is sometimes recommended that aloe vera gel be applied to the cheeks when changing tapes. Poor compliance by the parents can cause loss of valuable treatment time. There is the risk that the molding plate will become dislodged and obstruct the airway. Taping the arms too horizontally or with inadequate activation increases the possibility that the posterior border of the molding plate will drop down onto the tongue. There is only one reported incidence in which this happened, causing a temporary airway obstruction. We place a 5-mm diameter hole in the center of the molding plate at fabrication to provide for passage of air in the event that the molding plate drops down from the rear and causes obstruction. The hole, centrally located on the palatal portion of the molding plate, will in most instances allow adequate airflow.

Benefits

NAM has proved to be an efficient method for reducing cleft width and improving nasal shape and symmetry in uni- and bilateral clefts. Various cleft types and manifestations react differently to the therapy. Digitalization of plaster models for treatment observation and scientific evaluation seem to be an accurate way of documentation. Despite the differing opinions about the long-term success of NAM, the immediate success of the therapy facilitates cleft surgery immensely. Although lip closure can always be achieved surgically regardless of the cleft width, preoperative narrowing of the lip and alveolar segments, nasal shaping and columella lengthening help to reduce tissue tension and therefore improve surgical outcome by minimizing wound healing disturbances and scarring. For treatment success, a

high compliance and active participation of the patient's parents is however indispensable (Rau, 2015).

NAM has evolved over the past decade into its present form through contributions made by practicing clinicians and parents. This method of treatment requires attention to detail with appliance adjustments that are at times less than a millimeter in dimension. Clinical skills in NAM develop over time. Efficiency in treating patients increases as these clinical skills improve, and these skills may be advanced by the training of a dental assistant or laboratory technician to make adjustments to the molding plate under direct supervision of the practicing clinician. Since the initiation of NAM and the associated surgical technique, there has been a significant difference in the outcome of primary surgical cleft repair.

Conclusion

Despite the fact that PSO treatments were popularized >60 years ago, the evidence related to this topic is still weak and inconclusive, mainly due to difficulty of study design and data collection. All of this happens in a growing patient over a 20-year period. Several large case control studies have demonstrated adverse outcomes in protocols using active presurgical orthopedic therapy. Henkeland and Gundlach reported that the Latham-Millard active orthopedic device had an adverse effect on facial growth (Berkowitz, 2004), Berkowitz reported worsened occlusal outcomes in the patients treated with the Latham-Millard device (Matic, 2008). Matic and Power found maxillary growth to be decreased after active presurgical orthopedic therapy in unilateral and bilateral clefts, respectively (Matic, 2008 and Matic, 2008). But NAM has proved to be an efficient method for reducing cleft width and improving nasal shape and symmetry in uni- and bilateral clefts. Various cleft types and manifestations react differently to the therapy. Digitalization of plaster models for treatment observation and scientific evaluation seem to be an accurate way of documentation. Despite the differing opinions about the long-term success of NAM, the immediate success of the therapy facilitates cleft surgery immensely. Although lip closure can always be achieved surgically regardless of the cleft width, preoperative narrowing of the lip and alveolar segments, nasal shaping and columella lengthening help to reduce tissue tension and therefore improve surgical outcome by minimizing wound healing disturbances and scarring. For treatment success, a high compliance and active participation of the patient's parents is however indispensable (Rau, 2017).

REFERENCES

- Allareddy, V., Ross, E., Bruun, R., Lee, M.K., Shusterman, S. 2014. Operative and Immediate Postoperative Outcomes of Using a Latham-Type Dentomaxillary Appliance in Patients With Unilateral Complete Cleft Lip and Palate. *Cleft Palate Craniofac J*
- Berkowitz, S. 1996. A comparison of treatment results in completebilateral cleft lip and palate using a conservative approach versus Millard-Latham PSOT procedure, *Semin Orthod* 2:169.
- Berkowitz, S., Mejia, M., Bystrik, A. 2004. A comparison of the effects of the Latham-Millard procedure with those of a conservative treatment approach for dental occlusion and facial aesthetics in unilateral and bilateral complete cleft lip

- and palate: part I. Dental occlusion. *Plast Reconstr Surg.* Jan. 113(1):1-18. [Medline].
- Chan, K.T., Hayes, C., Shusterman, S., Mulliken, J.B., Will, L.A. 2003. The effects of active infant orthopedics on occlusal relationships in unilateral complete cleft lip and palate. *Cleft Palate Craniofac J* 40: 511-517.
- Dürwald, J., Dannhauer, K.H. 2007. Vertical development of the cleft segments in infants with bilateral cleft lip and palate: effect of dentofacial orthopedic and surgical treatment on maxillary morphology from birth to the age of 11 months. *J Orofac Orthop* 68: 183-197. 35
- Georgiade, N., Latham, R. 1975. Maxillary arch alignment in the bilateral cleft lip and palate infant, using pinned coaxial screw appliance, *Plast Reconstr Surg* 56:52.
- Georgiade, N.G., Latham, R.A. 1975. Maxillary arch alignment in the bilateral cleft lip and palate infant, using pinned coaxial screw appliance. *Plast Reconstr Surg* 56: 52-60.
- Grayson, B.H., Cutting, C.B. 2001. Presurgical nasoalveolar orthopedic molding in primary correction of the nose, lip, and alveolus of infants born with unilateral and bilateral clefts. *Cleft Palate Craniofac J.* 38: 193-8.
- Grayson, B.H., Maull, D. 2004. Nasoalveolar molding for infants born with clefts of the lip, alveolus, and palate, *Clin Plast Surg* 31:148.
- Grayson, B.H., Maull, D. 2004. Nasoalveolar molding for infants born with clefts of the lip, alveolus, and palate. *Clin Plast Surg.*, 31: 149-58.
- Grayson, B.H., Santiago, P.E., Brecht, L.E., Cutting, C.B. 1999. Presurgical nasoalveolar molding in infants with cleft lip and palate, *CleftPalate Craniofac J* 36:486.
- Grayson, B.H., Santiago, P.E., Brecht, L.E., Cutting, C.B. 1999. Presurgical nasoalveolar molding in infants with cleft lip and palate. *Cleft Palate Craniofac J* 36: 486-498.
- Grayson, B.H., Santiago, P.E., Brecht, L.E., Cutting, C.B. 1999. Presurgical nasoalveolar molding in infants with cleft lip and palate. *Cleft Palate Craniofac J.*, 36: 486-98.
- Hotz, M., Gnoinski, W. 1976. Comprehensive care of the cleft lip and palate children at Zurich University: a preliminary report, *Am J Orthod* 70:481.
- Hotz, M., Perko, M., Gnoinski, W. 1987. Early orthopaedic stabilization of the premaxilla in complete bilateral cleft lip and palate in combination with Celesnik lip repair, *Scand J Plast Reconstr Surg Hand Surg* 21:45.
- Latham, R.A., Kusy, R.P., Georgiade, N.G. 1976. An extraorally activated expansion appliance for cleft palate infants. *Cleft Palate J* 13: 253-261.
- Matic, D.B., Power, S.M. 2008. Evaluating the success of gingivoperiosteoplasty versus secondary bone grafting in patients with unilateral clefts. *Plast Reconstr Surg.* 2008 Apr. 121(4):1343-53; discussion 1368-9. [Medline].
- Matic, D.B., Power, S.M. 2008. The effects of gingivoperiosteoplasty following alveolar molding with a pin-retained Latham appliance versus secondary bone grafting on midfacial growth in patients with unilateral clefts. *Plast Reconstr Surg.*, Sep. 122(3):863-70; discussion 871-3. [Medline].
- McNeil, C. 1950. Orthodontic procedures in the treatment of congenital cleft palate, *Dent Rec (London)* 70:126.
- Millard, D. 1977. Cleft craft: the evolution of its surgery. Bilateral and rare deformities, Vol 2, Boston, Little, Brown.
- Millard, DR Jr, Latham, R.A. 1990. Improved primary surgical and dental treatment of clefts. *Plast Reconstr Surg* 86: 856-871.
- Papadopoulos, N.A. *et al.* Foetal surgery and cleft lip and palate. current status and new Perspectives. *British Journal of Plastic Surgery.* 2005;58:593-607
- Rattanayatikul, C., Godfrey, K. 2001. A Review of Presurgical Orthopedics for the Infants of Cleft Lip and Palate. *Srinagarind Med J.* 16:42-50.
- Rau, Andrea *et al.* "Nasoalveolar Molding in Cleft Care—Experience in 40 Patients from a Single Centre in Germany." Ed. James Cray. PLoS ONE 10.3 (2015): e0118103. PMC. Web. 26 Nov. 2017
- Romero, M., Latham, R., Romance, A., Salvan, R. 2003. Treatment of an infant with a rare cleft resolved with use of an orthopedic appliance. *Cleft Palate Craniofac J* 40: 642-644.
- van der Heijden, P., Dijkstra, P.U., Stellingsma, C., van der Laan, B.F., Korsten-Meijer, A.G., GoorhuisBrouwer, S.M. 2013. Limited evidence for the effect of presurgical nasoalveolar molding in unilateral cleft on nasal symmetry: a call for unified research. *Plast Reconstr Surg*, 131: 62e-71e.
- Yang, S., Stelnicki, E.J., Lee, M.N. 2003. Use of nasoalveolar molding appliance to direct growth in newborn patient with complete unilateral cleft lip and palate, *Ped Dent* 25:253,
