



ISSN: 0975-833X

## RESEARCH ARTICLE

### SUCCESSFUL THERAPEUTIC MANAGEMENT OF HEPATOGENOUS PHOTSENSITIZATION DUE TO LANTANA POISONING IN A SAHIWAL CALF

Sarma Kalyan, Borpujari Dhrubajyoti, Shah Nirali, Ahmed, F. A., Das, G., Behera, S. K., Saikia, B. and \*Talukdar Dibyajyoti

Teaching Veterinary Clinical Complex, College of Veterinary Sciences and Animal Husbandry, Central Agricultural University, Selesih, Aizawl, Mizoram, India

#### ARTICLE INFO

##### Article History:

Received 15<sup>th</sup> July, 2017

Received in revised form

07<sup>th</sup> August, 2017

Accepted 24<sup>th</sup> September, 2017

Published online 31<sup>st</sup> October, 2017

##### Key words:

Calf, Hepatogenous photosensitization, *Lantana camara*.

#### ABSTRACT

A one year old Sahiwal male calf was presented to the Teaching Veterinary Clinical Complex, College of Veterinary Sciences and Animal Husbandry, CAU, Mizoram with a history of accidentally consumption of *lantana camara* plant and showed the symptoms of dullness, depression, anorexia, lethargy, icteric mucous membrane and sluffing skin which was diagnosed as hepatogenous photosensitization. Haemato-biochemical analysis revealed anaemia, jaundice and hyperbilirubinemia. The animal was treated with Dextrose 5% with liver injection, antibiotic, antihistaminic and external antiseptic solution application for skin lesions. The duration of therapy for the complete clinical recovery was 30days.

Copyright©2017, Sarma Kalyan et al. This is an open access article distributed under the Creative Commons Attribution License, which permits unrestricted use, distribution, and reproduction in any medium, provided the original work is properly cited.

Citation: Sarma Kalyan, Borpujari Dhrubajyoti, Shah Nirali, Ahmed, F. A., Das, G., Behera, S. K., Saikia, B. and Talukdar Dibyajyoti, 2017. "Successful therapeutic management of hepatogenous photosensitization due to lantana poisoning in a sahiwal calf", *International Journal of Current Research*, 9, (10), 59329-59331.

#### INTRODUCTION

Photosensitization, also known as cutaneous disease, is a serious skin disease which takes place when skin becomes sensitized to sunlight, particularly ultraviolet range of the spectrum, due to the presence of photo-dynamic agents in the skin sunburn (Andrews *et al.*, 2004) which is characterized by pale and icteric mucous membrane, hyperkeratosis that can result in dermatitis, hypoxia, weight loss, and eventually death of affected animals (Antonio *et al.*, 2010). It is primarily a condition of sheep, cattle and horses but other species may also be susceptible (Witte and Curry, 1993). Cattle are the most commonly affected species in the field (Pass, 1986).

**There are four forms of photosensitization:** Primary photosensitization (Type 1 photosensitization), congenital photosensitization (Type 2), hepatogenous photosensitization (Type 3) and photosensitization of uncertain etiology (Type 4) (Radostits *et al.*, 2007). Primary photosensitization occurs when a 'photodynamic' agent is ingested, injected or absorbed through the skin and cause photosensitization when the animal is exposed to ultraviolet light (Radostits *et al.*, 2007). Hepatogenous photosensitization (Type 3) occurs when liver is

unable to excrete phylloerythrin (Haargis and Ginn, 2007). This occurs due to any hepatic problem which interfere chlorophyll metabolism leading to accumulation of abnormal by-product that should be excreted in the bile (Haargis and Ginn, 2007). This form is most often as a result of ingestion of hepatotoxic plants such as *Lantana camara* (Amaravathi *et al.*, 2016)

#### History and clinical observations

A Sahiwal male calf aged 1 year was presented with the symptoms with signs of restlessness on exposure to sunlight and sheltering in the shade, anorexia, edematous swelling and sloughing of the skin of ears and extensive cutaneous lesions were observed on back, neck and other parts of the bodies (Fig.1). The distinct signs of icterus could be seen with yellowish discoloration of conjunctivae and hairless part of the skin. Animal had a history of consuming Lantana leaves 1 week back. Upon physical examination, the temperature, pulse and respiration (TPR) were within normal range. Skin scrapings examination revealed negative for mites, bacterial and fungal infection. Faecal sample was also found negative for parasitic ova. 10 ml blood was collected from the jugular vein and EDTA-preserved blood and serum sample were placed on ice and transported to the laboratory for a complete blood count and serum biochemical analysis within 4h of collection. Results of the complete blood count and serum biochemistry are shown in Table 1. Haemato-biochemical parameters indicated anemia,

\*Corresponding author: Talukdar Dibyajyoti,

Teaching Veterinary Clinical Complex, College of Veterinary Sciences and Animal Husbandry, Central Agricultural University, Selesih, Aizawl, Mizoram, India.

Table 1. Clinical pathology parameters for hepatogenic photosensitized calf

S.No.	Parameters	Before treatment (day0)	After treatment (day15)	Reference range*
1	Hb(gm/dl)	7.00	11.50	8-15
2	PCV (%)	23.00	41.00	24-46
3	TEC(millions/ $\mu$ l)	3.60	5.20	5-10
4	TLC (thousands/ $\mu$ l)	15.56	12.34	4-12
5	Nutrophil (%)	50.00	53.00	15-45
6	Lymphocyte (%)	43.00	45.00	45-75
7	Monocyte (%)	01.00	01.00	0-8
8	Eosinophil (%)	06.00	01.00	0-20
9	Total Protein (g/dl)	4.80	6.70	6-8
10	Albumin (g/dl)	2.10	3.45	2.4-3.5
11	Globulin (g/dl)	2.70	3.25	3.6-4.5
12	AST (IU/l)	321.00	108.00	58-100
13	Total bilirubin(mg/dl)	5.30	1.34	0.1-0.6
13	BUN (mg/dl)	34.00	32.00	6-22
14	Creatinine (mg/dl)	1.80	1.10	0.5-1.1

\* Clinical Pathology laboratory, Department of Veterinary Pathology, Iowa State University, Ames, IA

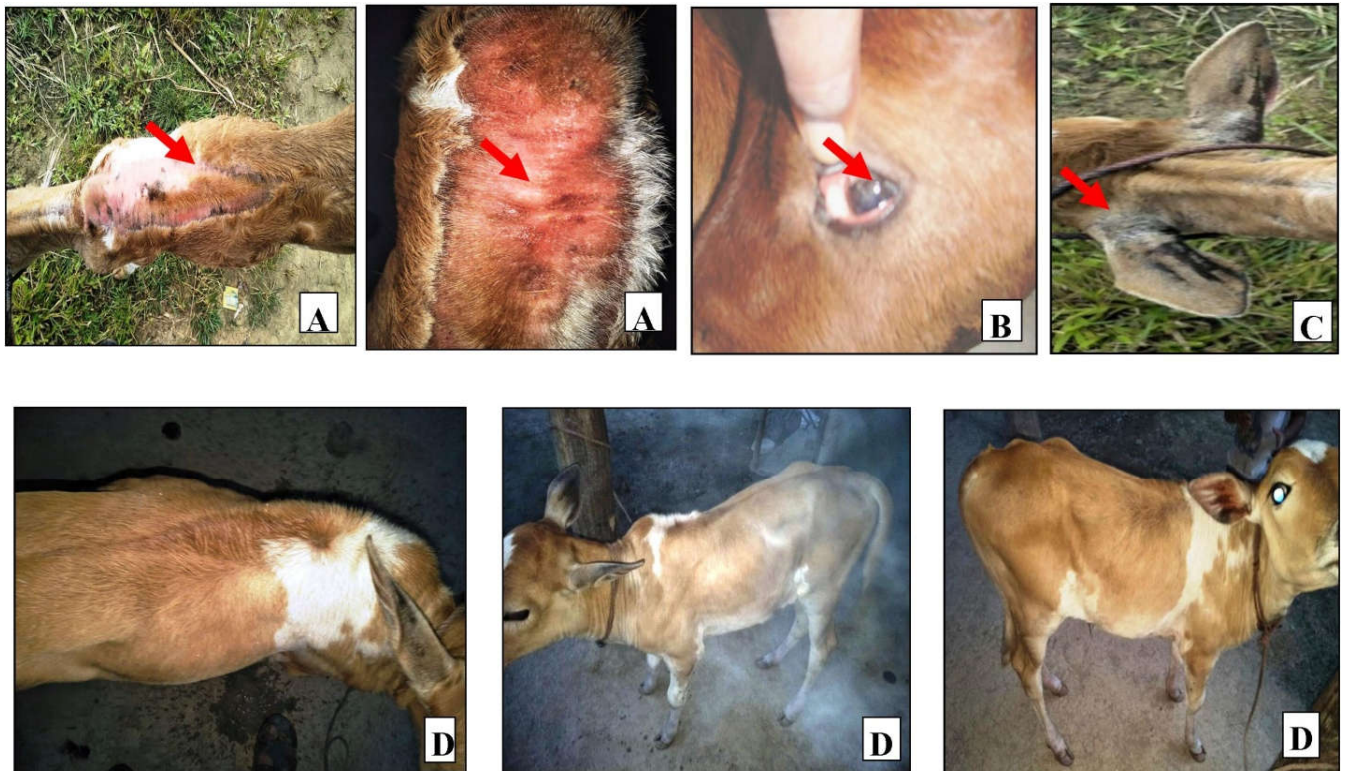


Fig. 1. Calf suffered from hepatic photosensitisation due to *Lantana camara* poisoning

- A. Sluffing of the Skin due to photosensitization
- B. Pale mucous membrane
- C. Hyperkeratinisation of the neck of the ear
- D. Improvement after Therapy

jaundice and hyperbilirubinemia and the AST level was higher than the reference range which indicated the involvement of liver problem.

#### Treatment

The animal was treated with 5% dextrose normal saline @ 300ml intravenously daily for 10days along with liver injection (Belamyl) @ 2ml intramuscularly every alternate day for 10days, antihistaminic (Avil) @ 2ml intramuscularly for 5 days, antibiotic (Intacef) @ 500mg intramuscularly for 5days and advised to external application of antiseptic (Betadine) solution for skin lesions regularly. The owner was advised not to allow the calf to graze in sunlight and to place in shade. After 2 week, the icteric condition improved, the mucous membrane became pink and calf was bright and alert. The skin

lesion of calf markedly improved where no signs of hyperkeratosis and necrotized skin lesions. Haemato-biochemical analysis revealed that all the parameters turned to normalcy (Table 1). At the end of the month the liver parameters back to normal and calf was doing well (Fig. 1). A diagnosis of hepatogenous photosensitization was made based on the nature and progression of clinical signs, elevated serum enzymes indicating hepatobiliary damage and response to therapy.

#### DISCUSSION

Hepatogenous photosensitization (HPS) is the most common form of photosensitization in ruminant (Wisloff *et al.*, 2002). Ingestion of lantana foliage by grazing animals causes intrahepatic cholestasis with liver damage. When Lantana is

consumed, phylloerythrin (photosensitizing agent), a catabolic product of chlorophyll, accumulated in the liver due to impaired excreted phylloerythrin capacity of liver (Haargis and Ginn, 2007) and cause hepatic injury and result to liver enzyme leakage (Cynthia, 2005). Damaged liver cannot properly metabolize phylloerythrin, which then accumulates in peripheral blood. Circulating phylloerythrin causes the photosensitization reaction in nonpigmented as well as pigmented skin (Haargis and Ginn, 2007). Cutaneous lesions cited for cattle include erythema, edema, fissuring, exudation, crust formation, alopecia, hypersalivation, skin necrosis and sloughing, secondary infection, and granulation (Amaravathi *et al.*, 2016). Anorexia, depression, recumbency, pruritus, and light avoidance are common behavioral changes. Generalized icterus is common with HPS, and discolored urine has been reported (Witte and Curry, 1993). The clinical signs observed in the present case were compatible with those previously described. Blood analysis revealed low haematological parameters viz Hb, PCV, TEC which also reported by Ali *et al.* (1995) whereas biochemical analysis revealed very high level of AST, serum bilirubin, BUN and creatinine at pre treatment estimation of the present case also reported by Sarma *et al.* (2015). The recommended treatment for hepatogenous photosensitization is removal of direct solar exposure along with correction of liver damage (Radostits *et al.*, 2007). It was effective for skin lesions disappear, and the appetite and body condition of the affected animals and returned to normal after 30 days as also observed in the present case. Symptoms of jaundice and photosensitization are seen within 1 week following consumption of *L. camara*. Similar findings were also observed in the present study.

## Conclusion

Successful outcome of the present case suggests that early intervention and treatment is important for better prognosis of the case.

## REFERENCES

Ali, M.K., Pramanik, A.K., Guha, C., Misra, S.K., Basak, D.K. 1995. Gross and histopathological changes in experimental *Lantana camara* poisoning in goats. *Indian Journal of Animal Health*, 34: 17–18.

- Amaravathi, M., Bharath, Kumar, Reddy, C. and Josthna Reddy, S. 2016. “Successful management of photosensitization due to lantana poisoning in a holstein friesian cow”, *International Journal of Current Research*, 8, (03): 27694-27695.
- Andrews, A.H., Blowey, R.W., Boyd, H. and Eddy, R.G. 2004. Photosensitization. *Bovine Medicine Diseases and Husbandry of Cattle*. 2 Edition. Pp 884-885.
- Antonio, H.H.M., Raimundo, A.B.J., Frederico, A.M.L.R., Rodrigo, N.F.F., Leonardo, F.R., Selwyn, A.H., and Enrico, L.O. 2010. Hepatogenous photosensitization associated with liver copper accumulation in buffalos. *Research in Vet Sci.*, 88: 519–522.
- Cynthia, K. M. 2005. Photosensitization. *Merck Veterinary Manual* 9th edition, 794-796.
- Haargis, A.M. and Ginn, P.E. 2007. The integument. In: McGavin, M.M., Zachary, J.F. (Eds.), *Pathologic Basis of Veterinary Disease*, fourth ed. Mosby/Elsevier, St.Louis, 1107–1261.
- Pass, M.A. 1986. Current ideas on the pathophysiology and treatment of lantana poisoning of ruminants. *Aust. Vet. J.*, 63: 169–171.
- Radostits, O.M., Gay, C.C., Hinchcliff, K.W., Constable, P. 2007. *Veterinary Medicine: A Textbook of the Diseases of Cattle, Horses, Pigs, Sheep and Goat*, 10th ed. W.B.Saunders, Oxford.
- Sarma, D.K., P.K. Boro, P. Hussain, P. Gogoi and M. Sharma, 2015. Efficacy of *Musa balbisiana* in hepato-biliary dysfunction affected with lantana camara poisoning in cattle. *Inter J Vet Sci.*, 4(4): 231-233
- Wisloff, H., Wilkins, A.L., Scheie, E., Flaoyen, A. 2002. Accumulation of Sapogenin Conjugates and Histological Changes in the Liver and Kidneys of Lambs Suffering from Alveld, a Hepatogenous Photosensitization Disease of Sheep Grazing *Narthecium ossifragum*. *V et. Res. Comm.*, 26: 381–396
- Witte, S.T. and Curry, S.L. 1993. Hepatogenous photosensitization in cattle fed a grass hay. *J. Vet. Diagn. Investig.* 5: 133–136.

\*\*\*\*\*