



RESEARCH ARTICLE

EARLY ECHOCARDIOGRAPHY DETECTION OF ASSOCIATED CONGENITAL CARDIAC ANOMALIES
IN ANORECTAL MALFORMATION PATIENTS AND ITS IMPACT ON PROGNOSIS

*¹Dr. Ahmed. S. Resheed, ²Bassim M. Salman, ³Salah A. AL-kubaisi and ⁴Mohammed S. Dawood

¹F.I.C.M Pediatric surgery, Department of Pediatric Surgery, Ministry of Health, Al-Anbar, Iraq

²F.I.C.M.S, C.A.B.P Pediatric echocardiography, Ministry of Health, Al-Anbar, Iraq

³Ministry of Health, Al-Anbar, Iraq

⁴Community Medicine, Ministry of Health, Al-Anbar, Iraq

ARTICLE INFO

Article History:

Received 22nd July, 2017

Received in revised form

14th August, 2017

Accepted 20th September, 2017

Published online 17th October, 2017

Key words:

Echocardiography,
Congenital,
Cardiac,
Anomalies,
Anorectal malformation,
Prognosis.

ABSTRACT

Background: Ano-rectal malformations is an abnormality of the ano-rectum at birth in which the infant born with abnormal rectal opening. Different types of ano-rectal malformations are present which occurs in 1/ 5000 live birth. Usually it's not lethal even with complex variants and their management, the association of serious renal or cardiac anomalies increasing the morbidity and mortality of ano-rectal malformation cases. Study were carried out to determine the congenital cardiac anomalies associated to patients born with ano-rectal malformation and its rate, type, impact on the outcome of surgical reconstruction and the utility of the preoperative echocardiography.

Methods: This prospective study was conducted between July 2007 and January 2016, including 67 cases born with ano-rectal malformations which were managed and the associated congenital cardiac anomalies were evaluated by preoperative Echocardiography. The cases with positive echocardiography findings were tabulated with the sex, congenital cardiac anomalies types, mortality and type of ano-rectal malformations, other associated anomalies, and the type of surgery performed.

Results: Sixty-seven patients born with ano-rectal malformation were referred to the pediatric surgery unit. Age of patients ranged from 18 -38 hours with a mean age 28 hours. According to the echocardiography, 17(25.3%) of patients had congenital cardiac anomalies. Atrial septal defect (7 cases) predominated followed by Ventricular septal defect (5 cases). In 12 patients (17.9%), the associated congenital cardiac anomalies were of a mild nature, and reconstruction of the ano-rectum went smoothly. Five patients (7.4%) had significant congenital cardiac anomalies and all of them were died.

Conclusion: Associated congenital cardiac anomalies are present in many patients with ano-rectal malformation. Prognosis of the ano-rectal malformations patients, mostly depend on severity of the associated anomalies than on ano-rectal malformations itself. Thorough systemic clinical and radiological examination must be done to detect any associated anomalies at an early presentation and should be managed as soon as possible to reduce the future morbidity and mortality. While most of the congenital cardiac anomalies associated with ano-rectal malformations was of the mild type and had no effect on their surgical reconstruction, some of these associated anomalies were serious and affected the prognosis. Preoperative echocardiography evaluation of all cases of ano-rectal malformations is important and mandatory to reduce the morbidity and mortality.

Copyright©2017, Ahmed Resheed et al. This is an open access article distributed under the Creative Commons Attribution License, which permits unrestricted use, distribution, and reproduction in any medium, provided the original work is properly cited.

Citation: Dr. Ahmed. S. Resheed, Bassim M. Salman, Salah A. AL-kubaisi and Mohammed S. Dawood, 2017. "Early Echocardiography Detection of Associated Congenital Cardiac Anomalies in Anorectal Malformation Patients and Its Impact on Prognosis", *International Journal of Current Research*, 9, (10), 58868-58871.

INTRODUCTION

Ano-rectal malformations are an abnormality in which the newborn present with abnormal anus and rectal opening (Javid et al., 1998). Ano-rectal malformations are of unknown etiology and occur in one to 5000 live births with significant variations in the prevalence between regions throughout the world. Ano-rectal malformations occur slightly more common in males (Murphy et al., 2006).

*Corresponding author: Dr. Ahmed. S. Resheed,
F.I.C.M Pediatric surgery, Department of Pediatric Surgery, Ministry of Health, Al-Anbar, Iraq.

Associated anomalies present with high frequency ranges from 40% to 70% in ano-rectal malformations patients. Although ano-rectal malformations are rarely fatal, some associated anomalies (renal, cardiac) can be serious and life threatening (Abadi et al., 2008; Stoll et al., 2007; Alford et al., 1977; B I nescu et al., 2013; Spouge and Baird, 1986). Thorough and perfect evaluation for such associated anomalies are highly indicated which mostly affect the morbidity and mortality of the ano-rectal malformation patients (Shaul and Harrison, 1997; Hassink et al., 1996). Urogenital associated anomalies are the commonest followed by spinal, extremities, and cardiovascular system anomalies (Nah et al., 2012). Cardiac

anomalies occur in 9-20% of the patients with ano-rectal malformations (Murphy *et al.*, 2006). The majority of associated cardiac lesions are corrected after repair of the ano-rectal malformations except the complex cases (Ashcraft *et al.*, 2006). Proper echocardiography evaluation is mandatory for the exact diagnosis of these lesions and to detect nature of these defects (Ratan *et al.*, 2004). Present study carried out to determine the congenital cardiac anomalies associated to patients born with ano-rectal malformation and its rate, type, impact on the outcome of surgical reconstruction, with the utility of the preoperative echocardiography.

MATERIALS AND METHODS

This prospective study was conducted between July 2007 and January 2016, including 67 cases born with ano-rectal malformation which were managed at the Pediatric Surgery Unit of the Babylon and AL-Ramadi Maternity and Pediatric Teaching Hospitals and the associated congenital cardiac anomalies were evaluated by preoperative Echocardiography. The cases with positive echocardiography findings were tabulated with the sex, congenital cardiac anomalies types, mortality and type of ano-rectal malformations, other associated anomalies, and the type of surgery performed.

RESULTS AND DISCUSSION

A total of 67 patients with various forms of ano-rectal malformations were diagnosed and managed, 35 males (52%) and 32 females (47.7%); all had echocardiography as routine preoperative evaluation. The rate of congenital cardiac anomalies among ano-rectal malformations patients was 17 (25.3%), that is ten males and seven females, with predominance of Atrial septal defect (7 cases) and Ventricular septal defect (5 cases) Table 1, [Figure 1].

Table 1. Congenital Cardiac Anomalies (CCA) Types & Sex Distribution

Associated CCA*	Sex	
	Male	Female
Atrial septal defect	4	3
Ventricular septal defect	3	2
Patent ductus arteriosus	2	1
Tricuspid regurgitation	0	1
Mitral regurgitation	0	1
Tetralogy of fallot	2	0
Transposition of great arteries	1	0
Tricuspid stenosis	0	1

*Some patients had more than one type of associated cardiac congenital anomalies.

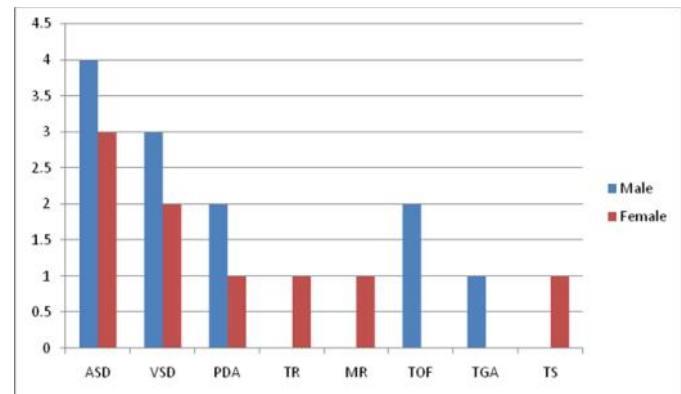


Figure 1. Associated congenital cardiac anomalies types and sex distribution

In 12 patients (17.9%), the associated congenital cardiac anomalies were of a mild nature and reconstruction of the ano-rectum went smoothly. Five patients (7.4%), had significant congenital cardiac anomalies and died (three postoperatively and two even before surgery) Table 2 and Table 3.

Table 2. Survived Patients with Positive Echo- findings & ARM procedure

	Type of ARM	Associated Anomalies	Echocardiography findings	Procedure
1	Rectourethral fistula	None	ASD,TOF,PDA	Staged PSARP
2	Rectourthral fistula	None	TOF	Staged PSARP
3	Rectal Artesia	Down's syndrome	ASD	Staged PSARP
4	Rectourethral fistula	Vesico-uretral reflux	ASD	Staged PSARP
5	Rectourethral fistula	None	VSD	Staged PSARP
6	Rectourethral fistula	Hemivertebra	VSD	Staged PSARP
7	Rectourethral fistula	None	ASD	Staged PSARP
8	Perineal fistula	None	PDA	Anoplasty
9	Rectovestibular fistula	None	MR	Staged PSARP
10	Rectovestibular fistula	None	ASD,TS	Staged PSARP
11	Perineal fistula	None	TR	Anoplasty
12	Perineal fistula	None	VSD	Anoplasty

ARM = Ano-rectal malformation, ASD =Atrial Septal Defect, VSD =Ventricular Septal Defect, TOF= tetralogy of fallot, PDA =Patent Ductus Arteriosus, MR =Mitral Regurgitation,TS=Tricuspid Stenosis, TR =Tricuspid Regurgitation, PSARP = Posterior Sagittal Anorectoplasty.

Table 3: Dead patients with positive echo- findings& ARM procedure

	Type of ARM	Echo findings	Associated anomalies	Timing of mortality
1	Persistent Cloaca	Cardiomegaly, large VSD,PDA,PS	None	Before surgery
2	High, no fistula	Large ASD	Esophageal Artesia and UDT.	After emergency colostomy
3	Perineal fistula	Large ASD	Bilateral Cleft Lip and Palate	After anoplasty
4	Rectovestibular fistula	Large VSD	Spina bifida	After emergency colostomy
5	Recto-urinary fistula	TGA	Congenital talpis equinovarus	Before surgery

ARM= Ano- rectal malformation, VSD=Ventricular Septal Defect, PDA= Patent ductus arteriosus, PS= Pulmonary stenosis, ASD= Atrial Septal Defect, TGA= Transposition of great arteries, UDT=Undescended testicle

Ano-rectal malformations and its associated anomalies can be repaired in single or in multiple stages starting from the neonatal period (Levitt and Peña, 2006) Perineal fistula and the covered anus as mild forms are usually done immediately in single stage, whereas the rest are managed in stages (Pena and Hong, 2000; Liu *et al.*, 2004). Neonates born with ano-rectal malformation are mainly affected by the associated anomalies particularly cardiac anomalies apart from gestational age, birth weight, duration of the procedure. Based on the severity and hemodynamic effect, preoperative medical or surgical management of the congenital cardiac anomalies may be needed (Kuroda *et al.*, 2011). In the five patients who died, surgical correction of the congenital cardiac anomalies was not possible in our hospital as pediatric cardiac surgery unit is not available. Three patients were on anti-failure medications but they could not tolerate the postoperative hemodynamic changes, while the other two patients with transposition of great arteries and large Ventricular septal defect died before surgery [Table 3]. Kamal *et al* from Saudi Arabia and Olgun *et al* from Turkey both reported the association between congenital cardiac anomalies and ano-rectal malformation in their studies as 24.6 % and 23.7% respectively (Kamal *et al.*, 2013; Olgun *et al.*, 2009). This is approximately similar to present study's result, that is, 25.3%. Chéhab *et al* in 2007 reported that Congenital anomalies of the gastrointestinal tract/abdominal wall are associated with congenital heart disease in 38% of the cases, with predominance of ventricular septal defect (VSD) (Chéhab *et al.*, 2007). While in present and Asslan *et al* studies (Saeed *et al.*, 2008), Atrial septal defect predominate followed by Ventricular septal defect Table [1], [Figure 1].

The majority of the associated congenital cardiac anomalies of a mild nature not giving rise to heart failure and their correction can be postponed after repair of the anal problem. Other anomalies are complex and may need some medications like prostaglandin as in cases with Patent ductus arteriosus lesions while the anal procedure is being done. Complex cardiac anomalies like transposition of the great arteries may need palliative procedures such as atrial septostomy to improve atrial blood mixing; this is one of the conditions where the cardiac lesion should be dealt with before the repair of ARMs (Ashcraft, 2006). Cardiovascular malformations are among the common associated anomalies which contribute significantly to the high mortality rate of patients with ano-rectal malformation (Merwe and Cox, 2017). In this study and according to the preoperative echocardiography, positive findings were seen in 17 cases. Whereas, twelve patients had mild congenital cardiac anomalies with insignificant hemodynamic effect and their ano-rectal malformation problems corrected similar to those without congenital cardiac anomalies, five cases had significant congenital cardiac anomalies, the first was male with Recto-urinary fistula had transposition of great arteries (TGA). The second, female with Persistent Cloaca had large Ventricular septal defect (VSD), both of them unfit for surgical interference and died before surgery. Three patients were died after surgical interference (colostomy, anoplasty) because of their unstable hemodynamic status Table 2 and Table 3.

Conclusion

Associated congenital cardiac anomalies are present in many patients with Ano-rectal malformation. The prognosis mostly depends on the severity of the associated anomalies rather than

on the ano-rectal malformations severity itself. Thorough systemic clinical and radiological examination must be done to detect any associated anomalies at an early presentation which should be managed as soon as possible to reduce the future morbidity and mortality. In this study while most of the congenital cardiac anomalies associated with ano-rectal malformation were of the mild type and had no effect on their surgical reconstruction, some of these associated anomalies were serious and affect the prognosis. Preoperative echocardiographic evaluation of all cases of ano-rectal malformations is important and mandatory to reduce the morbidity and mortality.

REFERENCES

- Abadi, S.A., Abadi, N.A., Mashrabi, O. and Fatorachi, H. 2008. Congenital hear anomalies in babies with imperforate anus and its mortality. *Res J Biol Sci.*, 3:922-924.
- Alford, B.N. and McIlhenney, J. 1977. The Newborn and Young Infant. In: Grainger, R.G. and D. Allison (Eds). Grainger and Allins Diagnostic Radiology: A Textbook of Medical Imaging. 3rd Edn. New York, Churchill Livingstone, pp:1114-1188.
- Ashcraft, K.W. 2006. Non urologic anomalies associated with anorectal malformations. In: Holschneider, A.M., Hutson, J.M., eds. Anorectal Malformations in Children. Germany: Springer, 263-268
- B I nescu, R.N., Topor, L. and Moga, A. 2013. Anomalies associated with anorectal malformations. *Chirurgia (Bucur)*. 108(1): 38-42.
- Chéhab, G. *et al.* 2007. Congenital heart disease associated with gastrointestinal malformations. *J Med Liban.*, 55(2):70-4.
- Hassink, E.A., Rieu, P.N., Hamel, B.C., Severijnen, R.S., vd Staak, F.H. and Festen, C. 1996. Additional congenital defects in anorectal malformations. *Eur J Pediatr.*, 155:477-482
- Kamal, S.K. and Ahmad, S.A. 2013. Congenital cardiac anomalies and imperforate anus: A hospital's experience. *J Cardiovascular Disease Research*, 4, 34-36
- Javid, P.J., Barnhart, D.C., Hirschl, R.B., Coran, A.G. and Harmon, C.M. 1998. Immediate and long-term results of surgical management of low imperforate anus ingirls. *J.Ped. Surg.*, 198-203.
- Kuroda, T., Kitano, Y., Tanaka, H., *et al.* 2011. Strategy for surgery in neonates with coexisting congenital heart disease. *Nihon Geka Gakkai Zasshi*. 112: 245-249
- Levitt, M.A. and Peña, A. 2006. Management in the newborn period. In: Holschneider AM, Hutson J, eds. Anorectal Malformations in Children. Germany: Springer, 289-294
- Liu, G., Yuan, J., Geng, J., Wang, C. and Li, T. 2004. The treatment of high and intermediate anorectal malformations: one stage or three procedures? *J Pediatr Surg.*, 39:1466-1471
- Merwe, V.D., Cox, E.S. and Numanoglu, A. 2017. Anorectal malformations associated congenital anomalies and their investigation in a South African setting. *Pediatr Surg Int.*, 33 (8):875-882.
- Murphy, F., Puri, P., Hutson, J. and Holschneider, A.M. 2006. Incidence and frequency of different types and classification of anorectal malformations: Holschneider AM, Hutson J, Eds. Anorectal Malformations in Children. Germany: Springer, 160-183

- Nah, S.A., Ong, C.C., Lakshmi, N.K., Yap, T.L., Jacobsen, A.S. and Low, Y. 2012. Anomalies associated with anorectal malformations according to the Krickbeck anatomic classification. *J Pediatr Surg.*, 47(12):2273-8
- Olgun, H., Karacan, M., Caner, I., Oral, A. and Ceviz, N. 2009. Congenital cardiac malformations In neonates with apparently isolated gastrointestinal malformations. *Pediatr Int.*, 51:260-262
- Pena, A. and Hong, A. 2000. Advances in the management of anorectal malformations. *Am J Surg.*, 2004; 180:370-376.
- Ratan, S.K., Rattan, K.N., Pandey, R.M., Mittal, A., Magu, S. and Sodhi P.K. 2004. Associated congenital anomalies in patients with anorectal malformations-a need for developing a uniform practical approach. *J Pediatr Surg.*, 39:1707-1711.
- Saeed, A.A., Nser, A.A., Omid, M. and Homa, F. 2008. Congenital Heart Anomalies in Babies with Imperforate Anus and its Mortality. *Res J. Biol. Sci.*, 3(8):922-924
- Shaul, D.B. and Harrison, E.A. 1997. Classification of anorectal malformations: initial approach, diagnostic tests, and colostomy. *Semin Pediatr Surg.*, 6:187-195.
- Spouge, D. and Baird, P.A. 1986. Imperforate anus in 100,000 consecutive live-born infants. *Am J Med Genet.*, 2:151-161
- Stoll, C., Alembik, Y. and Dott, B. 2007. Associated malformations in patients with anorectal anomalies. *Eur J Med Genet.*, 50(4):281-90.
