



RESEARCH ARTICLE

P73 GENE : TUMOR SUPPRESSOR IN ORAL CARCINOGENESIS

***¹Prajakta R. Zade, ¹Alka H. Hande, ¹Minal S. Chaudhari, ¹Madhuri N. Gawande, ²Amol R. Gadail, ¹Swati K. Patil, ³Dipak D. Ghatage and ⁴Satyajit A. Tekade**

¹Department of Oral Pathology & Microbiology, Sharad Pawar Dental College & Hospital, Datta Meghe Institute of Medical Sciences, Wardha, Maharashtra, India

²Department of Dentistry, Indira Gandhi Medical College, Nagpur, Maharashtra, India

³Department of Oral Pathology & Microbiology, Triveni Institute of Dental Sciences, Hospital & Research Centre, Bilaspur, Chhattisgarh, India

⁴Department of Oral Pathology & Microbiology, Modern Dental College & Research Centre, Indore, Madhya Pradesh, India

ARTICLE INFO

Article History:

Received 18th May, 2017
Received in revised form
25th June, 2017
Accepted 23rd July, 2017
Published online 31st August, 2017

Key words:

p73,
Carcinogenesis,
Oral squamous cell carcinoma,
Potentially malignant disorders.

ABSTRACT

Introduction: The biology and regulation of p73, a p53 homologue is complex, since the gene incorporates both tumor-suppressive and protooncogenic functions. However, the p73 gene is rarely mutated in tumors. A better understanding of p73 pathway is mandatory for the improvement of oral cancer diagnosis and treatment.

Aim: The aim of the present study was to evaluate p73 expression in oral potentially malignant disorders compared to oral squamous cell carcinoma.

Methods & Materials: p73 expression was assessed in 30 oral squamous cell carcinoma, 30 oral potentially malignant disorders & 10 normal oral mucosa. The immunohistochemistry was carried out by using rabbit anti-human antibody against p73.

Results: The Kruskal-Wallis test showed significant increase in p73 expression from normal oral mucosa to potentially malignant disorders to oral squamous cell carcinoma ($p=0.00$). Using Mann-Whitney test, the p73 expression was significantly higher in severe dysplasias than moderate and mild dysplasias ($p=0.00$). Similarly, the p73 expression was significantly higher in poorly differentiated squamous cell carcinomas than moderately and well differentiated squamous cell carcinomas ($p=0.00$). However, p73 expression was statistically insignificant ($p=0.853$) between severe dysplasia and well differentiated squamous cell carcinomas.

Conclusion: The results suggest that p73 acts as a tumor suppressor gene in oral carcinogenesis. From this evidence, it is likely that p73 protein isoforms are instrumental for the maintenance of head & neck squamous epithelial stem cells and progenitors. Conversely, loss of p73 expression is associated with keratinocyte differentiation. Therefore, it is proposed that p73 probably plays a role in the maintenance of stem and progenitor cells, leading to the control of early epithelial differentiation stages.

Copyright©2017, Prajakta R. Zade et al. This is an open access article distributed under the Creative Commons Attribution License, which permits unrestricted use, distribution, and reproduction in any medium, provided the original work is properly cited.

Citation: Prajakta R. Zade, Alka H. Hande, Minal S. Chaudhari et al. 2017. "P73 gene : Tumor suppressor in oral carcinogenesis", *International Journal of Current Research*, 9, (08), 56601-56606.

INTRODUCTION

Oral Squamous Cell Carcinoma (OSCC), the most common head and neck cancer is characterized by highly aggressive tumor growth and results in significant morbidity, commonly in the form of disfigurement and loss or impairment in the ability to speak and swallow. These medical and psychosocial consequences are exacerbated by relatively stagnant survival rates over the last several years despite advances in treatment

*Corresponding author: Prajakta R. Zade,

Department of Oral Pathology & Microbiology, Sharad Pawar Dental College & Hospital, Datta Meghe Institute of Medical Sciences, Wardha, Maharashtra, India

(Yang Zhang et al., 2012). A distinguishing feature of SCCs is their high degree of cellular heterogeneity, with cell populations at various stages of differentiation, which are able to reverse lineage commitment to proliferative stages as well as enter into quiescent, slow-cycling growth phases. These features make them particularly difficult to target with monotherapeutic approaches as described by Elkabets et al. (2015) (Paolo Dotto and Anil K. Rustgi, 2016). It is common for patients with OSCC to develop a series of potentially malignant disorders at several sites within the upper digestive mucosa established by Lumerman, et al. (1995) (Pauline Bidaud et al., 2010). Therefore, understanding susceptibility to tobacco-related malignancies holds great promise for primary

cancer prevention and identifying markers of risk among cancer survivors would greatly enhance secondary prevention, which is currently limited to rather simplistic clinical post-treatment screenings (Fanglin Li *et al.*, 2009). Numerous molecular pathology studies have led to consider OSCC carcinogenesis as a multiple step process arising from “fields of cancerisation” as stated by Braakhuis, *et al.* (2005). These fields contain genetically altered cells and are presumed to develop independently at multiple sites. The concept of a step-wise transition from oral potentially malignant lesions (OPMLs) to oral squamous cell carcinoma (OSCC) is well-established, but it can be difficult to predict if and when an OPML will undergo full transformation and result in a tumor. The presence of oral epithelial dysplasia (OED) in OPMLs is generally accepted as one of the most reliable predictors of malignant development (Ahmad A. AbdulMajeed and Camile S. Farah, 2013). Among the key genes involved in oral malignancy, the tumour suppressor gene *TP53* is the most targeted. The tumour suppressor p53 was discovered in 1979 and almost 20 years later, two relatives’ p63 and p73 were discovered (Linda Boldrupa *et al.*, 2007). Daniel Caput identified the first p53-related gene, p73, homologous of p53 in 1997 (Meredith S. Irwin and William G. Kaelin, 2001). The p73 shares more than 60% similarities of amino acid as in p53 DNA binding region, 58% similarities with p53 tetramerization domain and 29% similarities with p53 transactivation (TA) domain (Ambar Kusuma Astuti *et al.*, 2011). The human p73 genes consist of 15 exons spanning around 80kb on the genome. It has been mapped to chromosome 1p36.33. The p73 gene encodes 4 alternatively spliced isoforms with distinct ATG at the N-terminus (TA, Δ ex2, Δ ex2/3, Δ N) and 7 alternatively spliced isoforms at C-terminus (α , β , γ , δ , ϵ , ζ , and η) (Cai Christine Yuyang *et al.*, 1999; Kazushi Inoue and Elizabeth A. Fry, 2014) as stated by Moll & Slade (2004) and Bourdon (2005). The TAp73 γ isoforms most closely resemble the full-length wild-type TAp53 (Kazushi Inoue and Elizabeth A. Fry, 2014). It is generally accepted that TAp73 is a bonafide tumor suppressor, being able to induce cell death and cell cycle arrest; conversely, Δ Np73 shows oncogenic properties, inhibiting TAp73 and p53 functions. In general, TAp73 and Δ Np73 show opposing roles. However, in apparent contradiction to this alternative suppressor/oncogene hypothesis, the first total p73 knockout mouse model showed developmental abnormalities but no spontaneous tumors. This is in striking contrast with p53 knockout mice, which show high susceptibility to spontaneous and induced carcinogenesis. In many of the tumor specimens analyzed, the loss of heterozygosity of p73 was more frequent than the loss of the remaining p53 allele, revealing a potent tumor suppressor function for p73 (Alessandro Rufini *et al.*, 2011).

Unlike p53, p73 is rarely mutated in cancers, but its expression is often deregulated and it is important for our understanding of oncogenic pathways that we investigate why mutations in p53 are common whereas those in its highly homologous partner, p73, are rare—an area that has received surprisingly little study. Mutation of p73 occurred in just less than 0.5% of cancers (Ambar Kusuma Astuti *et al.*, 2011). Therefore, this gene does not function as a traditional tumor-suppressor gene. Furthermore, increased p73 expression was found in human malignancies associated with p53 mutations suggesting that p73 may act as a tumor suppressor with overlapping functions of p53 or compensating for the loss of function of p53 caused by mutations (Fanglin Li *et al.*, 2009). Many studies have reported p73 overexpression in human cancers including lung

cancer, colon cancer, ovarian cancer, endometrial cancer and breast cancer while others showed that a loss of p73 in pediatric acute lymphocytic leukemia (Mei Yong *et al.*, 2014) is associated with tumor progression and metastasis. Thus, whether p73 is a tumor suppressor gene or an oncogene has been a matter of debate. Although p73 has been much less studied than its counterpart, few studies have investigated its role in OSCC. p73 may play an independent and/or compensatory functional role for p53 in OSCC development and progression (Fanglin Li *et al.*, 2009). Therefore, the main aim of the study was to evaluate p73 expression in oral potentially malignant disorders compared to oral squamous cell carcinoma to better understand its role in oral carcinogenesis.

MATERIALS AND METHODS

This laboratory based retrospective study was carried out in the Department of Oral Pathology & Microbiology, Sharad Pawar Dental College, Sawangi (M), Wardha, after obtaining approval from the Institutional Ethical Committee, Datta Meghe Institute of Medical Sciences, Sawangi (M), Wardha, Maharashtra. The study included 30 histopathologically diagnosed cases of oral squamous cell carcinoma (10 each of well, moderately & poorly differentiated oral squamous cell carcinoma), 30 cases of oral potentially malignant disorders (10 each of mild, moderate & severe epithelial dysplasias) & 10 normal oral mucosa. The patient’s details regarding age, gender and location of lesions were recorded. The patients who underwent preoperative chemotherapy and had recurrence as well as second primary tumors were excluded from the study. The study was performed on tissues fixed in 10% neutral buffered formalin, paraffin embedded tissue. 5 μ m sections were cut serially for IHC to evaluate expression of p73 antigens.

Immunohistochemical method for detection of p73 antigen

For immunohistochemistry, the universal immunoenzyme polymer method was used. The sections were deparaffinized with xylene and hydrated. The slides were heated in microwave oven for 12 min in 0.01M sodium citrate buffer (pH 6.0) for antigen retrieval and bench cooled for 20 min, and again the same cycle was repeated. Endogenous peroxidase activity was blocked by incubating the section with 3% H₂O₂ in methanol for 30 min. The sections were then washed three times with gentle shaking in TBS for 5 min each. To prevent nonspecific reactions, sections were incubated with 10% serum for 10 min. Prediluted p73 antibody [P73 (H-79) sc-7957 IgG rabbit polyclonal antihuman antibody. Santa Cruz Biotechnology, INC] were incubated at room temperature in humidifying chamber for 60 min and then at 4°C overnight. Known oral squamous cell carcinoma sample showing good p73 expression was used as positive control. One section from each positive control was used as negative control by omitting the primary antibody and by incubating with TBS/serum. After the primary antibody and antigen reaction, the sections were rinsed in TBS three times for 10 min each. The secondary antibody [HRP labeled Polymer Antimouse (Dako Envision+System, Product Code: K4000, Dako North America Inc.)] was incubated at room temperature in humidifying chamber for 30 min. After the TBS washing three times for 10 min, freshly prepared substrate/chromogen solution of 3’3-diaminobenzidine (DAB) in provided buffer (mixing 5 μ L of concentrated DAB in 50 mL of substrate buffer) was used to visualize the antigen-antibody reaction. Finally, the sections

were counterstained in Harris's hematoxylin. Sections were examined by conventional light microscope (Leica DMLB2).

Assessment of immunohistochemically stained sections

The cells were considered positive for p73 antigen if there was an intranuclear DAB staining (brown colour). All the stained nuclei were scored positive regardless of their intensity of staining. Cells that lacked a clear nucleus were excluded. Minimum of 1000 cells were counted in each section. Tissue sections were scanned at a 100X magnification for most heavily labelled p73 positive cells. Cell counts were made at 400X magnification with conventional light microscope in 10 randomly selected fields. The number of positively stained nuclei was expressed as a percentage of the total number counted. $p73 \text{ Labelling Index (LI)} = \text{Number of IHC positive cells (p73)} \times 100 / \text{Total number of cells observed}$.

Statistical analysis

Group mean for p73 LI was derived for each group. Statistical analysis of data was done using SPSS 16.0 version software for windows. The Kruskal-Wallis test was used to detect variation of p73 LI amongst the three groups of OPMD & OSCC. Mann-Whitney test was used to compare between OPMD & OSCC. The level of statistical significance is at $P < 0.05$.

RESULTS AND OBSERVATIONS

p73 was expressed in all the cases of normal mucosa, OPMD & OSCC. In normal mucosa, p73 staining was intense and homogenous in all cells of the undifferentiated basal layer and the suprabasal layers; no staining was observed in the superficial differentiated cell layers. In OPMD (all grades of epithelial dysplasias), p73 staining was predominantly in suprabasal cell layers (Figure 1).

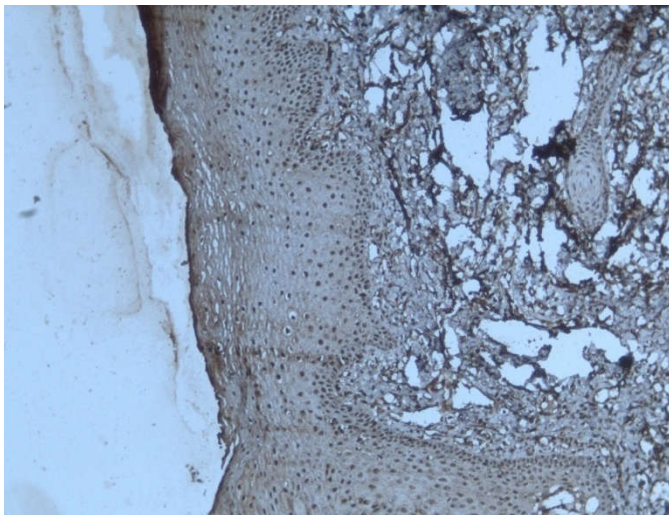


Figure 1. Photomicrograph of immunostaining for p73 antigen using monoclonal antibody in epithelial dysplasia shows intense and homogenous p73 immunostaining in all cells of the undifferentiated basal layer and the suprabasal layers; slight staining was observed in the superficial differentiated cell layers. (original magnification X 100).

However, in moderately & poorly differentiated squamous cell carcinomas, homogenous staining was observed in all tumor cells (Figure 2).

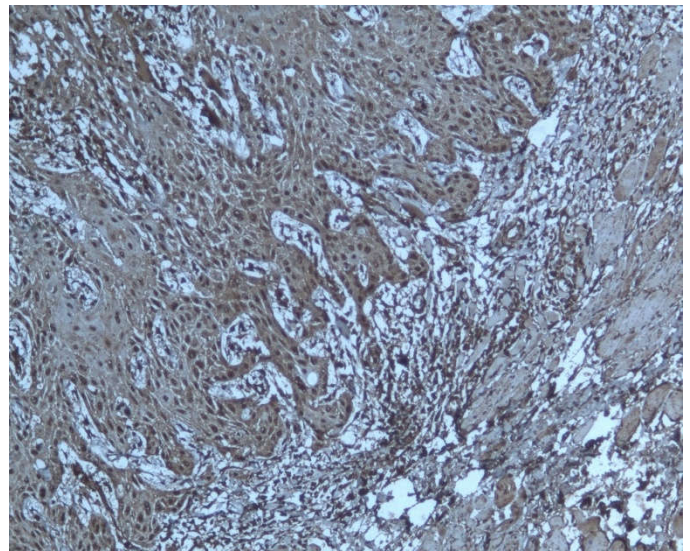


Figure 2. Photomicrograph of immunostaining for p73 antigen using monoclonal antibody in moderately differentiated squamous cell carcinoma shows homogenous p73 immunostaining in all tumor cells. (original magnification X 100)

In contrast, in well differentiated squamous cell carcinomas, p73 expression was restricted to the undifferentiated cell layer at the periphery of carcinomatous clusters. The most differentiated cells localized in the centre of the clusters and adjacent to keratin pearls, did not reveal any p73 expression (Figure 3).

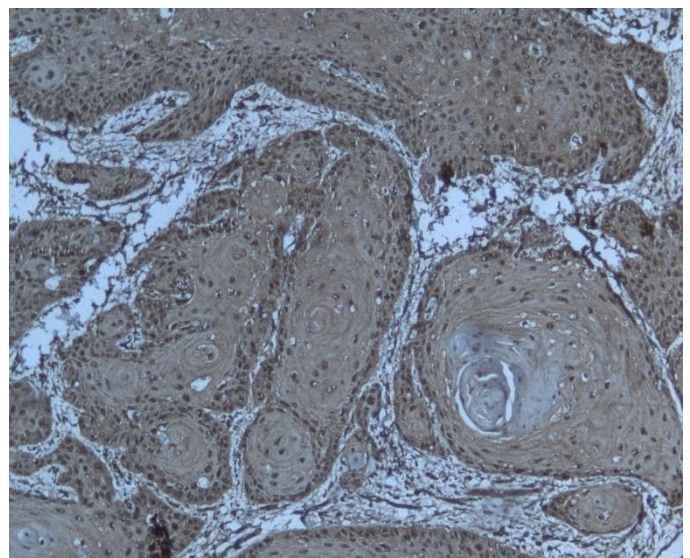


Figure 3. Photomicrograph of immunostaining for p73 antigen using monoclonal antibody in well differentiated squamous cell carcinoma shows p73 immunostaining restricted to the undifferentiated cell layer at the periphery of carcinomatous clusters whereas the most differentiated cells localized in the centre of the clusters and adjacent to keratin pearls, does not reveal any p73 immunostaining. (original magnification X 100)

Thus, our results suggest that loss of p73 protein expression is associated with the level of differentiation of squamous epithelial tissues of the head and neck. p73 counts were observed in increasing order from normal mucosa to grades of epithelial dysplasia to grades of squamous cell carcinoma (Table 1) which was statistically significant ($p=0.00$) by Kruskal-Wallis test (Table 2).

Table 1. Descriptive statistics for p73 labelling index in normal mucosa; mild, moderate & severe epithelial dysplasia and well, moderately & poorly differentiated squamous cell carcinoma

P73	N	Mean	Std. Deviation	Std. Error	95% Confidence Interval for Mean		Minimum	Maximum
					Lower Bound	Upper Bound		
Normal	10	35.6200	9.82817	3.10794	28.5894	42.6506	22.10	56.60
Mild ED	10	45.8100	5.25980	1.66329	42.0474	49.5726	35.90	51.80
Mod ED	10	60.9500	3.94638	1.24795	58.1269	63.7731	54.10	67.70
Severe ED	10	73.6000	5.37318	1.69915	69.7563	77.4437	63.60	81.90
WDSCC	10	71.3800	9.26065	2.92847	64.7553	78.0047	54.60	82.10
MDSCC	10	80.1000	6.22129	1.96734	75.6496	84.5504	69.30	88.40
PDSCC	10	92.1500	3.30933	1.04650	89.7826	94.5174	87.40	98.20
Total	70	65.6586	19.40533	2.31938	61.0315	70.2856	22.10	98.20

Table 2. Kruskal-Wallis test for p73 Labelling Index in normal, epithelial dysplasia and squamous cell carcinoma

p73	
Chi-Square	40.408
df	2
Asymp. Sig.	.000

Using Mann-Whitney test, the p73 expression was significantly higher in severe dysplasias than moderate and mild dysplasias ($p=0.00$). Similarly, the p73 expression was significantly higher in poorly differentiated squamous cell carcinomas than moderately and well differentiated squamous cell carcinomas ($p=0.00$). However, p73 expression was statistically insignificant ($p=0.853$) between severe dysplasia and well differentiated squamous cell carcinomas (Table 3).

Table 3. Mann Whitney U test for comparison of p73 Labelling Index between severe epithelial dysplasia and well differentiated squamous cell carcinoma

p73	
Mann-Whitney U	47.000
Wilcoxon W	102.000
Z	-.227
Asymp. Sig. (2-tailed)	.821
Exact Sig. [2*(1-tailed Sig.)]	.853

DISCUSSION

The head and neck squamous epithelium (HNSE), with basal layers containing stem cells and progenitors to gradually differentiated squamous cells, represents the paradigm of stratified epithelium which is consistently subjected to environmental genotoxic insults due to alcohol, tobacco and arecanut consumption. Therefore, this epithelium requires a perfect machinery to control and repair genotoxic damage and eliminate cells harbouring mutations. In this respect, p53 protein is likely to play a key role in the maintenance and control of HNSE homeostasis, with 60% of mutations in head & neck squamous cell carcinomas (HNSCC) till date (Soussi, *et al.*, 1994; Ahomadegbe, *et al.*, 1995). The two p53 homologues, p63 and p73, could therefore participate in HNSE homeostasis and could possibly replace p53 functions, when altered (Laurens Laetitia Faridoni and Bosq Jacques, 2001). Data regarding p73 mutation is limited in the literature; however different roles of several isoforms of p73 as tumor suppressor gene with anti-apoptosis effect (TAP73) and as oncogene ($\Delta NP73$) have been elucidated (Wu and Wei, 2002; Horikawa and Barret, 2003). In human malignancies involving p53 mutations, p73 expression has been found to be increased, proposing an additional role for p73 as a compensator for p53

in the event of dysfunctional p53 mutations (Yang Zhang *et al.*, 2012). Immunohistochemical analyses performed on normal tissues (oral cavity, oropharynx, hypopharynx and larynx) clearly showed that, p73 expression was restricted to undifferentiated cells situated in the basal layers of stratified HNSE. Immunostaining was uniformly distributed with a similar intensity in keratinocyte stem cells and progenitors, indicating protein expression in both proliferating and dormant cells. By contrast, differentiated cell layers did not show any p73 expression. Similar findings were noted in the present study. From this evidence, it is likely that p73 protein isoforms are instrumental for the maintenance of HNSE stem cells and progenitors. Conversely, loss of p73 expression is associated with keratinocyte differentiation. It is proposed that p73 probably plays a role in the maintenance of stem and progenitor cells, leading to the control of early epidermal differentiation stages (Ahmad A. AbdulMajeed and Camile S. Farah, 2013).

Furthermore, in our study, p73 expression was found in the less differentiated cells at the periphery of carcinomatous cluster of well differentiated carcinomas whereas negative staining is observed in the areas of keratin pearl formation. This observation suggests a relationship between p73 protein and the differentiation of oral stratified squamous epithelia. These findings appear to be consistent with the results of Faridoni-Laurens, *et al.* and Choi, *et al.* p73 has a sterile alpha motif (SAM) domain, which is not present in p53. These SAM domain-containing proteins are involved in development regulation (Levrero *et al.*, 2000; Arrowsmith, 1999). Because of the existence of the SAM domain in p73, it was postulated that p73 would be related to differentiation. Developmental abnormalities including neurological, pheromonal, immunological and inflammatory defects were noted in p73 knockout mice due to the absence of all TAp73 and $\Delta NP73$ isoforms (Kazushi Inoue and Elizabeth A. Fry, 2014; Hiroyuki Kumamoto *et al.*, 2005). Laetitia Faridoni-Laurens, Jacques Bosq (2001) and Yuk-Kwan Chen, Shui-Shang Hsue *et al.* (2004) in their studies revealed intense p73 nuclear staining in basal and parabasal cells of normal squamous epithelium, in contrast with complete absence of staining in more superficial cell layers. For buccal lesions deriving from mild, moderate and severe ED, p73 protein was observed in basal and parabasal layers and in more superficial cell layers corresponding to the spinous layer. Moderately differentiated carcinomas demonstrated homogeneous and diffuse staining in all tumor cells, while only basal cells were stained in well differentiated carcinomas as in normal tissue. These findings are in accordance with the present study. Hong-Ran Choi, *et al.* (2002) and Chen, *et al.* (2003) determined the interrelationship between p53, p63 and p73 genes in tumorigenesis in head and neck squamous cell carcinoma. p73 expression was associated with distant metastasis as well as perineural/vascular invasion.

Hong-Ran Choi, *et al.* (2002) indicated that (1) p63 and p73 expression may represent an early event in HNSC tumorigenesis, (2) the lack of correlation between p73 or p63 and p53 expression suggests an independent and/or compensatory functional role, and (3) p73 expression may play a part in HNSC progression. Faridoni-Laurens, *et al.* (2008) analyzed the expression of TAp73 and Δ TAp73 in HNSCC and compared them to the p53 status. They found that all of the p73 isoforms were upregulated in comparison to those in normal adjacent tissue. All of the HNSCC specimens studied had at least one p53 mutation and/or one Δ TAp73 transcript alteration. Although both the Δ Np73 and the TAp73 transcripts were upregulated in HNSCC, the predominant protein in the cancers expressed was Δ Np73. Furthermore, a trend was found for better overall survival in patients with a low expression of Δ Np73. Thus deregulation of both the p53 and the p73 pathways plays an important role in inducing HNSCC (Kazushi Inoue and Elizabeth A. Fry, 2014).

Indeed, there is increasing evidence that p73 effects on tumor progression do not rely on total p73 levels but rather on the ratio between TA and δ N expression. In addition, δ N isoforms have a longer half-life than TAp73, implying that even if the transcription of N-terminal isoforms is identical, δ N predominates due to its higher stability. For these reasons, overexpression of δ Np73 in tumors could be an important mechanism in blocking the proapoptotic functions of TAp73 and p53. Many reports have highlighted that increased levels of δ Np73, without a concomitant increase of TA, are a significant risk factor for reduced survival and thus correlates with prognosis. This has been shown in neuroblastoma, prostate, and cervical cancers. Finally, similar findings have been reported in head and neck squamous cell carcinomas with a significant correlation between δ Np73 levels and poor prognosis. Thus, in the majority of cancers in which p53 is mutated or otherwise inactive, exploiting TAp73 as a proapoptotic p53 substitute is an attractive therapeutic option (Alessandro Rufini *et al.*, 2011). However, the p73 gene is rarely mutated in tumors, so appropriate pharmacological manipulation of the p73 pathway is a very promising approach for cancer therapy (Andrea Bisso *et al.*, 2011). A better understanding of how the p73 pathway works is mandatory to discover additional players intervening in this pathway and has important implications for the improvement of cancer treatment with the development of new molecules or with the reposition of currently available drugs.

In summary, although somatic point mutations are rarely found in p73 in human cancers, aberrant splicing that result in Δ TAp73 overexpression are very frequently found. Since these proteins have transdominant activity on all p53 family proteins, it is speculated that this abnormal splicing contributes to human carcinogenesis, especially in ovarian, breast, lung, prostate cancers, HNSCCs and hematological malignancies. Published results indicate that Δ TAp73 overexpression is associated with poor clinical outcomes at least in lung cancer and HNSCCs. Judging from the very low frequency of mutations for p73 in human cancers, it is not a classical tumor suppressor gene, but the possibility remains that it is haplo-insufficient tumor suppressor, just like p27Kip1, PTEN, or DMP1 (Kazushi Inoue and Elizabeth A. Fry, 2014) (Quon & Berns, 2001, Berger & Pandolffi 2011; Inoue 2001, 2007; Mallakin 2007; Sugiyama 2008; Taneja 2010; Zhu 2013; Fry 2013). Thus it can be concluded that p73 expression may be (1) associated with the differentiation of oral stratified

squamous epithelium, (2) an early event in human oral carcinogenesis and (3) associated with the nodal status of patients with oral carcinoma and a possible indicator for malignant change of oral epithelial dysplasia. Therefore, the development of efficient prevention and early diagnosis of high-risk oral potentially malignant disorders is a major challenge for reducing mortality due to OSCC.

Acknowledgement

The authors thank Mr. Rupesh Maladhari, Lab Technician, Department of Oral and Maxillofacial Pathology, Sharad Pawar Dental College and Hospital, Datta Meghe Institute of Medical Sciences, Sawangi (Meghe), Wardha, Maharashtra, India.

REFERENCES

- Ahmad A. AbdulMajeed and Camile S. Farah. 2013. Can Immunohistochemistry Serve as an Alternative to Subjective Histopathological Diagnosis of Oral Epithelial Dysplasia? *Biomarkers in cancer*. 5:49-60
- Alessandro Rufini, Massimiliano Agostini, Francesca Grespi, Richard Tomasini, Berna S. Sayan, Maria Victoria Niklison-Chirou, Franco Conforti, Tania Velletri1, Antonio Mastino, Tak W. Mak, Gerry Melino, Richard A. Knight. 2011. p73 in Cancer. *Genes & Cancer*. 2 (4): 491-502.
- Ambar Kusuma Astuti, Irfan Prasetyo, Justisia Nafsi Yunita, Yuniardini Septorini Wimardhani, Febrina Rahmayanti. 2011. Profile of Human TERT and P73 in Oral Squamous Cell Carcinoma Cell Lines Compared to Normal Human Oral Mucosa: a Preliminary Study. *Journal of Dentistry Indonesia*, 18(1):10-16.
- Andrea Bisso, Licio Collavin and Giannino Del Sal. 2011. p73 as a Pharmaceutical Target for Cancer Therapy. *Current Pharmaceutical Design*. 17: 578-590
- Arrowsmith CH. 1999. Structure and function in the p53 family. *Cell Death Differ*. 6: 1169-73.
- Cai Christine Yuyang *et al.* 1999. Molecular alteration of p73 in human oesophageal squamous cell carcinoma: loss of heterozygosity occurs frequently; loss of printing and elevation of p73 expression may be related to defective p53. *Carcinogenesis*. 21(4):683-689.
- Chen, Y.K., S.S. Huse & L.M. Lin. 2003. Differential expression of p53, p63 and p73 protein in human squamous cell carcinoma. *Clin Otolaryngol.*, 28: 451-455.
- Choi Hong-Ran, Batsakis John G. 2002. Differential expression of p53 gene family members p63 and p73 in head and neck squamous tumorigenesis. *Human Pathology*, 33(2): 158-163.
- Fanglin Li, Erich M Sturgis, Mark E Zafereo, Z Liu, L-E Wang, Qingyi Wei, Guojun Li. 2009. p73 G4C14-to-A4T14 polymorphism and risk of second primary malignancy after index squamous cell carcinoma of head and neck. *Int J Cancer*, December 1; 125(11): 2660-2665.
- Hiroyuki Kumamoto, Kousuke Ohki, Kiyoshi Ooya. 2005. Expression of p63 and p73 in ameloblastomas. *J Oral Pathol Med.*, 34: 220-6.
- Horikawa I, Barret JC. 2003. Transcriptional regulation of the telomerase hTERT gene as a target for cellular and viral oncogenic mechanisms. *Carcinogenesis*. 24:1167-76.
- Kazushi Inoue and Elizabeth A. Fry. 2014. Alterations of p63 and p73 in human cancers. *Subcell Biochem.*, 85: 17-40.
- Laurens Laetitia Faridoni, Bosq Jacques. 2001. P73 expression in basal layers of head and neck squamous epithelium: a

- role in differentiation and carcinogenesis in concert with p53 and p63. *Oncogene*. 20: 5302-5312.
- Levrero M, De Laurenzi V, Costanzo A, Gong J, Wang JY, Melino G. 2000. The p53/p63/p73 family of transcription factors: overlapping and distinct functions. *J Cell Sci.*, 113: 1661–70.
- Linda Boldrupa, Jean-Christophe Bourdonb, Philip J. Coatesc, Björn Sjöströmd, Karin Nylandera. 2007. Expression of p53 isoforms in squamous cell carcinoma of the head and neck. *Eur J Cancer*, February; 43(3): 617–623.
- Mei Yong, Ling Yang, Qimuge Suyila, Wenyan Han, Hongwei Yuan, Cheng Zhao1, Xiulan Su. 2014. Expression and clinical implications of P53, P63, and P73 protein in malignant tumor of the parotid gland. *Turk J Med Sci.*, 44: 875-882.
- Meredith S. Irwin and William G. Kaelin. 2001. P53 family update: p73 and p63 develop their own identities. *Cell growth & Differentiation*, 12:334-37.
- Paolo Dotto G. and Anil K. Rustgi. 2016. Squamous cell cancers: a unified perspective on biology and genetics. *Cancer Cell*, May 9; 29(5): 622–637.
- Pauline Bidaud, Jacques Chasle, François Sichel, Stéphane Rousseau, Pascal Petit, Didier Pottier, Jean-Michel Picquenot, Marie-Yolande Louis and Mathilde Lechevrel. 2010. Expression of p53 family members and CD44 in oral squamous cell carcinoma (OSCC) in relation to tumorigenesis. *Histol Histopathol.*, 25: 331-339.
- Wu J, Wei LX. 2002. Telomere and telomerase in on-cology. *Cell Res.*, 12:1-7.
- Yang Zhang, Erich M Sturgis, Zhigang Huang, Mark E. Zafereo, Qingyi Wei, Guojun Li. 2012. Genetic variants of the p53 and p73 genes jointly increase risk of second primary malignancies in patients after index squamous cell carcinoma of the head and neck. *Cancer*, January 15; 118(2): 485–492.
- Yuk-Kwan Chen, Shui-Shang Hsue et al. 2004. P73 expression for human buccal epithelial dysplasia and squamous cell carcinoma: Does it correlate with nodal status of carcinomas and is there a relationship with malignant change of epithelial dysplasia? *Head and Neck*, 26(11): 945-952
