



CASE REPORT

RELAPSING POLYCHONDROITIS WITH C-ANCA POSITIVITY WITHOUT CLINICAL VASCULITIS

*¹Akhter A Raina, ¹Bilal A Mir and ²Zubair A Lone

¹Department of Medicine Govt. Medical Collage, Srinager Kashmir, India

²Department of E.N.T. Govt. Medical Collage, Srinager Kashmir, India

ARTICLE INFO

Article History:

Received 11th May, 2017

Received in revised form

19th June, 2017

Accepted 23rd July, 2017

Published online 31st August, 2017

Key words:

Relapsing polychondritis,
Cartilaginous, Steroids.

Copyright©2017, Akhter A Raina et al. This is an open access article distributed under the Creative Commons Attribution License, which permits unrestricted use, distribution, and reproduction in any medium, provided the original work is properly cited.

Citation: Akhter A Raina, Bilal A Mir and Zubair A Lone, 2017. "Relapsing polychondritis with c-anca positivity without clinical vasculitis", International Journal of Current Research, 9, (08), 56571-56573.

ABSTRACT

Relapsing polychondritis is a rare chronic inflammatory disorder primarily involving the cartilaginous structures of ears, nose and tracheobronchial tree. The disease can involve the eyes and the muskeloskeletal system with seronegative non erosive arthritis. We described a case of a 25 year female with relapsing polychondritis. This patient presented with history of throat pain, difficulty in breathing, hoarseness of voice from last one week and bilateral hearing impairment. On examination patient had bilateral auricular involvement with sparing of ear lobules, conjunctivitis, nasal chondritis and subglotic edema. Investigations revealed c-ANCA positivity and bilateral sensori-neural hearing loss. Patient was started on steroid therapy immediately and her symptoms improved.

INTRODUCTION

Relapsing polychondritis primarily affecting the cartilaginous structures of the body is an autoimmune disorder of unknown etiology. Other proteoglycan rich non-cartilaginous organs may also get involved (Kent *et al.*, 2004). It usually manifests at 40-50 years of age, but children and elderly may be affected as well. There is no gender predisposition and no apparent familial tendency (Kasper *et al.*, 2005). Relapsing polychondritis usually presents as necrotizing episodic inflammation of the cartilage that at times may be severe (Miller, 2007). The commonest clinical manifestations of this rare disease include auricular chondritis, nasal chondritis, laryngotracheal involvement, ocular involvement and seronegative non-erosive arthritis (Letko *et al.*, 2002). We describe a case of relapsing polychondritis in a 25 year female. Only one case has been reported from Kashmir and we report the second.

Case report

A 25 year unmarried female presented to our hospital with throat pain, hoarseness of voice and breathlessness from the last one week. Patient initially started with dull aching pain in the throat. Patient consulted a practioner and was advised some antibiotics and NSAIDS. After taking these medications

there was no gross improvement in her pain and she also experienced hoarseness of voice and breathlessness. Patient came to our hospital and she was breathless and a possibility of laryngeal edema due to anaphylactic drug reaction was made initially. After stabilization of the patient, thorough history and clinical examination was performed. Patient revealed that she had episodes of pain and swelling of both ears and nose from the last 2 years for which she used to take some NSAIDS with temporary relief. There is also history of arthritis of both knees during these episodes and decreased hearing from last one year. Patient also noted history of multiple episodes of redness and increased lacrimation from both eyes. Patient denies any history of rash, discharge from nose or ears, fever, hemoptysis, haematuria or oligurea, pain or numbness of limbs. Clinical examination of the patient revealed active inflammatory swelling of the auricular cartilages with sparing of lobules and loss of architecture of the ear (Fig.1) and (Fig.2).

There was bilateral conjunctivitis and active inflammation of nasal bridge. On FOL there was tenderness and edema in the sub-glottic region. Rest of the examination was normal. Complete blood count revealed normocytic normochromic anemia with Hb of 10.8 and ESR of 62 mm. Liver function tests, kidney function tests, blood glucose, electrolytes and uric acid levels were within normal range. Routine urine examination was normal and cultures sterile. ECG and radiographs of chest and neck were normal. Antinuclear antibody, anti-dsDNA and rheumatoid factor were negative. c-ANCA:Serine proteinase 3(PR-3) antibody was positive 4.82

*Corresponding author: Akhter A Raina,

Department of Medicine Govt. Medical Collage, Srinager Kashmir, India.

u/ml (<3.5 negative). Pure tone audiometry revealed bilateral sensori-neural hearing loss (Fig.3).

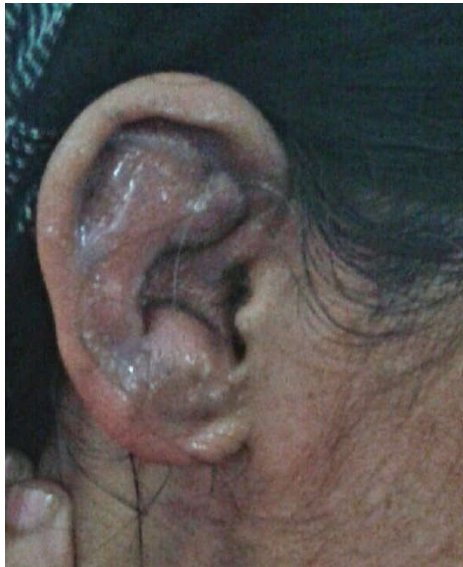
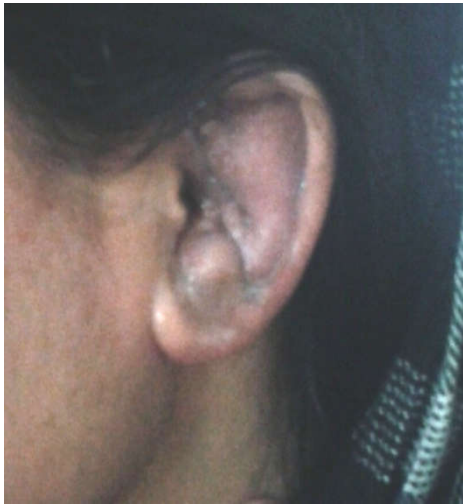
Fig. 1 left ear, fig.2 right ear loss of architecture of left ear with sparing of ear lobule and inflammation of right auricular cartilage

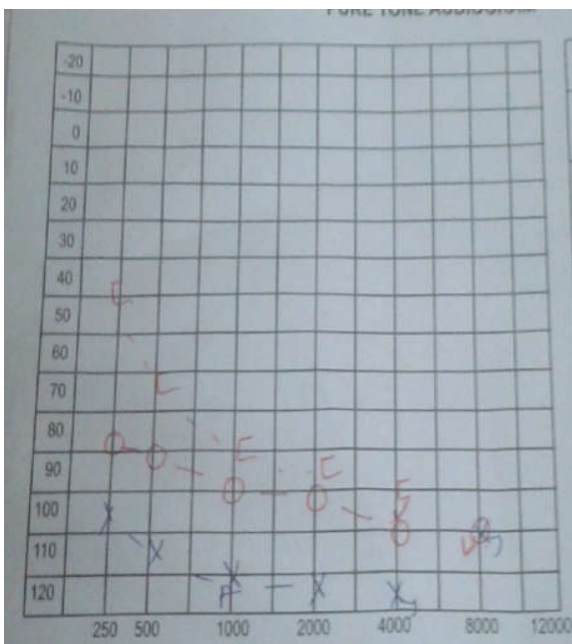


Fig.3. Bilateral sensori-neural hearing loss on PTA

In view of bilateral chondritis of the auricular cartilages with sparing of the ear lobules, nasal chondritis, chondritis of larynx and bilateral conjunctivitis and sensorineural hearing loss, a diagnosis of relapsing polychondritis was made as per the criteria by MacAdam *et al* and Damiani and Levine. Patient was started on prednisolone 1mg/kg body weight and there was a dramatic response to steroid therapy and patient was discharged and steroids tapered over a period of 6 weeks.

DISCUSSION

Relapsing polychondritis is an inflammatory disease of cartilaginous structures of the body involving ears, nose, throat, trachea, joints, eyes and cardiac valves. However, the etiology of RP is still not fully understood (Sharma *et al.*, 2013; Damiani and Levine, 1997). The disease usually manifests in the age group between 40-50 years, but children and elderly can be affected as well. There is no clear cut HLA association or hereditary predisposition reported (Luthra, 1998). The frequency of episodes of chondritis, pattern of cartilaginous involvement and the clinical features vary widely among patients. The most common clinical presentation of RP is auricular chondritis, which affects 85% of patients. Involvement of laryngotracheal cartilage occurs in 50% of patients. Usual manifestations being hoarseness of voice, tenderness over larynx and proximal trachea and non productive cough. Collapse of laryngeal or tracheal cartilage and mucosal edema can cause stridor (Kasper *et al.*, 2005). The diagnosis of RP is clinical, there are no specific serologic tests for diagnosing RP (Letko *et al.*, 2002). The diagnostic criteria by MacAdam *et al*, require three out of six of the following: bilateral auricular chondritis, nasal chondritis, non-erosive seronegative inflammatory arthritis, respiratory tract chondritis, ocular inflammation and audiovestibular damage (McAdam *et al.*, 1976). Damiani and Levine modified criteria include, one MacAdam criteria and tissue diagnosis or two MacAdam criteria and response to steroids (Damiani and Levine, 1997). Our patient had bilateral auricular chondritis, nasal chondritis, laryngeal chondritis, ocular involvement and bilateral sensorineural hearing loss. The etiopathogenesis of RP is still not clear, however immunologic reaction to type II collagen; antibodies against type XI and type IX have been found in a case of RP (Alsalameh *et al.*, 1993; Yang *et al.*, 1993). Other multi-system diseases can be associated with RP, of which systemic vasculitides are the most common. ANCA (anti-neutrophil cytoplasmic antibody) may be present in 25% of patients of RP (Papo *et al.*, 1993). Classical clinical features of one of ANCA associated vasculitides may be present in some of these patients and polychondritis is usually a secondary phenomenon (Handrock and Gross, 1993; Schina *et al.*, 2008; Mattiassich *et al.*, 2013). ANCA positivity in RP may not have any or only limited vasculitic symptoms (Papo *et al.*, 1993). There are a number of treatment options for RP. Corticosteroids remain the initial and major treatment option. Steroid therapy rapidly improve the symptoms and delay the progression of disease especially with early respiratory involvement. Other treatment options include dapson, colchicine, azathioprine, cyclosporine, methotrexate and hydroxychloroquine. At later stages of airway involvement, airway interventional therapy like metallic stent placement, positive airway pressure support or tracheostomy are used to improve airway obstruction (Rapini and Warner, 2006; Cazabon *et al.*, 2005). Early saddle nose deformity in young, respiratory involvement, anemia in elderly and co-existent vasculitis are bad prognostic factors. This case highlights the

importance of this rare disease, its varied clinical presentations and association with serologic ANCA positivity or clinical vasculitidic syndromes.

Conflict of interest: There are no conflict of interests.

REFERENCES

- Alsalameh S, Mollenhauer J, Scheuplein F, *et al.* 1993. Preferential cellular and humoral immune reactivities to native and denatured collagen types IX and XI in a patient with fatal relapsing polychondritis. *J Rheumatology*, 20(8): 1419-24.
- Cazabon, S, Over, K. and Butcher, J. 2005. The successful use of Infliximab in Resistent Relapsing Polychondritis and Associated scleritis. *Eye*, 19, 222-224.
- Damiani, J.M. and Levine, H.L. 1997. Relapsing Polychondritis- Report of Ten Cases. *Laryngoscope*, 89, 929-946.
- Handrock K, Gross WL. 1993. Relapsing polychondritis as a secondary phenomenon of primary systemic vasculitis. *Ann Rheum Dis.*, 52:895-897.
- Kasper DL, Braunwald E, Fauci AS, *et al.* (eds). 2005. Harrison's Principles of Internal Medicine. Vol 2. 16th ed. New York; McGraw-Hill. pp:2015-7.
- Kent, P. D., C. J. Michet Jr, and H. S. Luthra. 2004. "Relapsing Polychondritis." *Current opinion in Rheumatology*, vol. 16, no. 1, pp 55-61.
- Letko. E., P. Zafirakis, S. Baltatzis, A. Voudouri, C. Livir-Rallatos, and C. S. Foster, 2002. "Relapsing polychondritis: a clinical review," *Seminars in Arthritis and Rheumatism*, vol. 31, no.6, pp. 384-395.
- Luthra HS. 1998. Relapsing Polychondritis. In: klippel JH, Dieppe PA(eds), *Rheumatology*, 2nd ed, Mosby and Co, London, pp27.1-4.
- Mattiassich G, Egger M, Semlitsch G, Rainer F. 2013. Occurance of relapsing polychondritis with a rising c-ANCA titre in a c-ANCA positive systemic and cerebral vasculitis patient. *BMJ Case Rep.*
- McAdam, L. P., M. A. O'Hanlan, R. Bluestone, and C. M. Pearson, 1976. "Relapsing polychondritis: prospective study of 23 patients and a review of the literature," *Medicine*, vol. 55, no. 3, pp. 193-215.
- Miller ML. 2007. Miscellaneous condition associated with arthritis. In: Behrman RE, Kliegman RM, Jenson HB, *et al* (eds). *Nelson textbook of pediatrics*. 18th ed. Philadelphia; Saunders. Pp: 1051-2.
- Papo T, Piette JC, Le Thi Huong Du, Godeau P, Meyer O, Kahn MF, Bourgeois P. 1993. Antineutrophil cytoplasmic antibodies in polychondritis. *Ann Rheum Dis.*, 52:384-385.
- Rapini, R.P. and Warner, N.B. 2006. Relapsing polychondritis. *Clinics in Dermatology*, 24, 482-485.
- Schina M, Karsaliakos P, Apostolou T, Mousoulis G. 2008. Relapsing polychondritis as a secondary phenomenon of primary systemic vasculitis. *Clin Nephrol.*, 446-449.
- Sharma, A, Gnanpandithan, K. Sharma, k. and Sharma, S. 2013. Relapsing Polychondritis: A Review. *Clinical Rheumatology*, 32, 1575-1583.
- Yang CL, Brinckmann J, Rui HF, *et al.* 1993. Auto antibodies to cartilage collagens in relapsing polychondritis. *Arch Dermatol Res.*, 285(5): 245-9.
