



RESEARCH ARTICLE

MODIFIED VERHOEFF'S TECHNIQUE FOR STAINING OF ELASTIC FIBERS

^{*,1}Mr. Ziyad Mudasir and ²Mr. Ahmed Ibn Edriss, M.

¹B.Sc of Medical Laboratory Science Histopathology, Sudan

²B.Sc University of Gezira, MSc Sudan University of Science & Technology, Sudan

ARTICLE INFO

Article History:

Received 20th February, 2017
Received in revised form
21st March, 2017
Accepted 24th April, 2017
Published online 23rd May, 2017

Key words:

Modified,
Verhoeff's,
Elastic fibers.

ABSTRACT

Introduction: Reliable identification of elastic fibers structures in light microscopy can be altered by several diseases which cause changes in elastic tissues, such diseases are ageing and atrophy caused by arteriosclerotic changes.

Numerous empirical methods for elastic fibers displaying were evolved and modified along based on chemical structure of the elastic tissues components

A number of techniques can be applied for elastic fibers demonstration these techniques can stain the fibers intensely but sometimes being unrelated.

Study design: This is an experimental descriptive study conducted in White Nile State (Sudan), at University of El-Imam El-Mahdi (Kosti) from 27th April 2017 to 14th June 2017.

Methodology: Twenty arterial biopsies were taken from a rabbit after anesthesia. All biopsies were 1 × 1 × 0.3 cm in dimension. After the specimens were collected, all of them were immediately fixed in a wide suitable container by 10% neutral buffered formalin ten times the size of specimen for 48 h.

After fixation of specimens, the cut-up was done, specimens were put in cassettes then bearded the unique cases number. The specimen then passed into a tissue processing machine (Leica, 2000) for further treatment in Table 1. After tissue processing was completed the blocks containing the specimen was thereafter subjected to routine section cutting. 20 blocks were prepared. The blocks were cooled to solidify to turn out their moulds and were then cut by rotary microtome (Diaphat Galileo, fully automatic microtome Galileo, 2012). 10 sections of 5 μm thickness were sectioned from each block. 100 tissue section were stained by original Verhoeff's Van Geison method as control and the remaining 100 tissue sections were stained by modified Verhoeff's method.

Results: Elastic fibers were stained brown in a yellow background by modified Verhoeff's method.

Conclusion: Modified Verhoeff's method is easy to perform in a few steps (no need for removing of iodine pigment). The differentiation step can be carried out even by less experienced person and give good results.

Copyright©2017, Ziyad Mudasir and Ahmed Ibn Edriss. This is an open access article distributed under the Creative Commons Attribution License, which permits unrestricted use, distribution, and reproduction in any medium, provided the original work is properly cited.

Citation: Mr. Ziyad Mudasir and Mr. Ahmed Ibn Edriss, M. 2017. "Modified verhoeff's technique for staining of elastic fibers", *International Journal of Current Research*, 9, (05), 50881-50883.

INTRODUCTION

Supporting tissues occur in many different forms with diverse physical properties (Young and Heath, 2000). Elastic tissues with its numerous components such as elastin protein, elastic fiber microfibrillar protein (EFMP) and several types of glycol proteins makes a special kind of binding fibers (Jacob and Seances, 1990; Sakai *et al.*, 1986) Reliable identification of these structures in light microscopy can be altered by several diseases which cause changes in elastic tissues, such diseases are ageing and atrophy caused by arteriosclerotic changes (Rustin *et al.*, 1989). Numerous empirical methods for elastic fibers displaying were evolved and modified along based on chemical structure of the elastic tissues components. A number of techniques can be applied for elastic fibers demonstration

these techniques can stain the fibers intensely but sometimes being unrelated. Such techniques are H&E, hematoxylinphloxine- saffron, Congo red, periodic acid-Schiff (PAS), Verhoeff'shematoxylin, resorcin-fuchsin, aldehyde fuchsin, Taenzer-Unna orcein, etc (Bancroft and Gamble, 2002). Most other attempts for establishing a new methods for dyeing elastic tissues are in fact a modifications of basic established techniques and still only more or less applicable attempts (Gomori, 1950; Disbrey and Rack, 1970; Musto, 1981; Garvwey, 1984; Žarkov and Lunjkov, 1990). The critical point with most mentioned methods is differentiation (removal of the excessive stain from the section) in which the experience of the researcher plays the major role besides his subjective evaluation of the obtained results. For these reasons still there is a need for new methods of elastic fibers dyeing which would decrease or eliminate as much as possible difficulties in the previous established techniques, regardless of the type and

*Corresponding author: Mr. Ziyad Mudasir,
B.Sc of Medical Laboratory Science Histopathology, Sudan.

position of elastic tissues in the body and provide accurate results of showing the structure, number and net of elastic fibers.

MATERIALS AND METHODS

Study design

This is an experimental descriptive study conducted in White Nile State (Sudan), at University of El-Imam El-Mahdi (Kosti) from 27th April 2017 to 14th June 2017.

Method

Twenty arterial biopsies were taken from a rabbit after anesthesia. All biopsies were 1 × 1 × 0.3 cm in dimension. After the specimens were collected, all of them were immediately fixed in a wide suitable container by 10% neutral buffered formalin ten times the size of specimen for 48 h. After fixation of specimens, the cut-up was done, specimens were put in cassettes then bearded the unique cases number. The specimen then passed into a tissue processing machine (Leica, 2000) for further treatment in Table 1.

Table 1. Tissue processing schedule

10% buffered formalin	2 hours
70 percent alcohol	3 hours
90 percent alcohol	3 hours
Absolute alcohol	1 hours
Absolute alcohol	1 hours
Absolute alcohol	2 hours
Absolute alcohol	2 hours
Xylene	2 hours
Xylene	2 hours
Wax path	3 hours
Wax path	3 hours

After tissue processing was completed the blocks containing the specimen was thereafter subjected to routine section cutting. 20 blocks were prepared. The blocks were cooled to solidify to turn out their moulds and were then cut by rotary microtome (Diapath Galileo, fully automatic microtome Galileo, 2012). 10 sections of 5 µm thickness were sectioned from each block. (Edriss, 2015)

Staining

All sections were de-waxed by xylene for 10 min and rehydrated in descending alcohol concentrations of 100% through 90 and 70% to distilled water for 3 min in each stage. Each section was stained separately. 100 section were stained by original Verhoeff's method as control and the remaining 100 section were stained by the modified method.

Verhoeff's Van Geison's method

1. Verhoeff's solution (freshly prepared) for 20 minutes.
2. Rinse in water.
3. Differentiate in 2% aqueous ferric chloride until elastic tissue fibers appear black on a gray background.
4. Rinse in water.
5. Rinse in 95% alcohol to remove any staining due to iodine alone.
6. Counter stain in van gieson for 3 to 5 min.
7. Blot to remove excess stain.
8. Dehydrate rapidly through ascending grades of alcohol.
9. Clear in xylene and mount in DPX (Verhoeff's 1908).

Modified Verhoeff's method

Solutions

Periodic acid

Periodic acid	1g
Distilled water	100 ml

Solution a

Hematoxylin	5 g
Absolute alcohol	100 ml

Solution b

Ferric chloride	10 g
Distilled water	100 ml

Verhoeff's solution

Solution a	2.5 ml
Solution b	1 ml

Method

1. Oxidize in periodic acid solution for 5minutes.
2. Stain in Verhoeff's solution for 15-30 minutes.
3. Differentiate in 2% aqueous ferric chloride until elastic tissue fibers appear brown on a gray background.
4. Rinse in water
5. Counter stain as desired (Van Geison or eosin).
6. Blot for excess stain removing.
7. Dehydrate rapidly by rinse in absolute alcohol.
8. Clear in xylene.
9. Mount by DPX.

RESULTS

Elastic fibers were stained brown in a yellow background by modified Verhoeff's method.

Table 2. Elastic fibers staining results by original Verhoeff's Van Geison

Entities	Colure
Elastic fibers	Black
Other tissues	According to counter stain

Table 3. Elastic fibers staining results by modified method

Entities	Colure
Elastic fibers	Brown
Background	Yellow

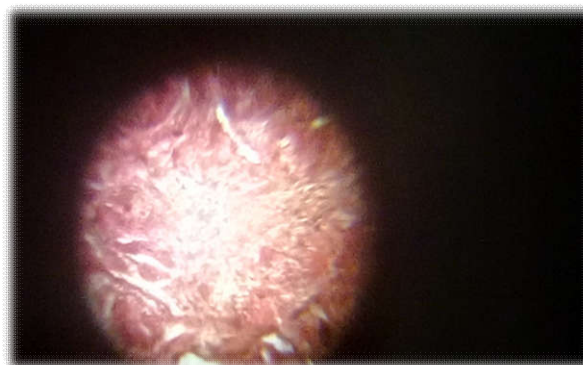


Figure 1. Elastic fibers stains brown

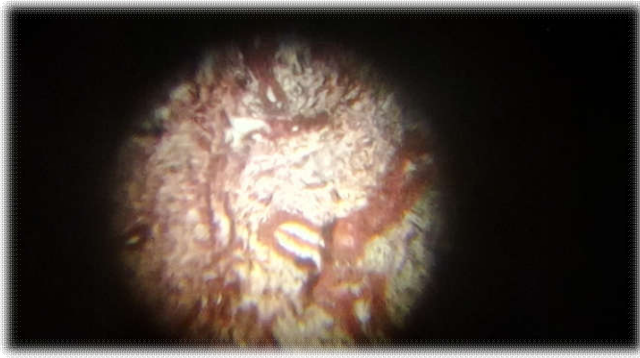

Figure 2. Brown elastic fibers in a yellow background

DISCUSSION

Elastic fibers with its components (elastin and pre-elastin), are highly cross-linked by disulfide bridges. Following oxidative treatment, for instance by iodine as in original Verhoeff's method, these disulfide bridges may be, in part, converted to anionic sulfonic acid derivatives. These derivatives will be strongly basophilic and capable of relatively selective reactions with the basic dye compounds of the above solutions. (Bancroft and Gamble, 2008) Oxidation using iodine will need to additional step to remove the brown pigment which remain in a section following oxidation, such step is rinse in 95% alcohol as stated in original Verhoeff's procedure. In contrast periodic acid is a colure less oxidizing solution and following oxidation the section will not stain by any pigment, although the periodic acid is an iodine in nature. Differentiation step is a critical step and needs for experience to be done in a proper way. (Bancroft and Gamble, 2008) In this modified method differentiation can be carried out easily.

Conclusion

Modified Verhoeff's method is easy to perform in a few steps (no need for removing of iodine pigment). The differentiation step can be carried out even by less experienced person and give good results.

Acknowledgment: First of all we thank Allah for giving us the strength and support to do this work. We are grateful to our *colleagues* at the Department of Histopathology and Cytology for their encouragement and support. Our dissertation would not have been successfully completed if we had not found conducive atmosphere of work. In this connect; gratitude is extended to all *members* of the histopathology laboratory of El-Imam El-Mahdi University for their fruitful cooperation and help.

REFERENCES

- Bancroft J. and Gamble M. 2002. Theory and Practice of Histological Techniques, 5th edition Churchill-Livingstone, London, England.
- Bancroft J. and Gamble M. 2008. Theory and Practice of Histological Techniques, 6th edition Churchill-Livingstone, London, England.
- Disbrey BD. and Rack, JH. 1970. Hystological laboratory methods. Ex SLivingstone. Edinburgh and London.
- Edriss AM. 2015. Lecture notes: routine histological techniques. At <http://www.slideshare.net>.
- Garvwey, W. 1984. Modified elastic tissue-Masson trichrome stain. *Stain Techn.*, 59: 213-6.
- Gomori G. 1950. Aldehyde-fuchsin: a new stain for elastic tissue. *Amer J Clin Path.*, 20: 665-6.
- Jacob MP. and Seances CR. 1990. Elastin: preparation, characterisation, structure, biosynthesis and catabolism. *SocBiolFil*; 187:166-80.
- Musto L. 1981. Improved iron hematoxylin stain for elastic tissue. *Stain Tecno.*, 56: 185-7.
- Rustin MHA, Papadaki L, Rode J, Dowd PM. 1989. Elastic fibers in patients with systemic sclerosis. *Arch. Pathol. Anat.*; 416:115-20.
- Sakai LY, Keene DR, Engvall E. 1986. Fibrilin, a new 350-kD glycoprotein, is a component of extracellular microfibrils. *J Cell Biol.*, 103: 2499-509.
- Young, B. and J.W. Heath 2000. Functional histology, fourth edition, ISSN 04430-56129.
- Žarkov VP. and Lunjkov VD. 1990. Metodika isledovanija: Bistroe gistohimičeskoe okrašivanje gistologičeskih preparatov. *ArhAnatGistolEmbriol.*, 99: 54-5.
