



CASE REPORT

OVERZEALOUS USE OF ELECTROCAUTY FOR GINGIVAL DEPIGMENTATION

1. *Chowdhary Zoya, 2Mohan Ranjana, 3Mehrotra Shalabh and 4Gundappa Mohan

¹Dental Surgeon, Health and Family Welfare Department, Jammu (J&K), India

^{2,3}Department of Periodontology, TMDCRC, Moradabad (U.P), India

⁴Department of Conservative Dentistry and Endodontics, TMDCRC, Moradabad (U.P), India

ARTICLE INFO

Article History:

Received 27th March, 2017

Received in revised form

15th April, 2017

Accepted 14th May, 2017

Published online 20th June, 2017

Key words:

Depigmentation, Electrosurgery, Gingival hyperpigmentation, Osteonecrosis.

Copyright©2017, Chowdhary zoya et al. This is an open access article distributed under the Creative Commons Attribution License, which permits unrestricted use, distribution, and reproduction in any medium, provided the original work is properly cited.

Citation: Chowdhary Zoya, Mohan Ranjana, Mehrotra Shalabh and Gundappa Mohan, 2017. "Overzealous use of electrocauty for gingival depigmentation", *International Journal of Current Research*, 9, (06), 51864-51867.

ABSTRACT

Electrosurgeries are performed routinely in clinical dentistry, and it has a great relevance to general dentists as it provides a bloodless field while performing the gingivectomy, gingivoplasty, crown lengthening, frenectomy, depigmentation etc. But the overzealous use of electrocautery leads to delayed wound healing leading to sometimes necrosis of alveolar bone and gingiva. The present case reports the osteonecrosis of the alveolar bone of the mandible following a careless handling of electrocautery while managing a case of gingival hyperpigmentation.

INTRODUCTION

Electrosurgery is defined as the intentional passage of high-frequency waveforms, or currents, through the tissues of the body to achieve a controllable surgical effect (Osman, 1982). The clinician may use the electrosurgery for cutting and/or coagulating soft tissues by varying the mode of application of the current. High-frequency waveforms when passing through tissues, produce intense heat intracellularly when contacted. The produced heat volatilizes cells and leaves a path of cell destruction as it passes through the tissues in the form of incision/ surface coagulation (Gnanasekhar/Ai-Duwairi, 1998). Electrosurgery device was first developed by William Bovie in 1926 (Preston, 2013) i.e. introduced to the dentistry about 70-80 years back, and has application in all clinical dentistry branches; but was gradually replaced by the Lasers, after their introduction in dentistry. The increased avoidance of electrosurgeries in clinical practice may be due to conflicting reports on the healing of the electrosurgical wound and the avoidance to teach electrosurgeries in dental schools (Gnanasekhar/Ai-Duwairi, 1998). Electrosurgeries require a comprehensive knowledge of the principles and skills, which come with constant practice and the clinician soon find it to be of immense use in clinical dentistry. But on the contrary, if either or any one of the two i.e knowledge and skill is lacking,

the clinician will end up with complications depending upon the procedure undertaken, most common being the underlying tissue necrosis (Osman, 1982; Gnanasekhar/Ai-Duwairi, 1998). The authors here present a very interesting case of osteonecrosis after overzealous used of electrocautery for the management of the gingival hyperpigmentation.

Case report

A 20-year-old female patient came to the Department of Periodontology with a chief complaint of the painful white patch in the lower front gums since 8-9 days. The pain was throbbing, continuous and non-radiating in nature. The past dental history revealed that she had undergone the gingival hyperpigmentation procedure performed by electrocautery in the mandibular anterior region a week ago from a private practitioner. A white patch was noticed by the patient in the region along with tender gums. On general examination, the patient was of normal built and had a normal gait. Intraoral examination revealed an underlying alveolar bone exposure in the mandibular anterior region. The gingival tissue was grayish-white in colour, surrounded by reddish, soft tissue (Figure 1). The lesion was located in the attached gingiva of approximately 3 mm (apico-occlusally), with its margins near the mucogingival line apically and 1mm below the gingival margin occlusally. It extended from the mesial line angle of the left mandibular first premolar to the mesial line angle of the right mandibular first premolar in length. The area of the

*Corresponding author: Chowdhary Zoya,

Dental Surgeon, Health and Family Welfare Department, Jammu (J&K), India.

surgical intervention was sensitive and painful to touch due to exposure of bone. Extra-oral, examination did not reveal any ulceration or swelling. A diagnosis of iatrogenic labial osteonecrosis in the mandibular anterior region was made.

Treatment

Complete extraoral and intraoral mouth disinfection was carried out, and the site was anaesthetized between the first mandibular premolars using local infiltration in the labial vestibule, with Xylocaine 2% with epinephrine 1:80,000. Bleeding was induced around the circumference of the lesion and beyond the mucogingival junction in the alveolar mucosa, with the help of BP blade no. 11. A thin blood clot covered the lesion evenly. The area was then covered with tin foil, over which the periodontal dressing (Coe-pack) was placed. The procedure was repeated every week for one month. The patient was prescribed Diclomol 50mg, Amoxicillin 500mg and Metronidazole 200mg every 8 hourly for 7 days; and Chlorhexidine gluconate mouthwash to be used twice a day for two weeks. The area was healed with uniform healthy gingival except in the region of 33, 34, 43 and 44 (Figure 2). The sequestrum observed with 33, 34, 43 and 44 was removed with the help of a tweezer under topical anaesthesia in the area. The area was cleaned and the periodontal dressing was placed over the wound. The patient was evaluated after a week, the periodontal dressing was removed. The area showed normal hard and soft tissue healing, restoring normal architecture. Intraoral periapical radiographs revealed no interdental bone loss. As the patient was insisting for a depigmentation procedure in the maxillary anterior region, so it was performed. The patient is still on follow-up visits. Both the patient and the clinician were satisfied with the results (Figure 3,4).

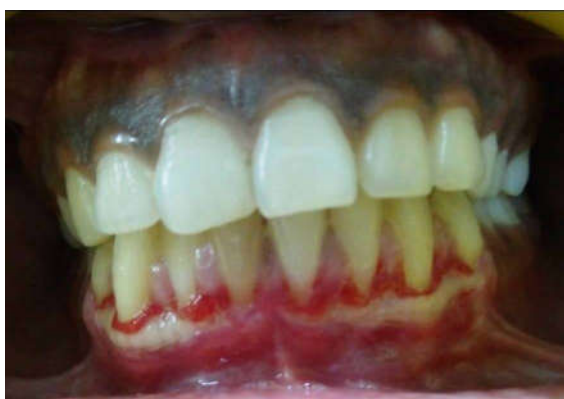

Figure 1. The underlying alveolar bone exposure in the buccal mandibular anterior region

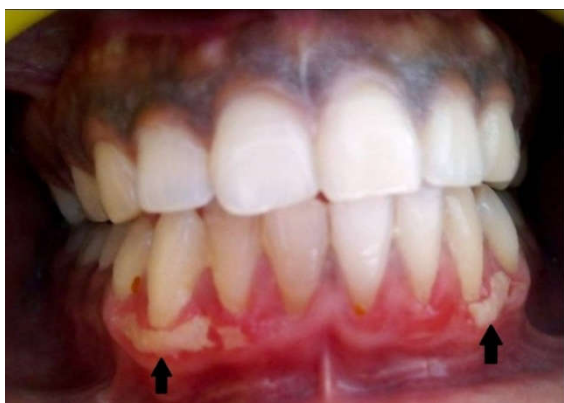

Figure 2. Lesion showed secondary healing eventually, and the formation of sequestrum (black arrows) which was later removed

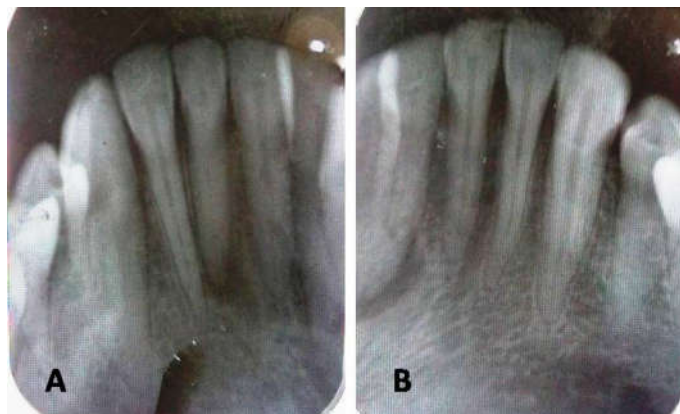


Figure 3. (A) and (B) shows no evidence of any pathology radiographically

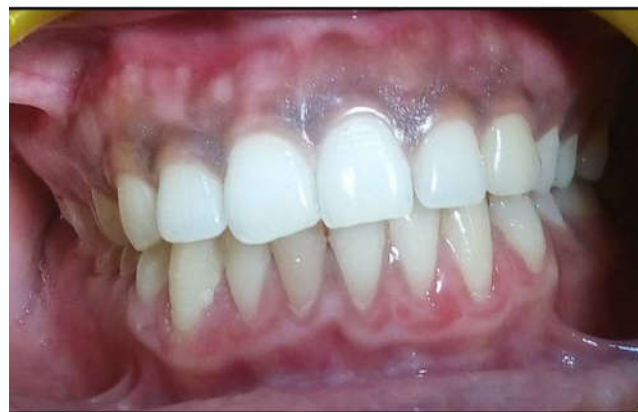

Figure 4. Complete healing of the lesion

DISCUSSION

Gingival depigmentation may be considered as a periodontal plastic procedure where the gingival epithelium along with a layer of underlying connective tissue is surgically removed. The procedure may be performed using various techniques, based on the clinician experience and the individual's preference (Murthy *et al.*, 2012). The various techniques for depigmentation are; scalpel technique (most widely used), cryosurgery, electrosurgery, Laser (Nd:YAG, Er:YAG and CO₂), chemical methods (outdated), masking techniques like free gingival graft, acellular dermal matrix allograft (Sushma *et al.*, 2009; Martin, 2012). Electrosurgeries are not widely used, as they have the limitations of undesired tissue destruction with delayed wound healing. A complete understanding of the electrosurgery unit, as well as its principle, is required. The electrosurgery unit consists of four components; the current generator (produces high-frequency waveforms ranging from 1 to 4 MHz), the active electrode (single-wire electrodes, for incision or excision; loop electrodes, for tissue planing; and heavy, bulkier ball electrodes, for coagulation), the passive electrode (ground plate) and the on-off switch (Osman, 1982). The active electrode tip when comes in contact with the tissue, intense intracellular heat is produced, causing disruption of the cells at the line of the incision and/ coagulation, which also spreads to the adjacent cell layers (Osman, 1982; Gnanasekhar/Ai-Duwairi, 1998). This heat is called Lateral heat, which is responsible for causing coagulation necrosis on the cell layers adjacent to all incision sites. The higher the lateral heat, more will be the tissue necrosis (Osman, 1982). So, the main objective is to produce a minimal amount of lateral heat along with a clean incision and/ or coagulation. This could

be achieved by controlling certain factors, such as; size and type of active electrode; power setting; waveform; cutting time; and surface tissue condition (Louca and Davies, 1992). It has been reported that larger/ thicker electrodes produce more lateral heat and cause more tissue damage than smaller/ thinner electrodes (Noble *et al.*, 1976). The cutting time should be minimum to avoid production of undesired lateral heat, which will further cause undesired tissue necrosis and destruction. The speed of the electrode over the tissue must be guided at 7mm/seconds (Kalkwarf *et al.*, 1987) and an active electrode must not contact the tissue for >2seconds at a time and successive applications at the same spot must have a time interval of 10-15seconds (Kalkwarf *et al.*, 1983b). It should be kept in mind that the surface over which an active electrode is contacted, must be wet/ moist as a dry/ dehydrated surface causes sparking, tissue drag, and delayed healing (Flocken, 1980)

The wavelength choice depends upon; surgical effect required (tissue separation/ hemostasis), and the proximity of the bone to the site. There are three types of waveforms;

1. The fully rectified, filtered waveform (CUT) - good tissue separation and effective hemostasis as heat and tissue destruction is minimal (Ravishankar and Satheesh, 2011).
2. The fully rectified waveform (COAG 1) - least amount of lateral heat with excellent tissue separation, but hemostasis is very little (Gnanasekhar/Ai-Duwairi, 1998). It is of small range in the clinical operation but its effective (Ravishankar and Satheesh, 2011).
3. The partially rectified waveform (COAG 2) - hemostasis only as it produces more lateral heat than other two waveforms (Gnanasekhar/Ai-Duwairi, 1998). It coagulates blood vessels leading to unnecessary coagulative contraction (Ravishankar and Satheesh, 2011).

In the present case report, severe underlying tissue destruction was seen because of the overzealous use of the electrocautery unit. The patient experienced severe pain as the bone was denuded and was devoid of the overlying soft tissue, leading to osteonecrosis of the labial alveolar bone of the mandibular anterior region. The reason for the destruction could be any one or combinations of the reasons above stated. Azzi *et al.* (1985) and Reinhardt *et al.* (1983) in their studies on dogs, revealed that careful, controlled use of the electrocautery within accepted clinical guidelines for the time of exposure and energy production may elicit cellular changes at the alveolar crest, but this reaction is not of clinical significance. But on a contrary, an uncontrolled use with long periods of exposure to the activated electrode/ exposure directly to denuded bone may result in bone necrosis and delayed wound healing, which is evident in this case report. Another cause could be the gingival biotype, which mostly the clinicians miss. According to Muller and Eger (1997) gingival biotypes can be thin i.e. <1.5 mm and thick i.e. ≥ 1.5 mm. A thin biotype is said to have a delicate and thin periodontium, whereas a thick biotype has a thick and heavy periodontium (Shah *et al.*, 2016). Kalkwarf *et al.* (1981 & 1983a) in their study found that following careful controlled electrocautery procedures a small denatured zone, produced by lateral heat is always found adjacent to path of incision and it gradually decreases while healing; but an improperly controlled electrocautery procedure is capable of causing adverse alternations in connective tissue that may delay the healing

response. In the present case report, the patient's gingival biotype was thin i.e. the proximity of the site to the underlying bone was very less and an uncontrolled electrocautery leads to adverse alterations of connective tissue as well as the underlying bone, leading to osteonecrosis of the bone and delayed the healing process. The misuse of electrocautery has reported causing a gingival recession (Ruel *et al.*, 1980; Azzi *et al.*, 1983; DeVitre *et al.*, 1985) or due to the thin gingival biotype (Shah *et al.*, 2016) and/or a combination of both.

Conclusion

The present case of Osteonecrosis due to overzealous use of electrocautery has been reported for the management of gingival hyperpigmentation. The overzealous use of the electrocautery was due to the lack of knowledge and the skill of a clinician about the electrocautery. The gingival biotype is an important factor while working in the mandibular anterior region. Electrocauteries must be used with caution in every aspect of clinical dentistry in order to avoid complications.

REFERENCES

- Azzi, R., Kenney, E.B., Tsao, T.F., Carranza, F.A. 1985. The effect of electrocautery on alveolar bone. *J Periodontol.*, 54:96-100.
- Azzi, R., Tsao, T.F., Carranza, F.A., Kenney, E.B. 1983. Comparative study of gingival retraction methods. *J Prosth Dent.*, 50:561-565.
- DeVitre, R., Galburt, R.B., Maness, W.J. 1985. Biometric comparison of bur and electrocautery retraction methods. *J Prosth Dent.*, 53:179-182.
- Flocken, J.E. 1980. Electrocautery management of soft tissues and restorative dentistry. *Oral Health.*, 70:35-40
- Gnanasekhar/Ai-Duwairi. 1998. Electrocautery in dentistry. *Quintessence Int.*, 29:649-654.
- Kalkwarf, K.L., Krejci, R.F., Edison, A.R., Reinhardt, R.A. 1983b. Subjacent heat production in tissue excision with electrocautery. *J Oral Maxillofac Surg.*, 41:653-657.
- Kalkwarf, K.L., Krejci, R.F., Shaw, D.H., Edison, A.R. 1987. Histologic evaluation of gingival response to an electrocautery blade. *J Oral Maxillofac Surg.*, 45:671-674.
- Kalkwarf, K.L., Krejci, R.R., Wentz, F.M. 1981. Healing of electrocautery incision in gingiva. Early histologic observations in adult men. *J Prosth Dent.*, 46:662-672.
- Kalkwarf, K.L., Krejci, R.R., Wentz, F.M., Edison, A.R. 1983a. Epithelial and connective tissue healing following electrocautery incisions in human gingiva. *J Oral Maxillofac Surg.*, 41:80-85.
- Louca, C., Davies, B. 1992. Electrocautery in restorative dentistry. I. Theory. *Dent Update.*, 19:319-323.
- Muller, H.P., Eger, T. 1997. Gingival phenotypes in young male adults. *J Clin Periodontol.*, 24:65-71
- Murthy, M.B., Kaur, J., Das, R. 2012. Treatment of gingival hyperpigmentation with rotary abrasive, scalpel, and laser techniques: A case series. *J Indian Soc Periodontol.*, 16:614-9.
- Noble, W.H., McClatchey, D.D., Douglas, G.D. 1976. A histological comparison of effects of electrocautery resection using different electrodes. *J Prosth Dent.*, 35:575-579.
- Osman, F.S. 1982. Dental electrocautery: General precautions. *Can Dent Asso J.*, 48:642.
- Preston, L., Carter. 2013. The life and legacy of William T. Bovie. *Am J Sur.*, 205:488-491.

- Ravishankar, P.L., Satheesh, Mannem. 2011. Electrosurgery: A review on its application and biocompatibility on periodontium. *Indian J Dent Adv.*, 3:492-508.
- Reinhardt, R.A., Hardt, A.B., Krejci, R.R., Kalkwarf, K.L. 1983. Histometric evaluation of inter proximal bone responses to electrosurgical mucoperiosteal incisions in dogs. *J Oral Maxillofac Surg.*, 41:807-813.
- Ruel, J., Schuessler, P.J., Malament, K., Mori, D. 1980. Effects of retraction procedures on the periodontium in humans. *J Prosth Dent.*, 44:508-515.
- Shah, R., Sowmya, N.K., Thomas, R., Mehta, D.S. 2016. Periodontal biotype: Basics and clinical considerations. *J Interdiscip Dentistry.*, 6:44-9.
- Sushma, L., Yogesh, D., Marawar, P.P. 2009. Management of gingival hyperpigmentation using surgical blade and diode laser therapy: A comparative study. *J Oral Laser Applications.*, 9:41-7.
