



CASE STUDY

SMILE DESIGNING IN CHILDREN

*¹Kavita Bekal and ²Arjun, M. R.

¹Department of Pedodontics and Preventive Dentistry, Mumbai, India
²Department of Periodontics, Sree Anjaneya Dental College, Kerala, India

ARTICLE INFO

Article History:

Received 10th November, 2016
Received in revised form
28th December, 2016
Accepted 02nd January, 2017
Published online 28th February, 2017

Key words:

Gummy smile, Depigmentation,
Crown lengthening, Esthetic, Children.

Copyright©2017, Kavita Bekal. This is an open access article distributed under the Creative Commons Attribution License, which permits unrestricted use, distribution, and reproduction in any medium, provided the original work is properly cited.

Citation: Kavita Bekal, 2017. "Smile designing in children", *International Journal of Current Research*, 09, (02), 46869-46871.

ABSTRACT

Excessive gingival display and gingival hyperpigmentation are major concerns for a large number of patients visiting the dentist. This problem is aggravated in patients with a gummy smile or excessive gingival display while smiling. This case report represents a simple surgical technique to de-epithelization which has been successfully used to treat gingival hyperpigmentation caused by excessive melanin deposition and crown lengthening procedure in a 14 year old female patient. Highlighting the relevance of an esthetically pleasing smile, especially in smile conscious individuals.

INTRODUCTION

Gingival health and appearance are the essential components of an attractive smile. Melanin pigmentation of the gingiva occurs in all races. (Dummett, 1945; Dummett and Baren, 1971; Dummett, 1979; Amir *et al.*, 1991; Gorsky *et al.*, 1984) Melanin hyperpigmentation usually does not present as a medical problem, but patients may complain their black gums are unaesthetic. Melanin, a brown pigment, is the most common cause of endogenous pigmentation of gingiva and is the most predominant pigmentation of mucosa. (Patsakas *et al.*, 1981; Prinz, 1932; Cicek and Ertas, 2003; Dummett and Baren, 1967; Perlmutter and Tal, 1986) This problem is aggravated in patients with "gummy smile" or excessive gingival display while smiling. (Hoexter, 1999)

Excessive Gingival Display

A conservative display of approximately 2- 3 mm of the marginal gingiva is generally considered as part of the ideal esthetic smile. In contrast excessive gingival display can severely compromise the appearance of the individual. Etiology for excessive gingival display includes vertical maxillary excess, gingival hyperplasia, and altered passive eruption. Excessive gingival display due to gingival enlargement or altered passive eruption can be effectively corrected by a gingivectomy procedure. The first and foremost indication for depigmentation is patient demand for improved

esthetics. Gingival depigmentation is removed or reduced by various technique. The present case report, describes a simple and effective surgical depigmentation technique and Crown lengthening that does not require sophisticated instruments or apparatus yet yields esthetically acceptable results along with patient's satisfaction.

Case Report

A female patient 14 years of age reported with the demand for cosmetic correction of "black gums", "gummy smile" and restoration of fractured anterior teeth (Fig.1). Medical history was non-contributory. On examination, the patient had a very high smile line that revealed the deeply pigmented gingival on the labial surface of both maxillary and mandibular arches and a root canal treated "11" with ellis class II fracture. The color of the gingiva was dark to black. The patient consent was taken. After oral prophylaxis and maintenance of oral hygiene instructions the surgical procedure was carried out under local anesthetic infiltration. Crown lengthening by external bevel gingivectomy was completed initially. The cemento-enamel junction was determined by careful probing around three points on the labial and lingual surface of each tooth. Pocket marking was done on the external surface of the gingiva corresponding to the cemento-enamel junction using pocket markers (Fig.2). The bleeding points on the gingival surface created by the pocket markers were taken as reference points for placing the external bevel incision. The incision was made using a Kirkland knife from the attached gingiva to a level just apical to the pocket markings (Fig.3a 3b).

*Corresponding author: Kavita Bekal,
Department of Pedodontics and Preventive Dentistry, Mumbai, India.

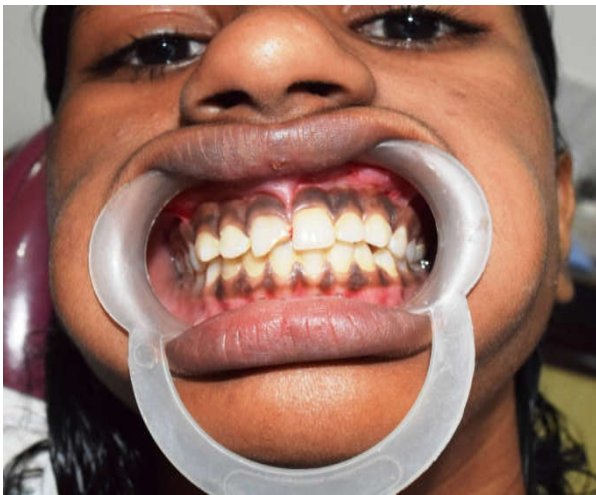

Figure 1. Intra oral pre operative view demonstrating hyperpigmented gingival and short clinical crowns of upper and lower anterior teeth with fractured 11

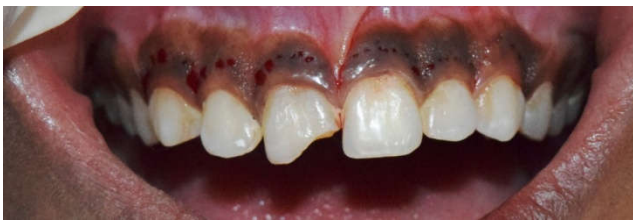

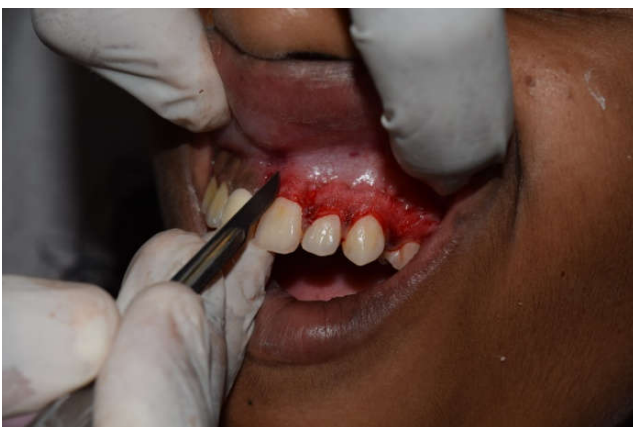
Figure 2. Pocket marking was done

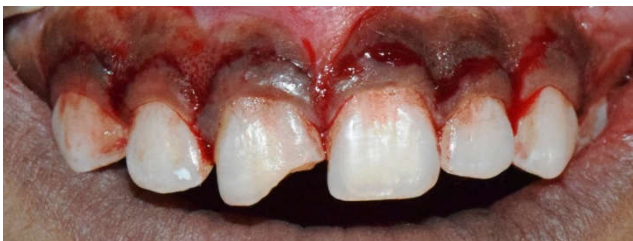

Figure 3. a) incision was made using a Kirkland knife

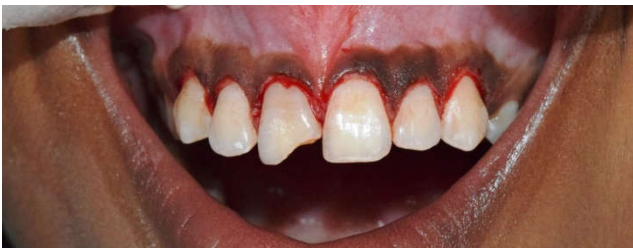

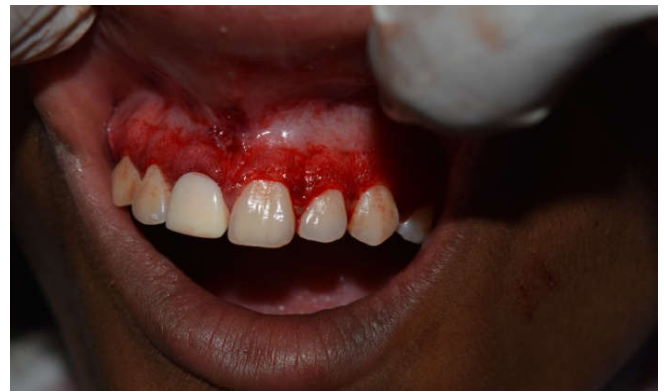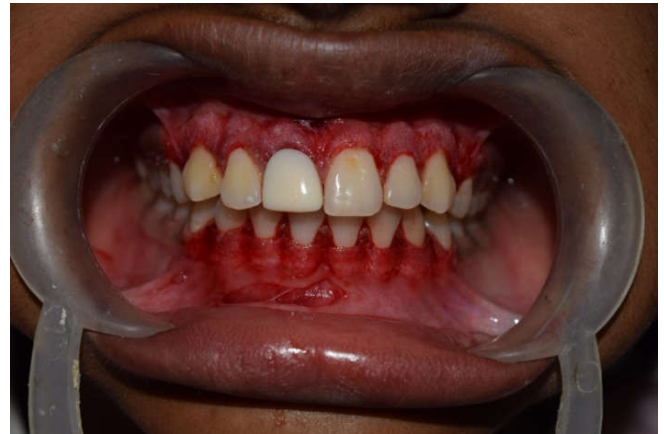Figure 3. b) gingival tissue removed



a)



b)



c)

Figure 4. Depigmentation done

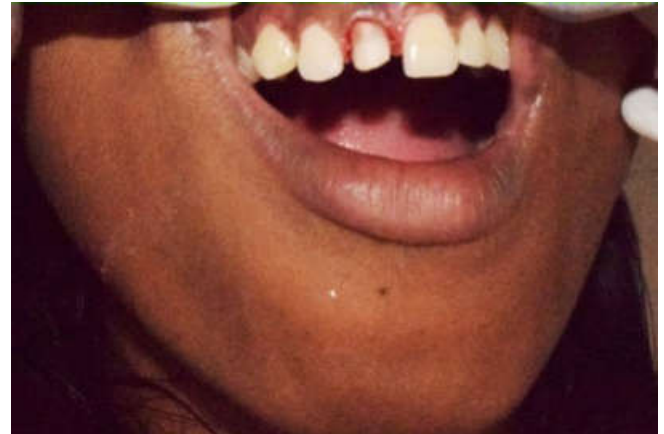

Figure 5. a) Crown preparation done

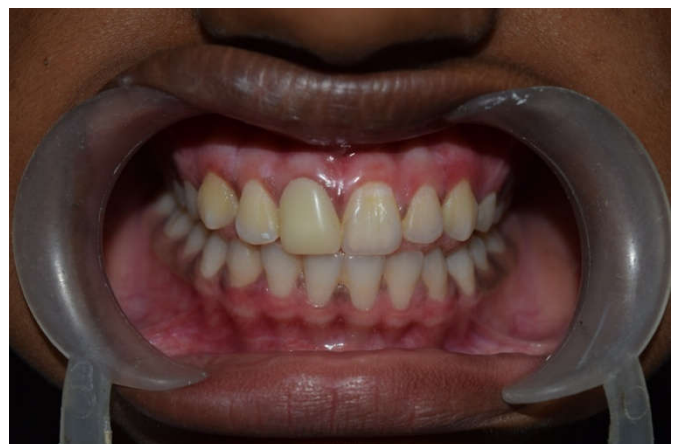



Fig 6. Nine months post op

An Orban interdental knife was used for interproximal incisions and the strip of excess gingival tissue was removed. The gingivectomy was followed by the depigmentation procedure. Using a number 11 brad parker blade, the entire pigmented epithelium along with a thin layer of connective tissue (split thickness flap) was removed (Fig.4). This incision was carried out from the apical level of external bevel incision to the apical end of the attached gingiva (mucogingival junction) up to where the pigmentation extended. Hemostasis was obtained with sterile gauze and direct pressure. The surgical wound was protected by a periodontal dressing for the immediate two-week postoperative period. The dressing may also prevent excessive granulation tissue formation during healing. Post operative analgesics and antibiotics were prescribed. Amoxicillin 500 mg thrice daily was prescribed for five days and ibuprofen thrice daily for two days was used as analgesic. The patient was advised to use chlorhexidine mouthwashes for the immediate two weeks postoperative period to aid in plaque control. Crown cutting was done in relation to upper left maxillary central incisor was done intermediately, it was temporized and replaced with acrylic crown. (Fig. 4) The area healed well after two weeks. Pigmentation was absent from the newly formed epithelium and it appeared red after 9 months. Upon final healing, the gingiva appeared pale pink, which was very satisfactory for the patient. (Fig. 5,6)

DISCUSSION

In the present case, repigmentation was not observed during a short follow up period (9 month). However, long-term observation are required to determine the efficacy of depigmentation in children. In future, even if gingival repigmentation occurs in this patient, the same procedure could be repeated in the same region. The timing of doing depigmentation procedure in children is not clear in the literature.

But growing children are more conscious about their dental esthetic appearance and that of the other children. Scalpel surgical technique is highly recommended in consideration of the equipment constraints that may not be frequently available in clinics (Almas and Sadig, 2002). It is known that the healing period for scalpel wounds is faster than in other techniques.

Conclusion

Excessive gingival display and gingival hyperpigmentation are major concerns for a large number of patients. Although several techniques are currently in use, the scalpel technique is still the most widely employed. Lasers and cryosurgery may offer less postoperative pain. The external bevel gingivectomy combined with the depigmentation procedure described above offers a practical technique to dramatically improve patient esthetics.

REFERENCES

- Almas K. and Sadig W. 2002. Surgical treatment of melanin-pigmented gingiva; An esthetic approach. *Indian Dent Res.*, 13:70-3.
- Amir E, Gorsky M, Buchner A, *et al.* 1991. Physiologic pigmentation of the oral mucosa in Israeli children. *Oral Surg Oral Med Oral Pathol.*, Mar;71(3):396-8.
- Cicek Y. and Ertas U. 2003. The normal and pathological pigmentation of oral mucous membrane: a review. *Contemp Dent Pract*, Aug 15;4(3):76-86.
- Dummet CO. and Barends G. 1971. Oromucosal pigmentation: an updated literary review. *J Periodontol.*, Nov;42(11):726-36. Review.
- Dummett CO. 1945. Clinical observation on pigment variations in healthy oral tissues in the Negro. *J Dent Res.*, 24:7-13.
- Dummett CO. 1979. Oral tissue color changes (I). *Quintessence Int.*, Nov;10(11):39-45.
- Dummett CO. and Barends G. 1967. Pigmentation of the oral tissues: A review of the literature. *J Periodontol.*, 38:369-78.
- Gorsky M, Buchner A, Fundoianu-Dayana D, *et al.* 1984. Physiologic pigmentation of the gingiva in Israeli Jews of different ethnic origin. *Oral Surg Oral Med Oral Pathol.*, Oct;58(4):506-9.
- Hoexter DL. 1999. Periodontal aesthetics to enhance a smile. *Dent Today*, 18(5): 78-81.
- Patsakas A, Demetriou N, Angelopoulos A. 1981. Melanin pigmentation and inflammation in human gingiva. *J Periodontol.*, Nov;52(11):701-4.
- Perlmutter S. and Tal H. 1986. Repigmentation of the gingiva following surgical injury. *J Periodontol.*, Jan;57(1):48-50.
- Prinz H. 1932. Pigmentation of the oral mucous membrane. *Dental Cosmos*. 72:554-561.
