



## CASE STUDY

### RETENTIVE AIDS IN AURICULAR PROSTHESIS

**\*Dr. Manikya Shastri, Dr. Sunil Dhaded and Dr. Subashani**

Ames Dental college, Raichur, India

#### ARTICLE INFO

##### Article History:

Received 14<sup>th</sup> October, 2016  
Received in revised form  
24<sup>th</sup> November, 2016  
Accepted 19<sup>th</sup> December, 2016  
Published online 31<sup>st</sup> January, 2017

##### Key words:

Retentive aid, Spectacles, Splint,  
Magnets, Adhesives.

Copyright©2017, Dr. Manikya Shastri and Dr. Sunil Dhaded. This is an open access article distributed under the Creative Commons Attribution License, which permits unrestricted use, distribution, and reproduction in any medium, provided the original work is properly cited.

Citation: Dr. Manikya Shastri and Dr. Sunil Dhaded, 2017. "Retentive aids in auricular prosthesis", *International Journal of Current Research*, 9, (01), 45843-45847.

#### ABSTRACT

Patients with facial defects avoid social contact. The reason behind this may be functional problems or serious psychological problems. Plastic surgery and prosthesis are the treatment option for the patients who are wishing to disguise the absence of all or missing part. The maxillofacial prosthesis constructed by prosthodontists is an alternative treatment when the facial defects cannot be surgically treated. There are various retentive aids to enhance retention. This article gives a brief review on auricular retentive aids which are used to enhance retention.

## INTRODUCTION

Reconstruction of facial defects is the most challenging task for the Prosthodontist and the surgeon. The clinical skill and utilization of available materials are utmost important for replacement of missing parts. Maxillofacial prosthetics is defined as that branch of prosthodontics concerned with restoration and/or replacement of the stomatognathic and craniofacial structures with prosthesis that may or may not be removed on a regular or elective basis. The defects may be congenital or developmental or acquired. (Deba *et al.*, 2012)

#### Classifications

All craniofacial anomalies may be classified into five categories based on etiology, anatomy and current treatment principles

1. Clefts-centric, acentric
2. Synostoses-symmetric, asymmetric
3. Atrophy-hypoplasia
4. Neoplasia-hyperplasia
5. Unclassified. (Whitaker *et al.*, 1981)

The absence of auricles is the second most common craniofacial malformation after cleft lip and palate. A clinical classification of auricular defects set forth by Tanzer in 1977 consists of five categories. These groups include: 1. anotia

2. Complete hypoplasia (microtia): with atresia of the external auditory canal without atresia of the external auditory canal
3. hypoplasia of the middle third of the auricle
4. hypoplasia of the superior third of the auricle constricted ear (cup and lop)
5. cryptotia, hypoplasia of entire superior third
6. Prominent ear. (Smith and Bumsted, 1993)

Classification of congenital abnormalities of the ear is as follows

1. Complete absence of the external auricle and meatus with or without development of the inner and middle ear.
2. Absence of the external auricle-complete or incomplete.
3. Ectopic ear. It is usually small, tilted and displaced downwards and forwards.
4. Supernumerary tags, usually in front of or below the ear or on a line from the tragus to the angle of the mouth.
5. Preauricular sinus
6. Prominent ears.
7. Faun ear or incomplete folding of the helix or outer rim of the ear.
8. Abnormally small ears.
9. Abnormally large ears.
10. Asymmetry, one ear being normal and the other either larger or smaller.
11. Large lobule.
12. Adherent lobule

The most common congenital auricular defect is microtia. It is the congenital deformity of the pinna. Which can be unilateral or bilateral. (Ramachandran and Singh, 2012)

Acquired auricular defects are divided into

1. Cutaneous defects
2. Composite defects –marginal, nonmarginal
3. Near-total or total auricular defects–surrounding tissue intact, surrounding tissues compromised.

### Causes

Trauma resection, congenital malformations, trauma, inflammation and burn injuries are the common causes of auricular defects. (Nanda *et al.*, 2012) The success of auricular restoration depends on various retentive aids. Extra oral retention can be 1. Anatomical 2. Mechanical. The anatomical undercuts can be either obtained from hard or soft tissues. The mechanical retentive aids for auricular defects can be obtained either from magnets, adhesives, implants, spectacles, pressure clips, ear splint, hair band, hader bar, buttons. (Yeshwante *et al.*, 2014)

### Magnets

Is used as an aid in retention utilizing both attractive and repulsive properties (Figure-1). They can be classified i. based on alloys used a) cobalt containing ex. alnico, b) cobalt free alloys ex. samarium-iron-nitride. ii. based on surface coating: a) coated b) uncoated iii. based on type of magnetism: a) repulsion b) attraction iv. based on arrangement of poles –a) reverse pole b) non reverse pole v. based on type of magnetic system –open and closed.

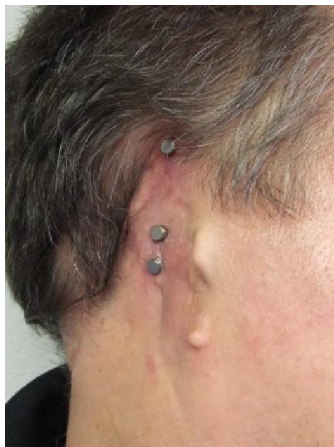

Figure 1. Magnets

Indications: a) inpatients with poor digital dexterity. b) in areas of high muscle activity adjacent to the prosthesis. C) in case of moderate muscle activity combined with rigid prosthesis. The disadvantages are low corrosion resistance and high cost. (Makihara *et al.*, 2008)

### Adhesives

The adhesive aids in retention, marginal seal, border adaptation and prevents the prosthesis from repeated and accidental dislodgment. (Yeshwante *et al.*, 2014) The adhesives used should be biocompatible and should not react with skin subjected to surgical trauma and irradiation. Thin and friable skin or skin that is irradiated is not suitable for repeated application of adhesive. The various adhesives are acrylic adhesives, silicone adhesive, pressure sensitive tape, combination of adhesives.

### Acrylic resin adhesive

Acrylic resin adhesive consists of acrylic resin dispersed in a water solvent, which when evaporates leaves rubber like substance. The examples are pro-aide adhesive (Figure-2), epithane -3 adhesive (Figure-3).

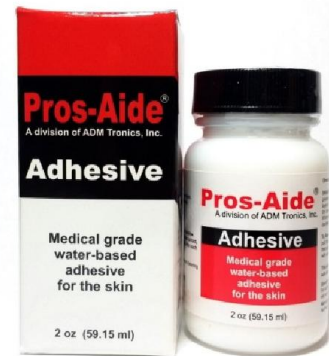

Figure 2. Prosaide Adhesive

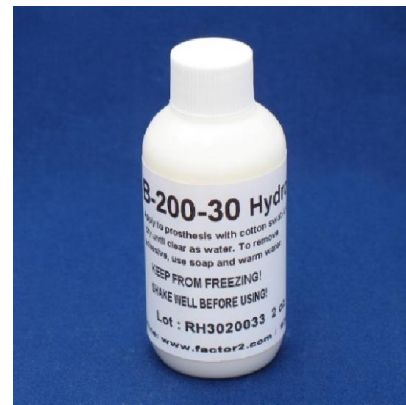


Figure 3. Epithane -3 Adhesive

Silicone adhesives: are room temperature vulcanizing silicone dissolved in a solvent. Only a tacky adhesive results after the solvent evaporates. These adhesives develop good resistance to moisture with low water absorption. The examples are Hollister medical adhesive (Figure-4) and secure medical adhesive (Figure-5).



Figure 4. Hollister Medical adhesive

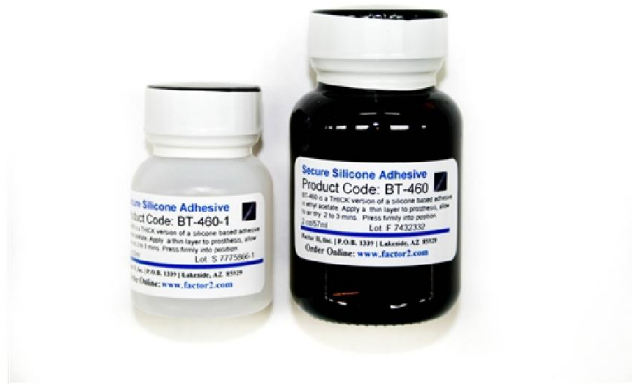

Figure 5. Secure Medical Adhesive

Pressure sensitive tape: consist of backing strip composed of cloth, paper, film, foil or laminate strip coated with pressure sensitive adhesive. It can be used only in patients whose defect demonstrate little or no movement. The examples are 3M-bifaceis (Figure-6 & 7)



Figure 6 & 7. 3M Bifaceis

Combination of adhesives: to overcome the limitation of one adhesive system it is combined with another adhesive system but good adhesive bond should exit between the prosthesis and skin. The examples are 1) epithane adhesive and silicone adhesive. 2) Biface tape and liquid adhesive.

**Spectacles to retain extra oral prosthesis**

It can be used as one of the retentive aid for auricular prosthesis (Figure-8). And mostly preferred for patients who are using

spectacles for visionpurpose. Plain glasses if the patient has no eye side effect. (Banerjee, 2012)

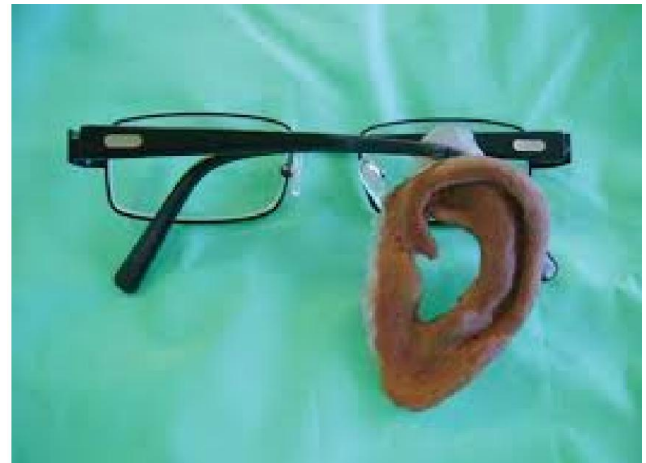






Figure 8. Spectacle retained auricular prosthesis

**Pressure clips**

Are made of polymethylmethacrylate and aesthetics can be enhanced by coloration. (Chugh *et al.*, 2013) The various pressure devices are u-loop pressure clip, spring loaded pressure devices, bent spring pressure earring. The pressure clips are used for the management of ear lobe keloid. These devices has been established as pressure therapy and as a effective option to reduce the amount of scar tissue. (Agrawal *et al.*, 1998) The pressure therapy accelerates the remodelling process and results in early maturation and flattening of scar (Table-1). Constant pressure of only 25mmHg (Chrisostomidis *et al.*, 2008) is required as excessive and prolonged pressure could result in circulatory disturbance and pressure ulcers. Hence pressure clips can be used as a retentive aid in auricle prosthesis.

Table 1. Values of pressure applied by various clips and after deduction of 20% error. (Sasidharan *et al.*, 2015)

Types of pressure clips		Pressure	Pressure after 20% error correction
Spring clips 1		25-35 mm of Hg	20-28 mm of Hg
Spring clips 2		30-40 mm of Hg	24-32 mm of Hg
Spring clips 3		35-50 mm of Hg	28-40 mm of Hg
Binder clips		55-70 mm of Hg	44-56 mm of Hg
Magnetic discs (10 mm 12 mm)		30 mm of Hg 40 mm of Hg	24 mm of Hg and 32 mm of Hg

**Splints**

The heat cure acrylic based splints can also be as a retentive aid (Figure-9). The splint can be aesthetically made by adding extrinsic stains and matching close to patients skin tone. (Krishnan *et al.*, ?)

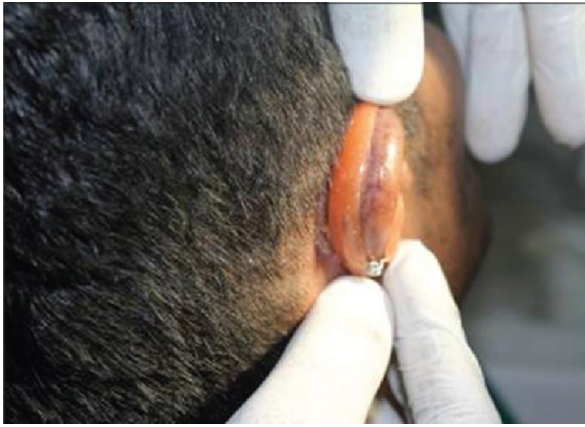

Figure 9. Splints

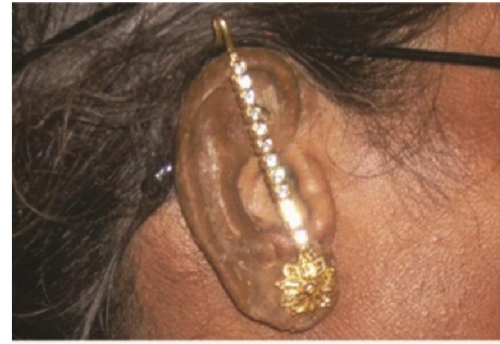

Figure 12. Ornaments retained auricular prosthesis

### Implants

Retention of the prosthesis can be achieved by implants (Figure-10). Size, position and orientation of the implant retained prosthesis must be considered and must be properly planned. (Nanda *et al.*, 2012) The location of implant should be at 2 o'clock and 4 o'clock position on the left hand side and at 8 o'clock and 10 o'clock position on right hand side. The distance of 10-12mm must be between two fixtures. Three fixtures are recommended if the distance is greater than 12mm between two fixtures. Implant retained auricular prosthesis can also be fabricated using a hader bar with two ERA attachments (Figure-11). (Shrestha *et al.*, 2015)

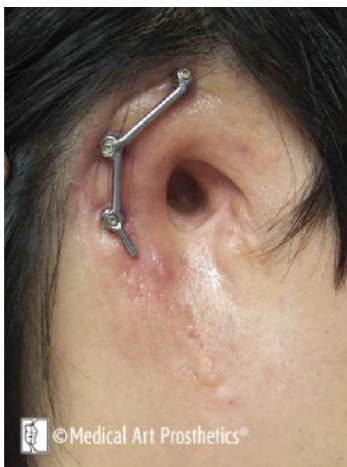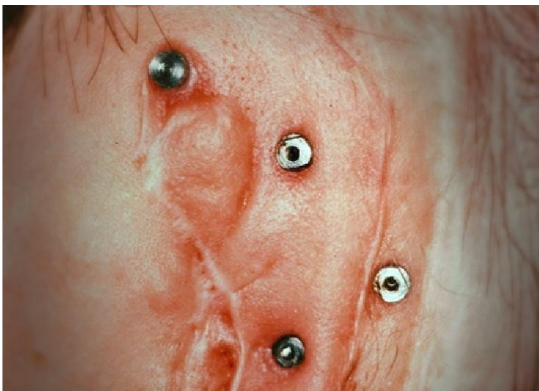


Figure 10 & 11. Implant retained auricular prosthesis

Buttons, headbands ornaments like ear rings (Figure-12) can also be used as a retentive aid for auricular prosthesis. (Kumar *et al.*, 2014)

20-40 % of children with microtia/anotia will have additional defects that could suggest a syndrome

- 1) Teacher collins syndrome
- 2) Goldenhar syndrome.
- 3) Hemifacialmicrosomia.

### Conclusion

The ultimate aim of any maxillofacial rehabilitation should be satisfy the need and expectations of the patient with best possible mode of treatment. Successful prosthesis include aesthetic acceptability, biocompatibility, functional performance, retention longevity and lack of morbidity. Prosthetic rehabilitation of auricular defects serve as a successful alternative treatment option to surgical reconstruction and can also be a redeem to patient desire.

### REFERENCES

- Agrawal K, Panda KN, Arumugam A. 1998. An inexpensive self fabricated pressure clip for the ear lobe. *Br J Plast Surg.*, 51:122-3.
- Banerjee S. 2012. Prosthodontics. *Clinical Dentistry* (0974-3979). Nov 1;6(11).
- Chrisostomidis C, Konofaos P, Chrisotomidis G, Vasilopoulou A, Dimitroulis D, Frangoulis M, *et al.* 2008. Management of external ear keloids using form-pressure therapy. *Clin Exp Dermatol.*, 33:273-5.
- Chugh A, Hooda A, Bishnoi P. 2013. Custom-made different designs of pressure clips for the management of ear lobe keloids. *Dental Hypotheses*, Oct 1;4(4):135.
- Deba K, Yunus N, Tamrakar AK. 2012. Oral & Maxillofacial Prosthetics-I Objectives & History. *Healthtalk.*, 4(5):18-20.
- Krishnan CJ, Balaji SM, Jain AR. A simple ear splint for microtia patients. Missing year, Vol. no., Issue no. & Page no.
- Kumar P, Shubha J, Sowjanya P, Shalini BN, Jesudass G. 2014. An Silicone Auricular Prosthesis Along with Retentive Aids-A Case Report. *Journal of Clinical and Diagnostic Research: JCDR*, Aug;8(8):ZD18.
- Makihara E, Masumi SI, Arita M, Kurogi T. 2008. Clinical Application of Magnetic Attachment for Retention and Connection of Maxillofacial Prostheses to an Intraoral Prosthesis. *Prosthodontic research & practice*, 7(1):60-3.
- Nanda A, Jain V, Kabra SK. 2012. Avenues for rehabilitation of auricular defects. *Indian Journal of Dental Research*, Jan 1;23(1):87.
- Ramachandran S. and Singh Z. 2012. Management Of Microtia In A Low Resource Set Up. *Indian Journal of Dental Sciences*, Jun 1;2(4):51-3.

- Sasidharan A, David A, Gohil A, Gupta AK. 2015. Simple device to determine the pressure applied by pressure clips for the treatment of earlobe keloids. *Indian Journal of Plastic Surgery: official publication of the Association of Plastic Surgeons of India*. Sep;48(3):293.
- Shrestha B, Fatmasari F, Thaworanunta S, Srithavaj T. 2015. Prosthodontic Rehabilitation of Congenital Auricular Defect: A Clinical Report. *The Cleft Palate-Craniofacial Journal*, Mar; 52(2):229-33.
- Smith JD, Bumsted RM, editors. 1993. *Pediatric facial plastic and Reconstructive Surgery*. Raven Press; Jun 1.
- Whitaker LA, Pashayan H, Reichman J. 1981. A proposed new classification of craniofacial anomalies. *Cleft Palate J.*, Jul;18(3):161-76.
- Yeshwante B, Patil SJ, Baig N. 2014. Retentive aids in Maxillofacial prosthesis. *International Journal of Clinical Dental Science*, Nov 23;5(2).

\*\*\*\*\*