



ISSN: 0975-833X

RESEARCH ARTICLE

PREDICTION OF MAXILLARY LATERAL-INCISOR ROOT RESORPTION OF POTENTIALLY IMPACTED CANINE USING SECTOR ANALYSIS

*Remmiya Mary Varghese and Dr. Aravind Kumar, S.

Saveetha Dental College and Hospitals, India

ARTICLE INFO

Article History:

Received 27th October, 2016
Received in revised form
15th November, 2016
Accepted 12th December, 2016
Published online 31st January, 2017

Key words:

Root Resorption,
Canine Impaction,
Opg, Sector Analysis.

ABSTRACT

Aim: To Predict the Maxillary Lateral-Incisor Root Resorption of Potentially Impacted Canine Using Sector Analysis

Material and Methods: OPG of 20 patients were included in the study. All patients had fully erupted maxillary permanent lateral incisors adjacent to the impacted canines. Each impacted canine was assigned to sector I-IV according to Lindauer and colleagues.

Results: In our study, none of the 10 impacted canines in sectors I and II had adjacent lateral incisors with any root resorption. Of the three canines in sector III, however, one had adjacent lateral incisors with root resorption; of the 7 canines in sector IV, 3 had adjacent lateral incisors evidencing root resorption.

Conclusion: It can be concluded that the more severe the impaction of a canine, the more likely it is that the adjacent lateral incisor will show some level of root resorption.

Copyright©2017, Remmiya Mary Varghese and Aravind Kumar. This is an open access article distributed under the Creative Commons Attribution License, which permits unrestricted use, distribution, and reproduction in any medium, provided the original work is properly cited.

Citation: Remmiya Mary Varghese and Dr. Aravind Kumar, S., 2017. "Prediction of Maxillary Lateral-Incisor Root Resorption of Potentially Impacted Canine Using Sector Analysis", *International Journal of Current Research*, 9, (01), 45786-45787.

INTRODUCTION

Maxillary canine palatal impaction occurs in 1 of 100 people. Bishara reported that incidence of maxillary canine impaction ranges between 1% and 3% of patients. Patients with canine impactions experience longer treatment times than those without impactions, depending on displacement of the tooth from the occlusal plane. Maxillary canine impaction is complex in its etiology, localization, response to preventive treatments, and prediction. Root resorption is not only the most common sequela of canine impaction but the most difficult to treat. Although the maxillary lateral-incisor root is the most commonly affected by ectopic eruption of the canine, there is also evidence that impacted canines can cause root resorption of the central incisors.

MATERIAL AND METHODS

Records were collected from 20 patients who were screened for unilaterally or bilaterally impacted maxillary canines. In this study, we used OPG to determine whether maxillary lateral-incisor root resorption can be predicted using a conventional panoramic radiograph and sector analysis. All patients had fully erupted maxillary permanent lateral incisors adjacent to the impacted canines. Each impacted canine was assigned to sector I-IV according to Lindauer and colleagues.

- **Sector I**—cusp tip distal to a line tangent to the distal heights of contour of the lateral incisor crown and root.

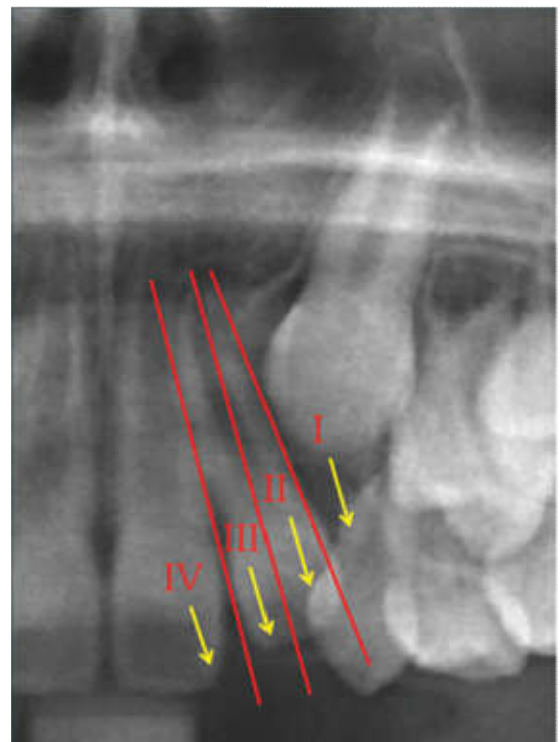


Figure 1. Levels of impaction indicated by sector analysis

- **Sector II**—mesial to sector I, with the cusp tip distal to a line bisecting the mesiodistal dimension of the lateral incisor along the long axis.
- **Sector III**—mesial to sector II, with the cusp tip distal to a line tangent to the mesial heights of contour of the lateral incisor crown and root.
- **Sector IV**—any position mesial to sector III

RESULTS

The basic results are presented in Table. Compared to sector IV, the odds of sector I and II canines causing lateral root resorption were extremely small.

Table 1. Evidence of root resorption using sector analysis

Sector	Total teeth	Teeth showing resorption	Teeth showing no resorption
I	7	0	7
II	3	0	3
III	3	1	2
IV	7	3	4
TOTAL	20	4	16

DISCUSSION

A pretreatment diagnosis of root resorption can drastically alter a treatment plan. It can be concluded that the more severe the impaction of a canine, the more likely it is that the adjacent lateral incisor will show some level of root resorption. In our study, none of the 10 impacted canines in sectors I and II had adjacent lateral incisors with any root resorption. Of the three canines in sector III, however, one had adjacent lateral incisors with root resorption; of the 7 canines in sector IV, 3 had adjacent lateral incisors evidencing root resorption. Even more important, the sector position of an unerupted canine can help determine its potential for impaction. Considering the possibility of higher levels of radiation exposure from the routine use of CBCT, however, it should not be recommended indiscriminately in all cases.

Sector analysis of a panoramic radiograph can guide the practitioner in determining whether CBCT may be indicated when a potentially impacted canine is present.

REFERENCES

- Algerban, A., Jacobs, R., Lambrechts, P., Loozen, G. and Willems, G. 2009. Root resorption of the maxillary lateral incisor caused by impacted canine: A literature review, *Clin. Oral Investig.*, 13:247-255.
- Arens, D.E. 1995. An alternative treatment for severely resorbed maxillary lateral incisor: A sequela of ectopic eruption, *J. Endod.*, 21:95-100.
- Bishara, S.E., Kommer, D.D., McNeil, M.H., Montagano, L.N., Oesterle, L.J. and Youngquist, H.W. 1976. Management of impacted canines, *Am. J. Orthod.*, 69:371-387
- Ericson, S. and Kurol, J. 1987. Radiographic examination of ectopically erupting maxillary canines, *Am. J. Orthod.*, 91:483-492.
- Ferguson, J.W. 1990. Management of the unerupted maxillary canine, *Br. Dent. J.*, 169:11-17.
- Jacoby, H. 1983. The etiology of maxillary canine impactions, *Am. J. Orthod.*, 84:125-132.
- Lindauer, S.J., Rubenstein, L.K., Hang, W.M., Anderson, W.C. and Isaacson, R.J. 1992. Canine impaction identified early with panoramic radiographs, *J. Am. Dent. Assoc.*, 123:91-92.
- Power, S.M. and Short, M.B. 1993. An investigation into the response of palatally displaced canines to the removal of deciduous canines and an assessment of factors contributing to favorable eruption, *Br. J. Orthod.*, 20:215-223.
- Schindel, R.H. and Duffy, S.L. 2007. Maxillary transverse discrepancies and potentially impacted maxillary canines in mixed dentition patients, *Angle Orthod.*, 77:430-435.
- Warford, J.H., Grandhi, R.K. and Tira, D.E. 2003. Prediction of maxillary canine impaction using sectors and angular measurement, *Am. J. Orthod.*, 124:651-655.
