



REVIEW ARTICLE

PRIMARY NEUROENDOCRINE TUMORS OF THE BREAST : A REPORT OF TWO CASES IN 20 YEARS

*¹Razia Bano, ¹Syed Hassan Raza, ²Anam Malick and ²Sajid Mushtaq

¹Surgical Oncology Department- Shaukat Khanum Memorial Cancer Hospital & Research Centre

²Pathology Department- Shaukat Khanum Memorial Cancer Hospital & Research Centre

ARTICLE INFO

Article History:

Received 28th October, 2016

Received in revised form

20th November, 2016

Accepted 20th December, 2016

Published online 31st January, 2017

Key words:

Neuroendocrine, Breast, Chemotherapy.

Copyright©2017, Razia Bano et al. This is an open access article distributed under the Creative Commons Attribution License, which permits unrestricted use, distribution, and reproduction in any medium, provided the original work is properly cited.

Citation: Razia Bano, Syed Hassan Raza, Anam Malick and Sajid Mushtaq, 2017. "Primary Neuroendocrine tumors of the breast : A report of two cases in 20 years", *International Journal of Current Research*, 9, (01), 45458-45460.

ABSTRACT

Primary neuroendocrine tumors of the breast are rare & aggressive tumors of the breast. We report two cases over a period of 20 years. One patient had poorly differentiated neuroendocrine and invasive ductal carcinoma grade 3, whereas the other case had small cell neuroendocrine tumor of the breast.

INTRODUCTION

Neuroendocrine cells are mostly present in gastrointestinal and bronchopulmonary system, therefore neuroendocrine tumors in breast may be the result of differentiation process in breast carcinomas, they constitute about 0.1 % of breast neoplasms (Ogawa *et al.*, 2008). They are common in elderly females in their seventies or eighties, extremely rare in younger females (Zhang and Chen, 2011). We present a review of two cases of primary breast neuroendocrine tumors treated at our institute.

Case 1

First case was registered in 2011, a 66 years female presented with a huge mass in breast, mammogram showed BIRADS category IV (Figure 1), ultrasound confirmed a lesion of 88 mm mass and suspicious lymph nodes. Core biopsy showed poorly differentiated neuroendocrine carcinoma and invasive ductal carcinoma grade III, estrogen and progesterone receptors were positive, immunohistochemistry markers LCA was negative while cytokeratin, E-Cadherin, CD 56 were positive. Metastatic work up was negative, she received 04 cycles of AC (Adriamycin & cyclophosphamide) and 12 cycles of weekly paclitaxel, followed by modified radical mastectomy. Final histopathology report showed poorly differentiated neuroendocrine tumor of the breast, a variant of invasive ductal carcinoma grade III. Final pathological staging was T3N3M0. She received adjuvant radiotherapy. She received tablet

anastrozole (an aromatase inhibitors) as hormonal therapy. She has completed 4 years of disease free survival.

Case 2

Second case was registered in 2013. Second patient was 55 years female. Mammogram and ultrasound revealed BIRADS category IV-C ultrasound showed two lesions in right breast, measuring 42 mm & 22mm (Figure 2). Core biopsy of the lesions revealed high grade neuroendocrine carcinoma, CD 56 and cytokeratin granular were positive. Metastatic workup was negative, she underwent modified radical mastectomy. Final histopathology report showed small cell neuroendocrine tumor of breast. Pathological staging was T2N2Mo. She received 6 cycles of cisplatin & etoposide. She developed later on developed multiple, hepatic, skeletal & pulmonary. Patient is currently hospitalized for palliative care.

DISCUSSION

Primary neuroendocrine neoplasm of breast are a rare form of breast malignancy accounting for about 5 % of breast tumors (Anlauf *et al.*, 2015), World Health Organization (WHO) classify neuroendocrine neoplasms of the breast as, well differentiated neuroendocrine tumors, poorly differentiated small cell neuroendocrine tumors, and invasive mammary carcinoma with neuroendocrine differentiation (Lakhani *et al.*, 2012), according to Watcher *et al* presentation is usually at advanced stage (Watcher *et al.*, 2014). Invasive breast carcinoma with neuroendocrine features was first described in 1963 (Feyrter and Harmann, 1963).

*Corresponding author: Razia Bano,

¹Surgical Oncology Department- Shaukat Khanum Memorial Cancer Hospital & Research Centre

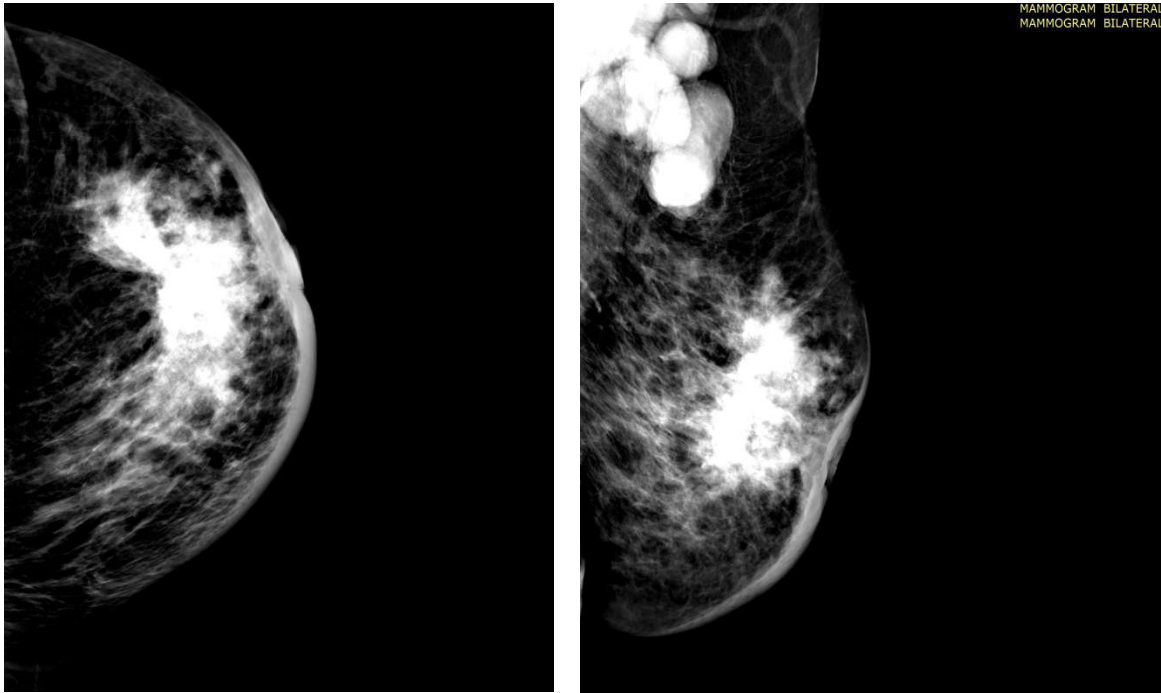


Figure 1. Mammographic findings of neuroendocrine tumor

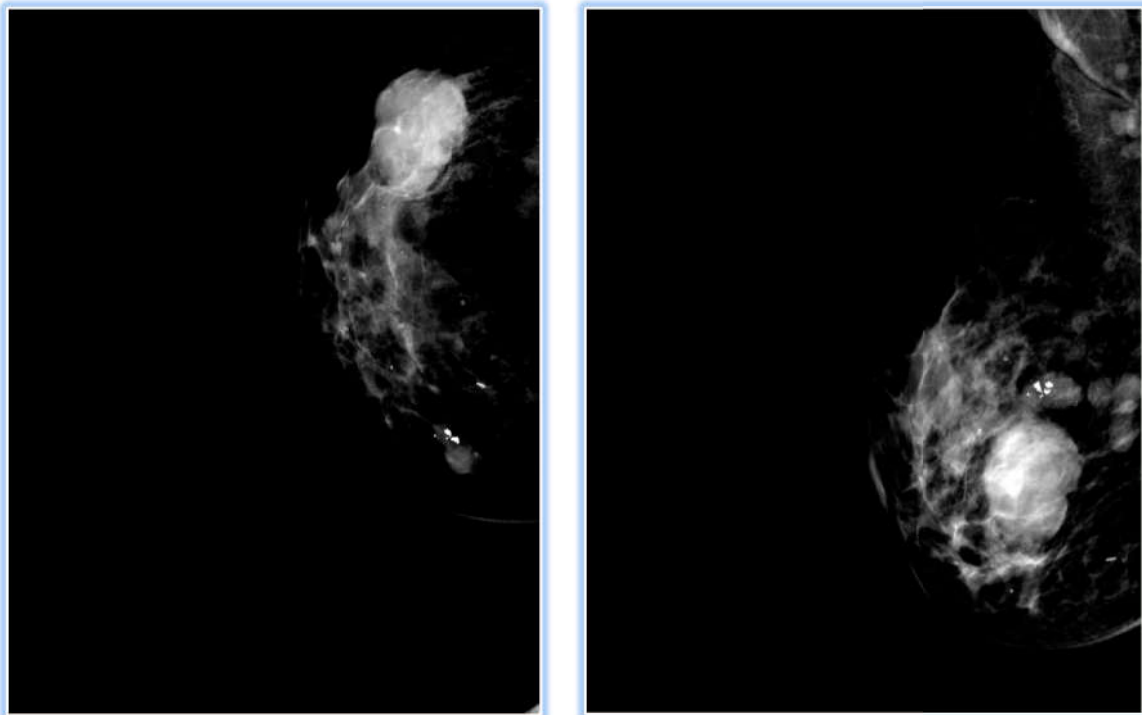


Figure 2. Radiological features of small cell neuroendocrine tumor breast

Specific neuroendocrine markers include expression of chromogranin A and synaptophysin and CD56 (Righi *et al.*, 2010), presence of one of these immunohistochemistry markers in more than 50% of the tumor cells confirms the diagnosis of NEN of the breast (López-Bonet *et al.*, 2008). Presentation may be in elderly females, Rovera *et al* reviewed 96 patients of neuroendocrine breast, they documented better prognosis of NEN, 10 year survival was 87 % in their study (Rovera *et al.*, 2013). Common presentation is painless breast lump (Suhani *et al.*, 2014), however it may present with nipple discharge, nipple retraction (Jeon *et al.*, 2014). Some studies describe imaging features of neuroendocrine as high density lesion

lobulated or speculated lesion, however imaging features may not differentiate primary neuroendocrine tumors from other subtypes of breast carcinoma (Gunhan-Bilgen *et al.*, 2003; Chang *et al.*, 2013). Park *et al* studied clinical, radiological and histological features in 78 women, they describe as round to oval masses, may be non speculated, irregular or hypoechoic, microcalcifications are less common in these tumors (Park *et al.*, 2014). Treatment include surgery, chemotherapy ,hormonal therapy in receptor positive tumors, & radiation therapy depending upon size of the tumor, Yildirim *et al* reported 6 cases of primary neuroendocrine breast tumors (Yildirim *et al.*, 2011).

Conclusion

Primary neuroendocrine tumors of the breast are a rare entity. They can be treated successfully by surgery, chemotherapy, radiation and hormonal therapy.

REFERENCES

- Anlauf M, Neuman M, Bomberg S, Luczak K, Heikau S, Gustmann C *et al.* 2015. Neuroendocrine neoplasm of breast. *Pathologie*. May, 36(3) 261-70.
- Chang ED, Kim MK, Kim JS, Whang IY. 2013. Primary neuroendocrine tumor of the breast : Imaging features. *Korean J Radiol.*, 14(3): 395-99.
- Feyrter F. and Harmann G. 1963. "On the carcinoid growth form of the carcinoma mammae, especially the carcinoma solidum (gelatinosum) mammae," *Frankfurter Zeitschrift für Pathologie*, vol. 73, pp. 24-39.
- Gunhan-Bilgen J, Zekioglu O, Uston EE, Menis A, Erhan Y. 2003. Neuroendocrine differentiated breast carcinomas: Imaging features correlated with clinical and histopathological findings. *Eur Radiol.*, 13:788-93.
- Jeon CH, Kim SM, Jang M, Yun BL, Ahn HS, Kim SW *et al.* 2014. Clinical and radiological features of neuroendocrine breast carcinoma. *JUltrasoundMed.*, August;33(8):1511-8.
- Lakhani SR, Ellis I, Schnitt S I. *et al.* 2012. WHO Classification of Tumours of the Breast. International Agency for Research on Cancer, IARC Press, Lyon, France.
- López-Bonet E¹, Alonso-Ruano M, Barraza G, Vazquez-Martin A, Bernadó L, Menendez JA. 2008. Solid neuroendocrine breast carcinomas: incidence, clinicopathologic features and immunohistochemical profilings. *Oncol Rep.*, Dec., 20(6):1369-74.
- Ogawa, Nishio A, Satak H *et al.* 2008. Neuroendocrine tumors in the breast. *Radiat Med.*, 28:28-32.
- Park YM, Wu Y, Wei W, Yang WT. 2014. Primary neuroendocrine carcinoma of the breast: clinical, imaging, and histologic features. *AJR Am J Roentgenol.*, Aug., ;203(2):221-30.
- Righi L, Sapino A, Marchio C, Papotti M, Bussolati G. 2010. Neuroendocrine differentiation in breast cancer: established facts and unresolved problems. *Semin Diag Patthol.*, Feb. 27(1):69-76.
- Rovera F, Lavazza M, La Rosa S, Fachinetti A, Chiappa C, Marelli M *et al.* 2013. Neuroendocrine breast cancer: retrospective analysis of 96 patients and review of literature *Int J Surg.*, 11 Suppl 1:S79-83.
- Suhani , Ali S, Desai G, Thomas S, Aggarwal L, Meena K, *et al.* 2014. Primary neuroendocrine carcinoma breast :our experience. *Breast Dis.*, 34(3):95-9.
- Watcher DL, Hartmenn A, Beckmann MW, Fasching PA, Hein A, Bayer CM *et al.* 2014. Expression of neuroendocrine markers in different molecular subtypes of breast carcinoma. *Biomed Res Int.*, Feb.
- Yildirim Y, Elagoz S, Kouncu A, AydinC, Karadayi K. 2011. Management of neuroendocrine carcinomas of the breast: A rare entity. *Oncology letters*, 2:887-90.
- Zhang JY, Chen WJ. 2011. Bilateral primary neuroendocrine carcinoma in a young women: Report of a case. *Surg., Today*, 41:1575-78.
