



CASE REPORT

ECTRODACTYLY: THE 'LOBSTER CLAW' ANOMALY – RARE REPORT OF AN INDIAN FAMILY DEMONSTRATING AUTOSOMAL DOMINANT INHERITANCE PATTERN

***Muhammed Basheer, K. T., Sunil Kumar Agarwalla, Pulak Ranjan Mallik and Subhrajit Parida**

Department of Paediatrics, MKCG Medical College Brahmapur, Odisha, India

ARTICLE INFO

Article History:

Received 30th August, 2016
Received in revised form
08th September, 2016
Accepted 23rd October, 2016
Published online 30th November, 2016

Key words:

Ectrodactyly, Split hand/foot malformation,
Syndactyly, Non-syndromic,
Autosomal dominant, Transverse bone.

Copyright © 2016, Muhammed Basheer et al. This is an open access article distributed under the Creative Commons Attribution License, which permits unrestricted use, distribution, and reproduction in any medium, provided the original work is properly cited.

Citation: Muhammed Basheer K T., Sunil Kumar Agarwalla., Pulak Ranjan Mallik and Subhrajit Parida, 2016. "Ectrodactyly: The 'Lobster Claw' Anomaly – Rare Report of an Indian Family Demonstrating Autosomal Dominant Inheritance Pattern", *International Journal of Current Research*, 8, (11), 41192-41194.

ABSTRACT

Ectrodactyly [Split hand/foot malformation (SHFM) or cleft hand or claw hand or lobster anomaly or central ray deficiency] is a limb malformation involving central rays of autopod and presenting with median clefts of hand and feet, hypoplasia/ aplasia of phalanges or metacarpals or metatarsals and variable syndactyly. It can occur either as part of a syndrome like EEC (ectrodactyly-ectodermal dysplasia-cleft syndrome) or isolated non-syndromic malformation. Inheritance pattern is autosomal dominant with variable penetration. Likely pathogenic mechanism is failure of defects in median apical ectodermal ridge activity. Here we are reporting autosomal dominant non-syndromic ectrodactyly (with syndactyly and transverse bone) in an Indian family due to rarity of incidence.

INTRODUCTION

Ectrodactyly is a limb malformation involving central rays of autopod and presenting with median clefts of hand and feet, hypoplasia/aplasia of phalanges or metacarpals or metatarsals and variable syndactyly. It can occur either as part of a syndrome like EEC or isolated non-syndromic malformation (Basel et al., 2006; Pinette et al., 2006). Most common inheritance pattern is autosomal dominant with variable penetration, but rarely autosomal recessive or X linked pattern do occur (Zlotogora et al., 1994). Here we are reporting a case of autosomal dominant non-syndromic ectrodactyly.

Case report

Eleven yr old male child, first child of a non-consanguineous marriage presented to OPD with viral fever was found to have deformed hands and feet- since birth (Figure-1). It was the product of a term, NVD without any significant perinatal events. Incidentally father was also found to have similar deformities. No such deformities in rest of the members of the family. There was no history of similar clinical profile in any of the relatives of both the parents.

In the right hand: Aplasia of phalanges of middle finger and flexion deformity of index finger were seen. (Figure-2 &3)

In the left hand: Along with aplasia of phalanges of middle finger transversely arranged bone and syndactyly were found. (Figure-2&3)

In both the feet: Normal metatarsals and aplasia of phalanges were seen. (Figure-4&5) There were no other dysmorphic features. Anthropometric measurements within normal limits. Developmentally appropriate for age. Echocardiogram was done to rule out any congenital heart disease. Audiometric evaluation done to look for sensorineural hearing loss.

Father's phenotype: In both the hands there was aplasia of phalanges of middle finger (Figure-6). Both the feet were normal No other dysmorphic features. Intelligence was normal

DISCUSSION

Ectrodactyly is the limb malformation with underdeveloped or absent central digits of hand or foot and clefts of hand or foot. It is associated with syndactyly with oligodactyly and rarely polydactyly. The word ectrodactyly was derived from two Greek words - ektroma = abortion, and daktylos = finger (Duroway et al., 2011). It is also known by other names like Split hand/foot malformation (SHFM) or cleft hand or claw hand or lobster anomaly or central ray deficiency.

***Corresponding author: Muhammed Basheer, K.T.**

Junior Resident, Department of Paediatrics, MKCG Medical College Brahmapur, Odisha, India.

Table 1. Ectrodactyly different types (Amalnath et al, 2014)

	Inheritance	Locus	Gene	Associated condition
Type 1	Autosomal dominant	7q21	DLX6, DLX5, DSS1	Sensorineural-hearing loss
Type 2	X-linked recessive	Xq26	FGF13	
Type 3	Autosomal dominant	10q24	HOX11, FGF8	
Type 4	Autosomal dominant	3q27	TP63	EEC syndrome
Type 5	Autosomal dominant	2q31	HOXD13	Mental retardation, Micrognathia, Low set ears
Type 6	Autosomal recessive	12p11	WNT10B	Syndactyly, Polydactyly

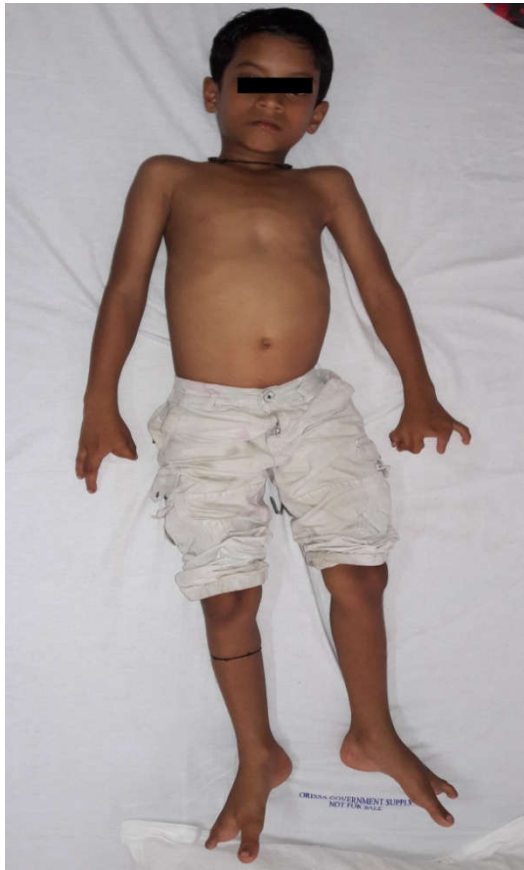

Figure 1. Ectrodactyly affecting both hands and feet

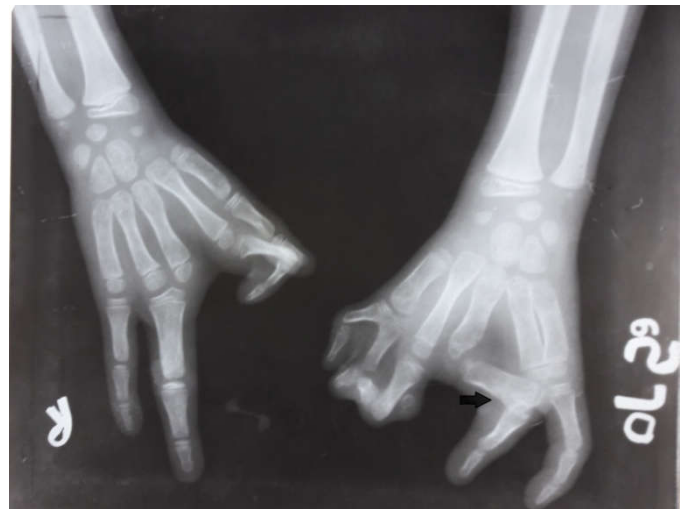

Figure 3. Arrow mark indicates transverse bone (Its growth will widen the cleft)

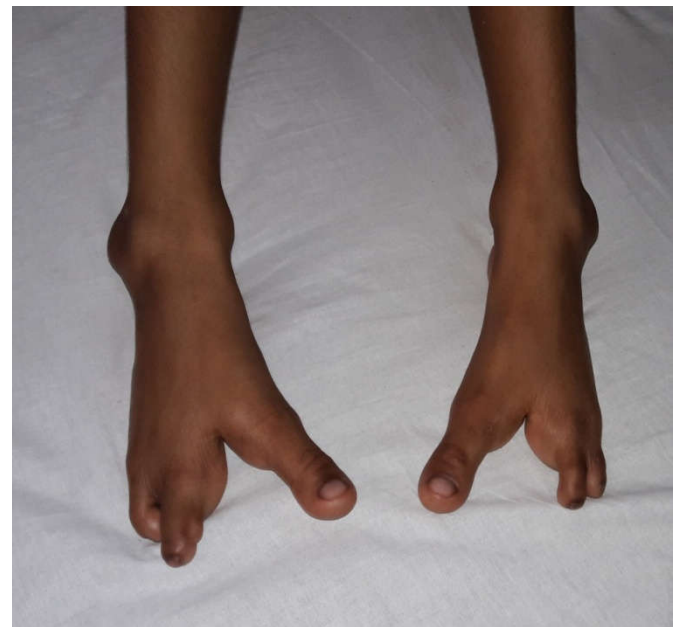

Figure 4. Aplasia of phalanges of toes in both the feet with classical cleft foot or split foot appearance

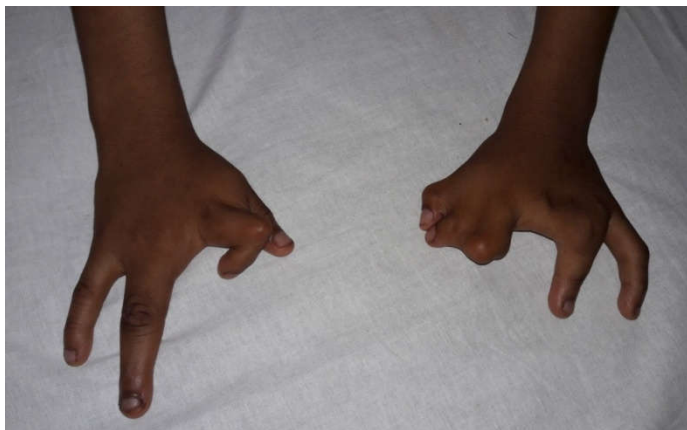


Figure 2. Right hand--Aplasia of phalanges of middle finger, Flexion deformity of index finger; Left hand-- Aplasia of phalanges of middle finger, Syndactyly between thumb & index finger

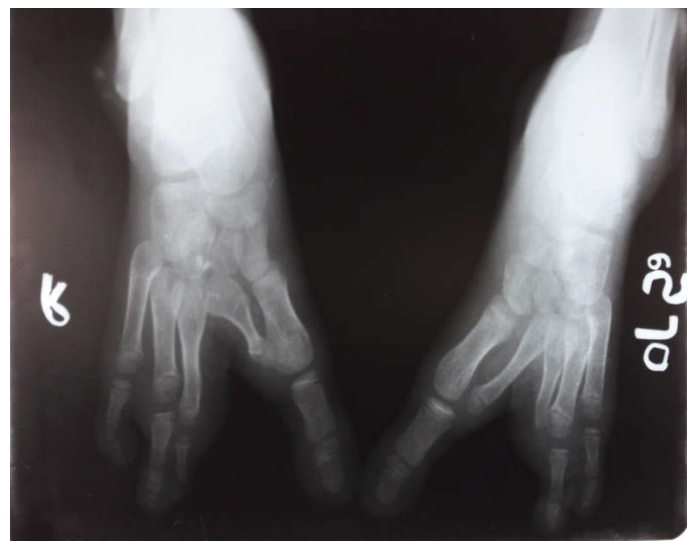

Figure 5. Aplasia of phalanges of toes (Right-2nd, Left-2nd & 3rd) depicted in X-ray

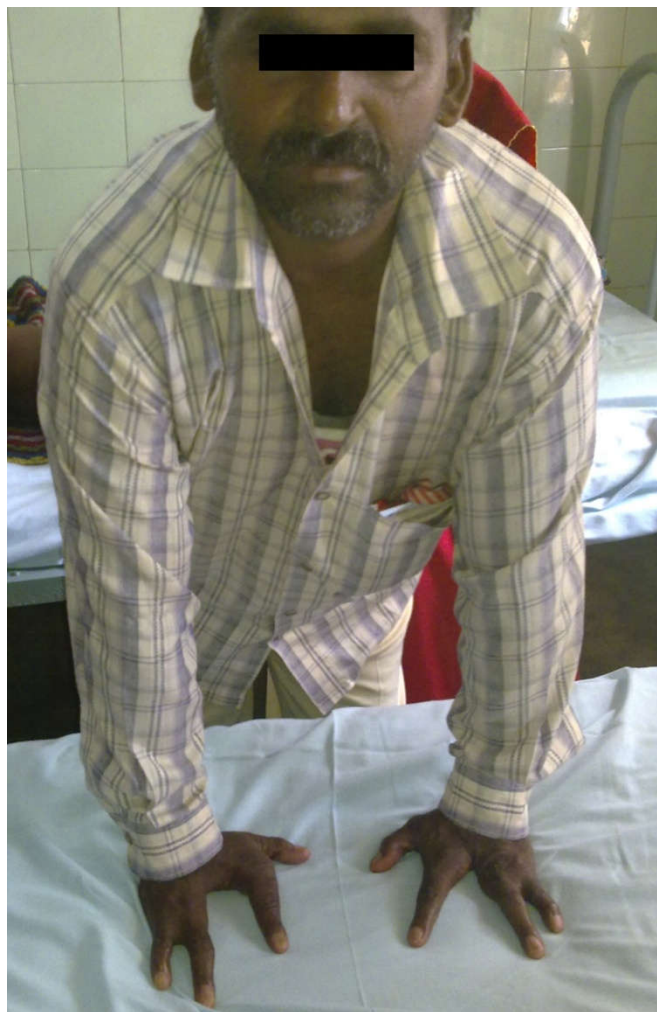

Figure 6. Both hands--Aplasia of phalanges of middle fingers

Its incidence has been reported to be about 1 in 90,000 babies with no sex predilection (Jindal *et al.*, 2009). It can present as an isolated form or in combination with additional anomalies affecting the long bones- nonsyndromic form or other organ systems including the craniofacial, genitourinary and ectodermal structures- syndromic ectrodactyly (Basel *et al.*, 2006; Pinette *et al.*, 2006). Nearly 50 syndromes have been described with SHFM, the most common being the ectrodactyly-ectodermal dysplasia-cleft syndrome (EEC) with cleft lip/palate and teeth and skin anomalies. Other syndromic variants are Silver-Russel syndrome, Cornelia de Lange syndrome, ectrodactyly-ectodermal dysplasia-macular dystrophy syndrome, acrorenal syndrome, ectrodactyly – mandibulofacial dysostosis, focal dermal hypoplasia and ectrodactyly-polydactyly (Winter *et al.*, 1987). Nonsyndromic form can have associated long bone defects like tibial aplasia or fibular aplasia, then it is known as SHFM with long bone deficiency (SHFLD). Our case belongs to the non-syndromic type of SHFM as there is no associated anomaly. The syndromic form has a variable degree of expression. The non-syndromal SHFM limited to the hands and feet usually follows the pattern of autosomal dominant inheritance with a high penetrance (Zlotogora *et al.*, 1994). Rarely they may follow autosomal recessive or X linked pattern. In the pedigree of our patient both son and father affected implying that it follows autosomal dominant inheritance pattern. Six types of SHFM are described

till date (Type 1-6) and among which type-1 is most common variety (Table-1) (Amalnath *et al.*, 2014). The three major tissues responsible for limb patterning are: Apical ectodermal ridge (AER), zone of polarizing activity (ZPA), and progress zone (PZ). The AER determines the proximodistal axis by directing the PZ. The ZPA determines the anteroposterior axis of the limb (Duijf *et al.*, 2003). Failure of limb patterning leads to increased cell death or reduced cell proliferation, which in turn results in central ray defects. If ectrodactyly patients are having transverse bone, then deformity will progress as growth of the bone will widen the cleft. Our patient does have such transverse bone in left hand. This will make surgical correction a necessity for cosmetic as well as functional advantage. Appropriate prosthetics needed in some cases. Effective counselling regarding recurrence in next pregnancy and antenatal ultrasonography remains cornerstone of a multidisciplinary approach.

Conclusion

Ectrodactyly or Split hand/foot malformation is a rare congenital malformation of limb with median cleft and hypoplasia of phalanges. Most commonly it follows autosomal dominant inheritance pattern. Surgical correction can be considered if it is associated with transverse bone or syndactyly. Proper counselling regarding recurrence in future siblings should be done with advise to go for antenatal ultrasound.

Conflict of interest: Nil

Funding: Nil

Acknowledgements

Special thanks to Dept. of Paediatrics and Dept. of Orthopedics for precious works.

REFERENCES

- Amalnath SD, Gopalakrishnan M, Dutta TK. 2014. Split-hand/feet malformation in three tamilian families and review of the reports from India. *Indian Journal of Human Genetics*, 20(1):92-95. doi:10.4103/0971-6866.132769.
- Basel D, Kilpatrick MW, Tsipouras P. 2006. The expanding panorama of split hand foot malformation. *Am J Med Genet A.*, 140A:1359–1365.
- Duijf PH, van Bokhoven H, Brunner HG. 2003. Pathogenesis of split-hand/split-foot malformation. *Hu Mol Genet.*, 12:R51–60.
- Durowaye M, Adeboye M, Yahaya-Kongoila S, et al. 2011. Familial Ectrodactyly Syndrome in a Nigerian Child: A Case Report. *Oman Medical Journal*, 26(4):275-278. doi:10.5001/omj.2011.67.
- Jindal G, Parmar VR, Gupta VK. 2009. Ectrodactyly/split hand feet malformation. *Indian Journal of Human Genetics*, 15(3):140-142. doi:10.4103/0971-6866.60191.
- Pinette M, Garcia L, Wax JR, Cartin A, Blackstone J. 2006. Familial ectrodactyly. *J Ultrasound Med.*, 25:1465–7.
- Winter RM, Baraitser M. 1987. The London dysmorphology database. *J Med Genet.*, 24:509–10.
- Zlotogora J. 1994. On the inheritance of the split hand/split foot malformation. *Am J Med Genet.*, 53:29–32.