



CASE REPORT

FULL MOUTH REHABILITATION WITH INTERDISCIPLINARY APPROACH IN A PATIENT WITH SEVERE DENTAL FLUOROSIS:-A CASE REPORT

¹Dr. Arvind Singh, ^{*}²Dr. Rahul Mishra, ²Dr. Rajmangal Yadav, ²Dr. Abhishek Parashar, ¹Dr. Archana malviya and ²Dr. Gunjan Verma

¹Department of Prosthodontics, Chandra Dental College, Barabanki

²Department of Dentistry, UPUMS, SAIFAI, ETAWAH

ARTICLE INFO

Article History:

Received 22nd May, 2016
Received in revised form
25th June, 2016
Accepted 04th July, 2016
Published online 31st August, 2016

Key words:

Full mouth rehabilitation,
Dental fluorosis,
Centric relation,
Developmental anomalies,
Pedodontics.

ABSTRACT

Treatment of severe generalized dental fluorosis with surface defects to rehabilitate esthetics, phonetics, and mastication require removal of unsupported and pitted enamel and/or dentine, reestablishment of centric relation with or without reestablishing vertical dimension of occlusion and fabrication of full mouth crown and bridge work. Full mouth rehabilitation continues to be the biggest challenge to any clinician in Restorative dentistry. It requires efficient diagnosis and elaborates treatment planning to develop ordered occlusal contacts and harmonious articulation in order to optimize stomathognathic function, health and esthetics which then translates to patient's comfort and satisfaction. This case report describes the Full mouth rehabilitation of a 21 year old boy who reported with multiple decayed and discolored fluorosed teeth. The case was treated with individual Porcelain fused to metal crowns and a bridge with Group function occlusal scheme using Simultaneous full arch technique which is although exacting, exhaustive and demanding provides for a structured stable and predictable articulation.

Copyright©2016, Rahul Mishra. This is an open access article distributed under the Creative Commons Attribution License, which permits unrestricted use, distribution, and reproduction in any medium, provided the original work is properly cited.

Citation: Dr. Arvind Singh, Dr. Rahul Mishra, Dr. Rajmangal Yadav, Dr. Abhishek Parashar, Dr. Archana malviya and Dr. Gunjan Verma. 2016. "Full mouth rehabilitation with interdisciplinary approach in a patient with severe dental fluorosis:-a case report", *International Journal of Current Research*, 8, (08), 37279-37282.

INTRODUCTION

Dental fluorosis is a developmental disturbance of enamel caused by successive exposures to high concentrations of fluoride during tooth development (Alvarez *et al.*, 2009). Severely fluorosed teeth may undergo post eruptive surface breakdown and dark brown to black staining (Nq, 2007). The enamel is often affected and may vary from areas of flecking to diffuse opacous mottling, while the color of the enamel ranges from chalky white to a dark brown/black. Brown/black discoloration may be posteruptive and probably caused by the internalization of extrinsic stain into the pitted enamel (Weatherall, 1972), which indicates dental fluorosis. Treatment of severe generalized dental fluorosis to acceptable aesthetic and mastication especially in young age remains a great challenge. Conformative means of occlusal rehabilitation at the intercuspal position or ICP has to be weighed against the more radical reorganization of occlusion at the centric relation contact position or CRCP, as it requires exhaustive planning

and structured treatment procedures. However, in most cases requiring Full mouth rehabilitations, reorganizing the occlusion is the only means by which we can predict a self-sustained, self maintaining masticatory mechanism ensuring health, harmony and comfort.

Case Report

A 16 year old boy moderately built with good general health and no systemic ailments reported to the Department of Dentistry, UPUMS, Saifai. He complained of discolored and multiple decayed teeth with "chipping off" in the posteriors. The patient gave a history of residence since his birth at a village in Etawah District which had high fluoride levels in the ground water and informed of the same problem with his younger siblings. On clinical and radiographic examination it was seen that he suffered from generalized dental fluorosis with severe mottling of the enamel and dark brown discoloration (Deans Fluorosis Index: Severe) (Fig 1). Multisurface caries with occlusal wear in all the posterior teeth. Patient was given various treatment options and he consented for Full mouth rehabilitation. Miracle mix

**Corresponding author: Rahul Mishra,*
Department of Dentistry, UPUMS, SAIFAI, ETAWAH

restorations were made in all the carious teeth and RCT was done in 11,12,21,22 (Fig 2). Diagnostic impressions were made with irreversible hydrocolloid (Neocolloid, Zhermack, Italy) and the maxillary cast oriented to the articulator axis with a facebow record (Quick mount facebow, Whipmix, U.S.A.). (Fig 3&4) A leaf gauge was used to deprogramme the mandible and was maneuvered into centric closure and a thin trapezoidal Aluwax sheet was used to record the same without any tooth contact (perforation) and the relation used to transfer the mandibular cast to a semi adjustable articulator (Whip mix #8500, U.S.A.). Protrusive occlusal registration was made with fast setting polyvinylsiloxane bite registration material (BluMousse, Parkell, U.S.A.) and the articulator adjusted. Diagnosticocclusal assessment was done and any interference during centric closure noted and removed in the patient's mouth. A permissive occlusal splint fabricated in clear auto-polymerizing resin on the articulated casts was then given both as a definitive deprogrammer and also to assess the possibility of increasing the vertical dimension by 2mm if and when required, given his occlusalwear (Fig 4).

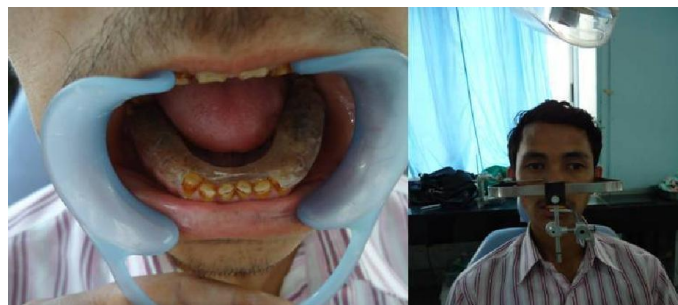

Fig. 4. Permissive occlusal splint & Facebow recording

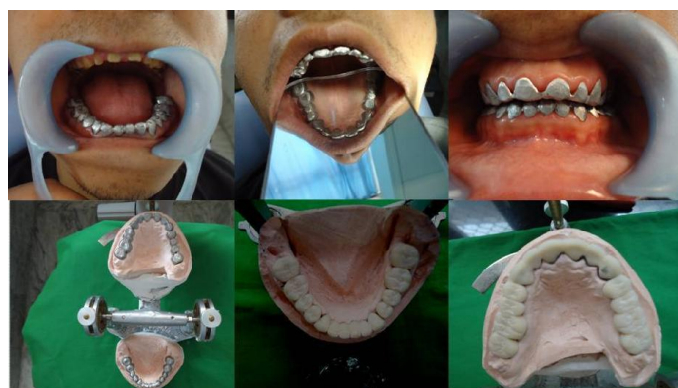

Fig. 5. Intraoperative photograph of PFM Crown Fabrication

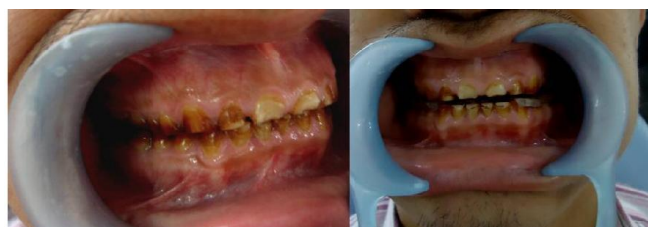

Fig. 1. Preoperative view

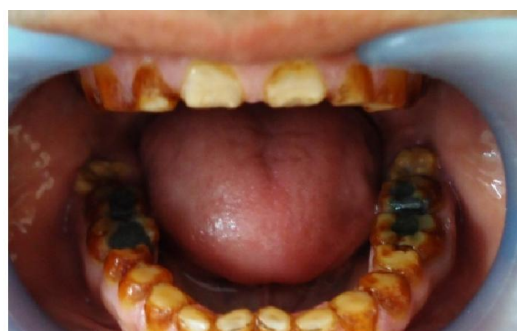

Fig. 2. Restored Teeth

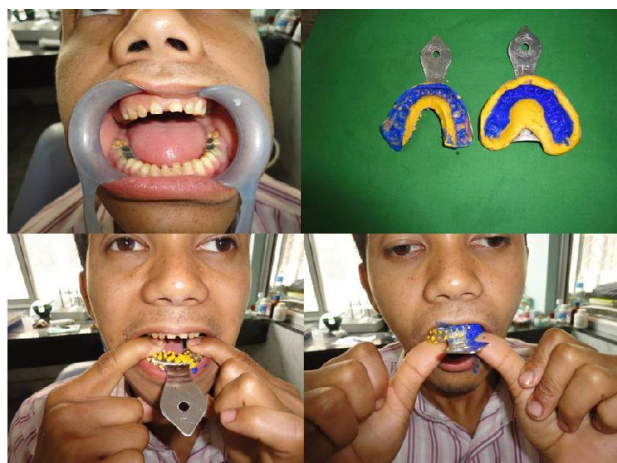

Fig. 3. Tooth preparation & PVS impressions

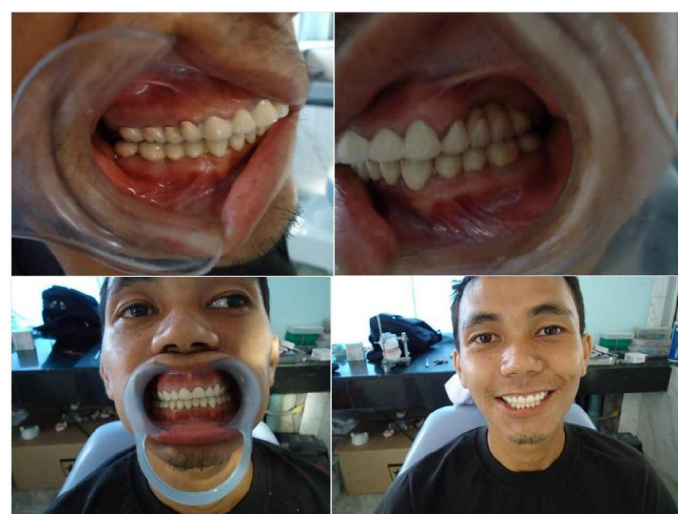


Fig. 6. Postoperative Photograph

A diagnostic wax up was made on the articulated models and two Putty Silicone indices (Aquasil, Dentsply, U.S.A.) were made on the Diagnostic waxup models, one complete for fabrication of the temporaries and the other sectioned to aid as a guide during tooth preparation. When after using the splint for 6weeks, the patient reported of no discomfort, a Reorganized approach to the full mouth rehabilitation with individual porcelain fused to metal crowns and a PFM bridge and Group function occlusal scheme through a simultaneous full arch technique was planned. The maxillary and mandibular teeth were prepared simultaneously and impressions made with poly vinyl silicones (Aquasil Putty and Aquasil LV, Dentsply, U.S.A.). Complete arch dies were prepared and the casts mounted using renewed facebow, centric and the protrusive

interocclusal records. Temporization (Tooth Shade Acrylic, Duralay, U.S.A.) was done indirectly using the Putty Silicone index from the diagnostic wax up. Metal coping trial was made to confirm fit and marginal integrity. Ceramic (IPS Classic, Ivoclar Vivadent) was fired onto the copings and was followed by the bisque try-in. Final occlusal adjustments to the modified incisal guidance during protrusion were made and Unilateral group function on the working sides was adjusted and confirmed (Fig 5). The crowns and the bridge were finally stained and glazed and cemented with a glass ionomer (GC FujiI) luting cement (Fig. 6). Patient was then put on a strict oralhygiene regimen and recall schedule.

DISCUSSION

Fixed Prosthodontic procedures fall in one of two categories- Conformative or Re-organized. Conformative occlusal approach is generally followed when relatively small amount of restorative treatment is required and is designed around the patients existing Inter Cuspal Position, ICP (or Maximum Intercuspation, MI) which may or may not coincide with the Centric Relation. It is limited to localized occlusal adjustments involving the tooth to be prepared or its immediate vicinity such as removal of deflecting contact, shortening of the opposing cusp, elimination of non-working side interferences. Reorganized approach is needed when the present ICP is unacceptable and needs to be changed or when extensive restorations are required to optimize the patient's occlusion. Herein, the ICP is developed at the Centric Relation position of the Mandible or the ICP is made coincident with the CRCP (Centric Relation Contact Position). This provides an even and stable occlusion and ensures there are no pathogenic deflective contacts. Therefore, most of all full mouth rehabilitations tread the Reorganized approach as it restores the structural and functional integrity of the dental arches that are compromised extensively by decayed, missing, broken, worn, discolored teeth or teeth suffering from developmental defects or faulty fixed prosthodontic work. Once the decision of full mouth rehabilitation is arrived at, two questions need to be answered, what sequence of tooth preparation and restoration is to be followed and what occlusal scheme to give. Choices range from Simultaneous full arch or Segmental/ Quadrant or Sequential simultaneous techniques and Group function or Canine guided occlusal schemes. Each comes with its own merits and demerits.

The choice is balanced between what is best for the patient given the clinical condition and patient's expectation and the operators experience and understanding. Irrespective of the choice, the treatment protocol should essentially include preliminary procedures directed towards eliminating pain, infection, carious lesions and teeth with poor prognosis by an interdisciplinary team of specialists followed by a full analysis of occlusion as it exists. Analysis of the occlusion requires the transfer of the maxillary and mandibular diagnostic casts to a capable articulator which provides for a more convenient and relatively definite means of assessment. This requires a Facebook record to orient the maxillary cast to the opening and closing axis of the articulator and a set of interocclusal records, one the centric relation record and the other the protrusive and laterotrusive records which are used to transfer the mandibular

cast to the articulator and adjust the lateral and horizontal condylar guidances. Deprogramming of the mandible from a learned pattern of neuromuscular memory to change it from a tooth guided (ICP) to a joint guided (CRCP) movement facilitates easier maneuver into Centric closure and therefore identifying any prematurities and deflecting contacts. Permissive occlusal splints are excellent deprogramming devices and also of diagnostic value in cases where the vertical dimension is planned to be increased. Guiding the mandible into centric closure is achieved by one of many methods like chin point guidance, Dawson's bimanual manipulation Tongue to palate manoeuvre. Many recording media are available for interocclusal registration like plaster, thermoplastic waxes, zincoxideeugenol pastes, silicones and polyethers.

For its ease of manipulation and non-compressibility after setting, Aluwax is a relatively convenient material for registration. Centric records can be made with bimanual manipulation and a wax record in patients who exhibit easy movement along the retruded arc. Anterior stop techniques such as tongue spatula, modified leaf gauge acrylic jig can be used in patients showing difficulty in movement along the retruded arc (Woelfel and Lee, 1991 and Lodge Le, 1967). Analyze the occlusion on the articulated casts, identify and remove sequentially any prematurities and interferences before the Diagnostic wax up is started after the preparation on the gypsum teeth. Wax is built up and contoured to the selected scheme of occlusion and the anterior guidance modified there in form and position (Irad, 1987). Putty Silicone indices are made on the Diagnostic wax up models, one complete for fabrication of the temporaries and the other sectioned to aid as a guide during tooth preparation (Martin and Cardash, 1981). The Simultaneous full arch technique requires restoring both the arches at once with complete arch prepared dies and provides the convenience of flexibility in an occlusal plane, occlusal scheme, embrasures, crown contours and esthetics which are restricted in the Quadrant/segmental technique. However it is arduous and requires a full arch anesthesia. Canine guided occlusion is preferred in most full mouth rehabilitations because of its ease of fabrication (Lucia, 1962; Amico, 1961; Stallard, 1963 and Mann, 1987). However in cases where the canines are missing or are compromised by developmental deficits such as short roots, malocclusion, marked jaw size discrepancy and periodontal disease, Group function provides for a more stable and self-maintaining scheme of occlusion and distributes the force over greater number of teeth on the mediotrusive side. Group function or Unilateral balanced occlusion has its origin in the works of Schuyler (Schuyler, 1969), Pankey, Mann (Mann, 1963), Ramfjord (Ash, 1982), etc. This ensures that there is distribution of contacts on all the posterior teeth in centric position thereby applying forces along their long axes. Disocclusion occurs in the posteriors during protrusion and during lateral movements disocclusion on the non-working side occurs against the canine and buccal cusps of maxillary and mandibular premolars and molars on the working side. Group function on the working side distributes the occlusal load onto several teeth and the absence of contacts on the non-working side prevents destructive oblique forces on the teeth. However developing Group function requires greater clinical and technical precision and is relatively difficult to achieve.

Conclusion

Optimum oral health should be the prime objective of all rehabilitation procedures because the ultimate goal will always be to restore the mouth to health and function and preserve this status throughout the life of the patient.

REFERENCES

- Alvarez, J.A., Rezende, K.M., Marocho, S.M., Alves, F.B., Celiberti, P., Ciamponi, A.L. 2009. Dental fluorosis: Exposure, prevention and management. *Med Oral Patol Oral Cir Bucal*, 14:103-7.
- Amico. D.1961. Functional occlusion of the natural teeth of man. *J Prosthet Dent*, 2:899-901.
- Ash, M.M and Ramfjord SP. An introduction to functional occlusion, 1982, W.B. Saunders.
- Irad, D.Z. and Francis, A.P. 1987. Full mouth reconstruction fixedremovable. *Dent Clin North Am*, 31-35.
- Lodge Le and Mahan PD. Study of mandibular movement from centric occlusion to maximum intercuspation. *JProsthet Dent.*, 1967; 18:19-30.
- Lucia, C.V. 1962. The Gnathological concepts of articulation. *DentClin North Am*, 183-197.
- Mann, A., Chan, C. and Miralles, R.1987. Influence of group functionand canine guidance on EMG activity of elevator muscles. *J Prosthet Dent*, 57:494-500.
- Mann, A.W. and Pankey, L.D. 1963. The PM philosophy of occlusalrehabilitation. *Dent Clin North Am*, 7:621-629.
- Martin D and H. Cardash. 1983. Transferring anterior occlusalguidance to the articulator. *J Prosthet Dent*, 61:282-285.
- Nq, F., Manton, D.J. 2007. Aesthetic management of severlyfluorosedincisors in an adolescent female. *Aust Dent J*, 52:243-8.
- Peter, E. Dawson. 1989. Evaluation, diagnosis and treatment ofocclusal problems. The C.V.Mosby Company.
- Schuyler, C.H. 1969. Freedom in centric. *Dent Clin North Am*, 13:681-686.
- Stallard, H. and Stuart, C.E. 1963. Conceots of occlusion. *Dent ClinNorth Am*, 11:591-606.
- Stewart, R.K. 1997. Clinical removable Partial Prosthodontics. IEA Publishers, St. Louis.
- Weatherall, J.A., Robinson C, Hallsworth AS. 1972. Changes in the fluorideconcentration of the labial surface enamel with age. *Caries Res*, 6:312-24.
- Woelfel and Lee. 1991. Suggested modification for the leaf wafersystem. *J Prosthet Dent*, 65:287-291.
