



ISSN: 0975-833X

## RESEARCH ARTICLE

### EVALUATION OF HEPATOPROTECTIVE ACTIVITY OF ALCOHOLIC, CHLOROFORM AND AQUEOUS EXTRACTS OF *CONVOLVULUS PLURICALIS* CHOISY

\*<sup>1</sup>Veena Rani, I., <sup>1</sup>Annapurna, A. and <sup>2</sup>Ganapathi, S.

<sup>1</sup>Department of Pharmacology, AU College of Pharmaceutical Sciences, Vishakapatnam-530003, India

<sup>2</sup>Department of Pharmacognosy, Gitam Institute of Pharmaceutical Sciences, Vishakapatnam-530003, India

#### ARTICLE INFO

##### Article History:

Received 13<sup>th</sup> May, 2016

Received in revised form

23<sup>rd</sup> June, 2016

Accepted 19<sup>th</sup> July, 2016

Published online 20<sup>th</sup> August, 2016

##### Key words:

Hepatoprotective,  
Paracetamol,  
DNA Fragmentation.

#### ABSTRACT

The study was designed to evaluate hepatoprotective activity of *Convolvulus pluricaulis* Choisy (CP) belonging to the family Gentianaceae in acute experimental injury by paracetamol (PCM) and the effects observed were compared with known hepatoprotective agent silymarin. Alcoholic (AECP), Chloroform (CECP) and Aqueous (AqCP) extracts of *Convolvulus pluricaulis* Choisy in different doses (150 and 300 mg/kg) were administered to the groups for a period of 10 days which were pretreated with hepatotoxicant paracetamol (2 g/kg). The control group was administered with 1 % Tween 80. The blood sample was collected, centrifuged and the obtained serum was used for the assay of marker enzymes like and the liver was subjected to histopathology. Aspartate aminotransferase (AST/SGOT), Alanine aminotransferase (ALT/SGPT), Alkaline phosphatase (ALP), Acid phosphatase (ACP) and Bilirubin. The liver was subjected to histopathology and DNA Fragmentation assay. Hepatotoxic rats pretreated with silymarin or CP extracts exhibited significant decrease in biochemical parameters enzyme level. From the histopathological observation, lymphocyte infiltration and marked necrosis were observed in PCM-treated groups (negative control), whereas maintenance of the normal hepatic structure was observed in group pretreated with silymarin and the plant extracts. More over the DNA was secured in these treated groups compared to the broken DNA in PCM treated group. In conclusion the AECP, CECP and AqCP extracts exhibited hepatoprotective potential and thus warrants further investigation.

Copyright©2016, Veena Rani et al. This is an open access article distributed under the Creative Commons Attribution License, which permits unrestricted use, distribution, and reproduction in any medium, provided the original work is properly cited.

Citation: Veena Rani, I., Annapurna, A. and Ganapathi, S. 2016. "Evaluation of Hepatoprotective activity of alcoholic, chloroform and aqueous extracts of *Convolvulus pluricalis* choisy", *International Journal of Current Research*, 8, (08), 36110-36115.

## INTRODUCTION

Liver has a major role in many of enzymatic metabolisms and is a primary target for most of the toxicities (Eswarkumar et al., 2013). Severe hepatic injuries have been reported by various drugs, industrial chemicals and infections due to viruses. Several drugs are being drawn out from the marketplace because of delayed discovery of hepatotoxicity which may be due to unpredicted toxicities as a result of differences in the metabolisms in the liver. The materialization of drug-induced hepatotoxicity is highly incoherent, which array from asymptomatic rise of liver enzymes to complete hepatic failure (Michael et al., 2014). Liver disease remains one of the serious health problems. In the absence of consistent liver protective drugs in allopathic medical practices, herbs play an important role in the management of various liver

disorders (Jain et al., 2005). The liver is an important organ because a person's nutritional level is not only determined by what he or she eats, but by what the liver processes. The invention of liver tonics, which act upon liver for protecting against toxins, poisons and pathogens, stimulates regeneration of liver cells and protects against inflammation (Butner GR., 2000). Based on this interest the plant *Convolvulus pluricalis* Choisy was selected to evaluate hepatoprotective activity. Phyto-chemical analysis revealed the presence of Alkaloids, Flavonoids, Glycosides, Steroids, Tannins (Srishti et al., 2012, Asim et al., 2013, Parul et al., 2014). *Convolvulus pluricalis* Choisy has been employed in traditional herbal medicine to treat a variety of health conditions. Some studies showed that extracts and its constituents possess Conditioned avoidance response (Sharma et al., 1965) Cardiac activity (Barak et al., 1966) Antifungal (Gupta et al., 1974) Hypolipidemic (Chaturvedi et al., 1997) Antiulcer (Sairam et al., 2001) Antagonized tremorine induced tremors in mice (Pawar et al., 2001) Antioxidant Activity (Jayashree et al., 2004) Wound

\*Corresponding author: Veena Rani, I.

Department of Pharmacology, AU College of Pharmaceutical Sciences, Vishakapatnam-530003, India.

healing activity (Singh et al., 2005) Antibiotic activity (Meenakshi et al., 2006) and Antidepressant effect in mice by interaction with adrenergic, dopaminergic and serotonergic systems (Dinesh et al., 2007). The present study investigated the hepatoprotective potential of alcoholic, Chloroform and aqueous extract of *Convolvulus pluricalis* Choisy treatment against paracetamol induced liver toxicity in rats. More over DNA fragmentation assay was also carried out as a supportive study.

## MATERIALS AND METHODS

### Drugs and chemicals

Silymarin is obtained from SIGMA chemicals, Mumbai. Paracetamol and all other chemicals used in the study were obtained from S.D fine chem. ltd, Mumbai. All chemicals used in the study were of analytical grade.

### Plant collection, authentication and preparation of extracts

*Convolvulus pluricaulis* Choisy belonging to family *Gentianaceae* flowers and leaves were collected from KRC Reddy Colony Bachupally, Quthubullapur mandal, Hyderabad during the month of December in the year 2012. The plant was authenticated by a taxonomist from Sri Venkateshwara University, Tirupathi. The collected plant material was washed and shade dried for two weeks and powdered mechanically. The dried powder was sieved through mesh no.44. The alcoholic and chloroform extracts were obtained by hot soxhlet extraction with 100gm of powdered drug with 500ml of solvents with 3cycles (yield- 2% w/w) and evaporated under reduced pressure by using rotary evaporator (Buchi-R-210) until a soft mass is obtained. The aqueous extract was obtained by macerating 100gm of the powder with 500ml of double distilled water for 24h with intermittent shaking (yield = 5%w/w). This extract as a suspension was used for further investigation. SGOT/ AST, SGPT/ALT was estimated by Henderson method and Tietz method. Alkaline Phosphatase (Alp) was estimated by king and kings method; Acid Phosphatase was estimated by colorimetric method. Bilirubin by Modified Jendrassik & Grof's Method.

### Animals

Male and female Wistar albino rats weighing about (150-200 g) were used. The animals were housed in polypropylene cages and maintained at 27° ± 2°C and 12 hour light dark cycle. They were acclimatized to the laboratory conditions for 5 days prior to use in animal house. The study was approved by the Institutional Animal Ethics Committee and the reference number is MRCP/PCOL/2012/004. The animals were fed with standard laboratory feed and drinking water ad libitum.

### Study protocol

Suspensions of *Convolvulus pluricalis* Choisy extracts were prepared in 1% tween 80. 54 male wistar albino rats in the weight range of 150-200gms were selected and they are distributed into nine groups as mentioned below, consisting of

six animals each. And the treatments were given as per the following table.

Table 1.

Group	Treatment	Dose (Once daily)
Group I(NC)	Control (1 % Tween 80)	1 ml
Group II (PCM)	Toxicant (Paracetamol)	2g/kg
Group III (SS <sup>*</sup> )	Standard ( Silymarim)	100 mg/kg
Group IV (AEC1 <sup>*</sup> )	Alcoholic Extract	150 mg/ kg
Group V (AEC2 <sup>*</sup> )	Alcoholic Extract	300 mg/ kg
Group VI (CECP1 <sup>*</sup> )	Chloroform Extract	150 mg/ kg
Group VII (CECP2 <sup>*</sup> )	Chloroform Extract	300 mg/ kg
Group VIII (AqCP1 <sup>*</sup> )	Aqueous Extract	150 mg/ kg
Group IX (AqCP2 <sup>*</sup> )	Aqueous Extract	300 mg/ kg

\* Received paracetamol 2g/kg body weight once daily from 4th to 10th day

The blood sample was collected under light ether anesthesia. The collected blood samples were centrifuged at 3000 rpm at 4°C for 10 minutes to separate the serum. The serum was used for the assay of marker enzymes and the liver was subjected to histopathology. The biomarker enzymes like, Aspartate aminotransferase (AST/SGOT), alanine aminotransferase (ALT/SGPT), alkaline phosphatase (ALP), acid phosphatase (ACP), Bilirubin, were estimated from the collected blood samples at the end of the treatment by he following methods. SGOT/ AST, SGPT/ALT was estimated by Henderson method (Henderson et al., 2001) and Tietz method (Tietz, 1995). Alkaline Phosphatase (Alp) was estimated by king and kings method (Tietz, 1976). Acid Phosphatase was estimated by colorimetric method (King, 1959; Bull, 2002). Bilirubin by Modified Jendrassik & Grof's Method (Powell, 1994).

## RESULTS AND DISCUSSION

Serum enzyme levels of animals treated with different doses of Alcoholic, Chloroform and Aqueous extracts of CP were presented in Table no 2 and 3. The results showed that the animals treated with toxicant Paracetamol (PCM), the level of serum enzymes like SGOT, SGPT, ALP, ACP, Total bilirubin, and Direct bilirubin increased significantly. When the animals were treated with different doses of Alcoholic (AECP), Chloroform (CECP) and Aqueous (AqCP) extracts of CP, the serum biochemical parameters of SGOT, SGPT, ALP, ACP, TB and DB were brought down significantly and the activity had shown dose dependency. The serum biochemical parameters reduced drastically which indicated that the extracts have the hepatoprotective action.

Table 2. Serum biochemical parameters in treated rats with different extract of BP against Paracetamol induced damage

GROUPS	SGOT(U/L)	SGPT(U/L)	ALP(U/L)	ACP(U/mL)
NC	29.13±1.01 <sup>a</sup>	36.05±1.423 <sup>a</sup>	108.2±3.27 <sup>a</sup>	17.25±1.11 <sup>***c</sup>
PCM	251.3±12.33 <sup>***</sup>	273.8±12.73 <sup>***</sup>	225.0±2.68 <sup>***</sup>	29.33±1.15 <sup>*</sup>
SS	42.55±0.66 <sup>a</sup>	44.63±1.49 <sup>a</sup>	126.6±1.76 <sup>a</sup>	23.51±1.44
AEC1	144±4.31 <sup>***a</sup>	198.5±8.57 <sup>***a</sup>	162.3±4.03 <sup>***a</sup>	12.5±0.94 <sup>***a</sup>
AEC2	77±4.12 <sup>***a</sup>	102.7±4.57 <sup>***a</sup>	115.8±4.68 <sup>a</sup>	11.63±0.34 <sup>***a</sup>
CECP1	160±7.56 <sup>***a</sup>	171.8±1.63 <sup>***a</sup>	171.5±4.94 <sup>***a</sup>	11.63±0.48 <sup>***a</sup>
CECP2	91.83±2.37 <sup>***a</sup>	117.0±4.07 <sup>***a</sup>	132.5±3.58 <sup>a</sup>	8.930±0.75 <sup>***a</sup>
AqCP1	173.8±6.52 <sup>***a</sup>	192.5±2.02 <sup>***a</sup>	178.3±4.85 <sup>***a</sup>	14.02±1.71 <sup>***a</sup>
AqCP2	116.8±4.10 <sup>***a</sup>	131.5±3.43 <sup>***a</sup>	137.7±4.64 <sup>a</sup>	11.90±0.27 <sup>***a</sup>

Values expressed Mean ± SEM; \*\*\* p<0.0001, \*\*p<0.01 \* p<0.05 when compared to standard group; <sup>a</sup> p<0.001, <sup>b</sup> p<0.01, <sup>c</sup> p<0.05 when compared to Paracetamol group

**Table 3. Serum biochemical parameters in treated rats with different extract of BP against Paracetamol induced hepatic damage**

GROUPS	TB (mg/dL)	DB (mg/dL)
NC	0.1875±0.003 <sup>a</sup>	0.1053±0.002 <sup>**a</sup>
PCM	1.423±0.009 <sup>***</sup>	1.215±0.006 <sup>***</sup>
SS	0.06153±0.001 <sup>a</sup>	0.0808±0.002 <sup>a</sup>
AECP1	0.170±0.009 <sup>***a</sup>	0.1300±0.004 <sup>***a</sup>
AECP2	0.1355±0.011 <sup>a</sup>	0.0942±0.002 <sup>a</sup>
CECP1	0.1675±0.008 <sup>***a</sup>	0.1000±0.005 <sup>a</sup>
CECP2	0.1267±0.006 <sup>a</sup>	0.0818±0.004 <sup>a</sup>
AqCP1	0.1950±0.019 <sup>***a</sup>	0.09375±0.003 <sup>a</sup>
AqCP2	0.1417±0.007 <sup>a</sup>	0.6735±0.186 <sup>***a</sup>

Values expressed Mean ± SEM; \*\*\* p<0.0001, \*\*p<0.01 \* p<0.05 when compared to standard group; <sup>a</sup>p<0.0001, <sup>b</sup>p<0.01, <sup>c</sup>p<0.05 when compared to Paracetamol group

But the levels of these hepatoprotective parameters were higher than the control animals (NC) and animals treated with Standard silymarin (SS) except for ACP where the levels were lower than the control animals and animals treated with Standard silymarin. The serum levels of ACP had decreased significantly by low doses of Alcoholic (AECP1), Chloroform (AECP 1) and Aqueous (AqCP1) extracts of CP and were reduced further in groups treated with higher doses of the extracts (AECP2, ACP2, AqCP2) when compared to control group. The majority of pharmaceutical poisoning today is the over usage of over the counter drugs (OTC). PCM is well known for its OTC medication for analgesic and antipyretic actions. It has been reported that it causes centrilobular hepatic necrosis upon over dose (Litovitz *et al.*, 2002). Quite a few reviews have been reported (Bessems *et al.*, 2001; Nelson *et al.*, 2002) on acetaminophen hepatic toxicity and said that cell death/ necrosis is the manner of toxicity (Lawson *et al.*, 1999; Gujral *et al.*, 2002). It has been revealed that acetaminophen was converted to a reactive metabolite by the action of the enzymes CYP 450 (Mitchell *et al.*, 1973) and its mechanism of liver toxicity is discussed earlier. The increase in the level of serum enzymes like SGPT, SGOT, ALP, etc correlate with the toxic effects of acetaminophen. Whenever there is damage to the hepatocytes, the structural integrity is lost and the enzymes which are present in the cytosol are found in higher levels in the blood stream due to their leakage from the cell. Therefore, the levels of these enzymes can be accounted for the extent of damage of the liver tissue (Sallie *et al.*, 1991). The higher level of SGPT is associated with major liver disorders (Nyblom 2004, 2006). SGOT is found in almost all the tissues of the body, with higher amounts in liver. This enzyme is also found markedly in cardiac tissues, to some extent in Kidneys, skeletal muscles, Brain and RBCs (Ghouri *et al.*, 2010). When compared to SGPT, the increase in levels of SGOT is highly specific marker for liver disorders as they may involve the dangers associated with other major tissues.

In the present study, when the Paracetamol pre-treated animals were treated with Alcoholic, Chloroform and Aqueous extracts of CP, the SGOT and SGPT levels had decreased but not as shown in the animals treated with standard Silymarin. The dose dependency was observed as increase in the dose, decreased the SGOT and SGPT levels further. When Alcoholic (AECP2) and Chloroform (CECP2) extracts were given at 300 mg/kg dose the SGOT levels had decreased significantly but still were not effective as that of the standard Silymarin (SS)

treatment. The Alcoholic extract has a greater effect when compared with other extracts when the dose is increased from 150 mg/kg to 300 mg /kg. Alkaline phosphatase (ALP) is a membrane bound glycoprotein enzyme present in the cells lining the biliary ducts of the liver. ALP helps in dephosphorylation of nucleotides, proteins and some of the alkaloids. It is found in higher concentrations in sinusoids, endothelium, bone and placental tissue. The source of ALP in liver is mainly through bone (Burtes *et al.*, 1986). The levels of ALP are increased in case of hepatobiliary disorders which is in accordance with the results of the present study in rats treated with Paracetamol gave an evidence of protein binding and damage of the cellular integrity (Rajesh MG *et al.*, 2004). The reverse was seen in rats treated with extracts of *Convolvul pluricalus* Choisy which revealed that there was restoration of the serum levels of ALP and maintenance of the structural integrity. When the dose of all the extracts was increased to 300 mg /kg, the levels of ALP had decreased significantly and were comparable with that of the standard drug treatment. Especially alcoholic extract (AECP2) when given at higher dose had greater response in decreasing the levels of ALP even better than the standard (SS) drug treatment and was comparable with the levels found in the control animals. This indicates that the alcoholic extract had a good effect in decreasing the levels of ALP during the hepatotoxicity. Acid Phosphatase (ACP) is another biomarker enzyme, where increase in the levels of the enzyme is due to the dysfunctioning of the tissues.

It is generally present in Liver, Kidneys, Bones, Spleen and in large amounts in Prostate gland and is stored in lysosomes. It helps in the dephosphorylation (Bull *et al.*, 2002). The present study confirmed the hepatocyte dysfunction in rats treated with Paracetamol has been reversed by treatment with different extracts of CP even at 150 mg/kg and the levels were brought down even lesser than the control, which signified that the extracts of CP were able to reverse the levels of ACP during hepatotoxicity. Chloroform extract (CECP) was more effective when compared with other extracts and dose dependency was observed. The TB levels were increased when animals were treated with Paracetamol. The extracts treated groups of CP showed decreased levels even lesser than that of control animals but not to the extent of animals treated with standard silymarin. The levels of TB were brought down to very low when animals were treated with standard drug (SS). The results revealed that all the extracts have tendency to decrease the levels of TB during the hepatotoxicity but were not as effective as that of standard silymarin treatment. The increased levels of DB due to Paracetamol treatment were reversed with treatment of aqueous extract (AqCP1) of CP. Significant effect was not observed with alcoholic (AECP1) and chloroform (CECP1) extracts, but when the dose was increased to 300 mg/kg, the effect was significant. The effects of different extracts of CP were comparable to standard drug treatment.

## RESULTS

To obtain further vision to the Paracetamol induced liver injury mechanism, the liver sections were investigated for the occurrence of nuclear DNA fragmentation and mitochondrial injury as a part of the toxicity mechanism.

## Histopathological sections of the liver tissue

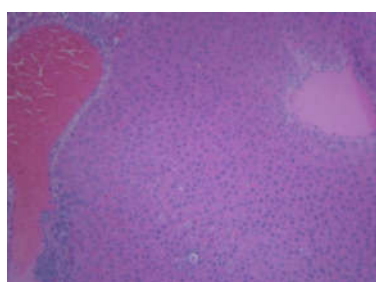


Fig 1. NC2

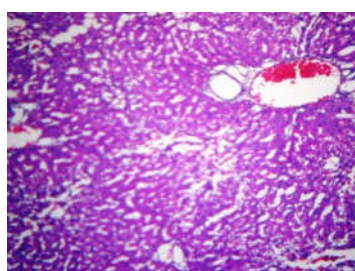


Fig 2. PCM (2g/Kg)

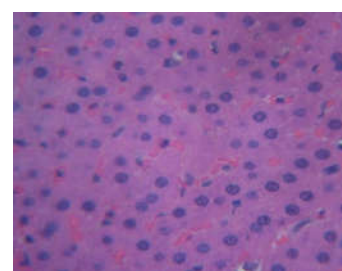


Fig 3. SS2 (100mg/Kg)

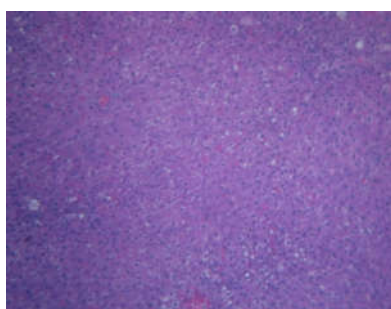

Fig 4. AECPI (150 mg/Kg)

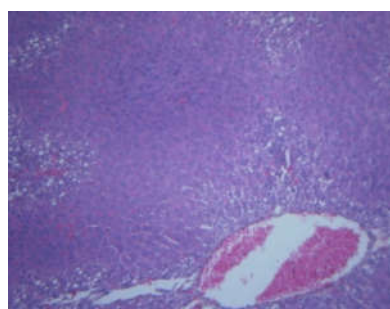


Fig 5. AECPI (300 mg/Kg)

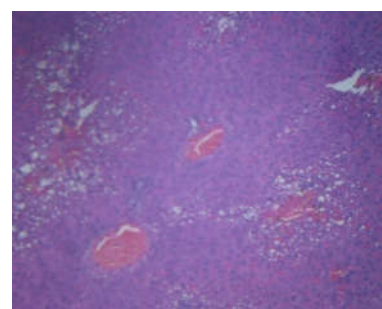


Fig 6. CECPI (150 mg/Kg)

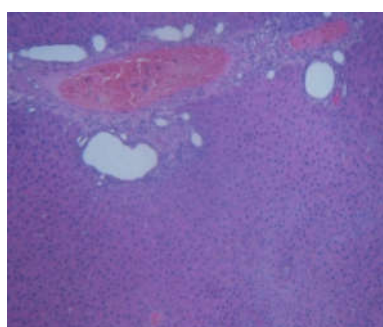


Fig 7. CECPI (300 mg/Kg)

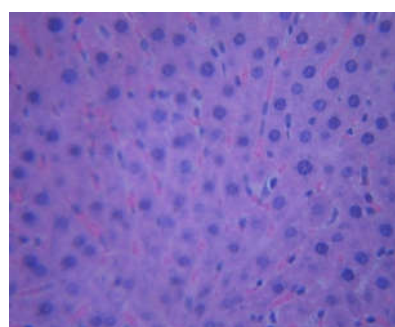


Fig 8. AqCPI (150 mg/Kg)

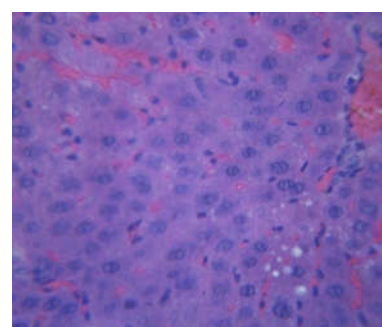


Fig 9. AqCPI (300 mg/Kg)

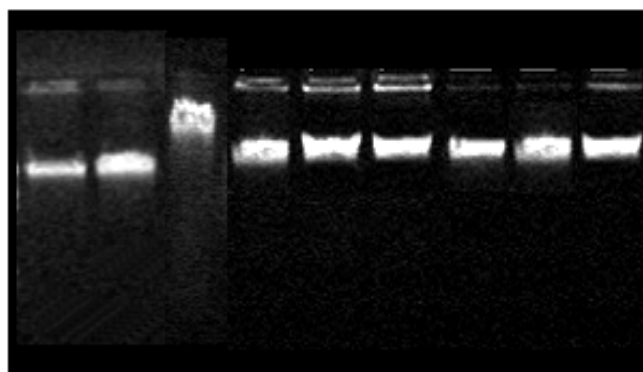
**Fig 1.** Showed normal lobular architecture of liver with hepatocytes arranged in single cords and there were no vacuoles seen in hepatocytes, the central vein was also normal. **Fig 2.** Which was treated with paracetamol showed congestion, infiltration perivenular necrosis and steatosis with degree of steatosis being variable, there was a degeneration of hepatocytes to necrosis. Central lobular vacuoles were seen. **Fig 3.** Showed normal portal tracts, normal lobular architecture, terminal branch of the hepatic artery and portal vein were normal, which indicates the drug's hepatoprotective action and devoid of changes seen with Paracetamol control group. In this group the rat tissue showed less degeneration and disarrangement of hepatocytes. **Fig 4.** Showed the portal tract and central vein with prominent fatty change hepatitis showing early stage of necrosis, with less number of small vacuoles seen occasionally indicated the hepatoprotective action. **Fig 5.** Section showed the portal tract and central vein with normal lobular architecture with less degree of necrosis, with less number of small vacuoles seen occasionally. **Fig 6.** Showed normal architecture, with centrilobular midzonal vacuoles seen occasionally, prominent fatty change hepatitis and early necrosis, and few dilated sinusoids seen around central veins suggesting least hepatoprotective action of Chloroform extract against Paracetamol induced toxicity. **Fig 7.** Showed normal architecture, with less degree of necrosis, with less number of small vacuoles seen occasionally indicating the hepatoprotective action of aq.extract of *Convolvulus pluricalis* Choisy comparative to the 150 m/kg of chloroform extract. **Fig 8.** Showed prominent fatty change hepatitis and early necrosis, occasionally vacuoles are seen in hepatocytes suggesting least hepatoprotective action of aqueous extract against paracetamol induced toxicity. **Fig 9.** Showed the portal tract and central vein consisting sinusoids with normal lobular architecture with less degree of necrosis and no derangement was observed at hepatic cords indicating the protective action. This indicates the dose dependent hepato protective of aqueous extract of *Convolvulus pluricalis* Choisy.

The extent of DNA fragmentation was more in the Paracetamol treated group indicating the liver toxicity and low doses (150mg/kg) of extracts showed slight DNA fragmentation indicating minimum hepatoprotection compared to that of the control and standard group. In silymarin treated

group the DNA was found to be intact, and the high doses (300mg/kg) of the BP extracts treated group the DNA was intact with absence of fragmentation indicating the hepatoprotection against paracetamol induced hepatotoxicity.

## DNA Fragmentation

**Fig 10. Gel picture of DNA Fragmentation Assay of liver of animals treated with *Convolvulus pluricaulis* Choisy**



- 1.NC2
- 2.SS2
- 3.PCM
- 4.AECP1 (100 mg/kg)
- 5.AECP2 (300 mg/kg)
- 6.CECP1 (150mg/kg)
- 7.CECP2 (300mg/kg)
- 8.AqCP1 (150 mg/kg)
- 9.AqCP2 (300 mg/kg)

## DISCUSSION

- By the administration of Paracetamol the contents of mitochondria are lost and DNA is fragmented due to endonucleases, which are responsible for breakdown of the DNA strands and this DNA fragmentation is considered as an indirect marker of Mitochondrial injury. (Mitchell R M, *et al.*, 2012, Laura *et al.*, 2003)
- In the present study the prescribed above events occurred in the Paracetamol treated group. The presence of the nuclear DNA fragments were observed in the tissues of rats treated with Paracetamol providing an evidence of mitochondrial damage and loss of tissue function which also supports the increased levels of serum enzymes like SGOT, SGPT, ACP, ALP etc.
- Further, the DNA fragmentation was secured by showing an intact DNA in rats treated with Alcoholic, Chloroform and Aqueous extracts of *Convolvulus pluricalus* Choisy that is contributing to the protection of mitochondrial oxidative stress. Hence the plant *Convolvulus pluricalus* Choisy is protecting the DNA from the fragmentation due to toxicity.

## Conclusion

The incidence of viral hepatitis is high in developing and developed countries, hence an effective hepatoprotective agent from the natural source must be investigated such a promising effect is seen by the plant *Convolvulus pluricalus* Choisy. From the results obtained it was understood that the serum biochemical parameters which were elevated due to hepatic damage induced by Paracetamol were brought down in the Alcoholic, Chloroform and Aqueous extracts of CP treated groups. Almost all the extracts had similar performance with a

slight variation in reducing the levels of serum biochemical parameters. Among these three extracts, Alcoholic extract of CP had exhibited better activity against the Paracetamol induced hepatotoxicity in a dose dependant manner. Histopathological studies revealed that, when treated with Paracetamol liver showed necrosis and steatosis being variable and degeneration of hepatocytes. When Aqueous, Chloroform, and Alcoholic extracts were administered priorly before Paracetamol administration the central vein and portal tract were clear with normal lobular architecture and no necrosis is seen indicating the hepatoprotective action of extracts of *Convolvulus pluricalus* Choisy. Further, the DNA fragmentation was secured, which showed an intact DNA in rats treated with Alcoholic, Chloroform and Aqueous extracts of *Convolvulus pluricalus* Choisy that is contributing to the protection of mitochondrial oxidative stress. In conclusion, the results obtained in the present study suggest that *Convolvulus pluricalus* Choisy possesses a promising hepatoprotective. However, further studies on other models and extensive clinical trials are needed to confirm the possibilities of the extract in the treatment of various liver disorders.

## REFERENCES

- Asim AK, Syed SN, Raheela J. 2013. Preliminary pharmacognostical, physico-chemical and phytochemical investigations of *Convolvulus Pluricaulis* Choisy. *Intl J of Analy Pharm Biomed Sci.*, 2(3): 1-5.
- Barak FSK, Sharma VN, 1966. Preliminary pharmacological studies on *Convolvulus pluricaulis* Choisy: *An Indian indigenous herb.* *Ind J Physiol Pharmacol.*, 9(2): 99-102.
- Bessemis JG and Vermeulen NP. 2001. Paracetamol (acetaminophen)-induced toxicity: molecular and biochemical mechanisms, analogues and protective approaches. *Crit Rev Toxicol.*, 31: 55-138.
- Buettner GR. Antioxidant enzymes and functions. 1-20 (2005). Available from: URL: <http://www.antioxidantenzyme/buertner/tnu.htm> 2000.
- Bull H, Murray PG, Thomas D, Fraser M, Nelson PN. 2002. Demystified Acid phosphatases. *Mol Pathol* 55(2): 65-72.
- Burtes CA, Ashwood ER. 1986. Textbook of clinical chemistry Philadelphia. WB Saunders Company 56.
- Chaturvedi M, Mali PC, Dixit VP. 1997. Hypolipidaemic effect of *Convolvulus microphyllus* on cholesterol fed gerbils. *J Phytological Res.*, 8(2): 153-55.
- Dinesh D, Rekha V. 2007. Evaluation of the antidepressant-like activity of *Convolvulus pluricaulis choisy* in the mouse forced swim and tail suspension tests. *Med Sci Mont.*, 13(7): BR155-161.
- Eswar KK, Harsha KN, Sudheer V, Giri N. 2013. In vitro antioxidant activity and in vivo hepatoprotective activity of aqueous extract of *Allium cepa* bulb in ethanol induced liver damage in Wistar rats. 2 (3-4): 132-138.
- Ghouri N, Preiss, David Sattar, Naveed. 2010. Liver enzymes, nonalcoholic fatty liver disease, and incident cardiovascular disease: a narrative review and clinical perspective of prospective data. *Hepatology* 52 (3): 1156-1161.
- Gujral JS, Knight TR, Farhood A, Bajt ML, and Jaeschke H. 2002. Mode of cell death after acetaminophen overdose in mice: apoptosis or oncotic necrosis. *Toxicol Sci.*, 67: 322-328.

- Gupta RC, Mudgal V. 1974. Anti-fungal effect of *Convolvulus pluricaulis* (Shankapushpi). *J Res Indian Med.*, 9(2): 67-68.
- Henderson AR, Moss DW. 2001. Enzymes Tietz Fundamentals of Clinical Chemistry, 5th Ed., Burtis, C.A. & Ashwood, E.R. (W.B. Saunders eds. Philadelphia USA) 352.
- Jain SP, Teckade AR, Joshi UM. 2005. Protective effect of *Gingiko Biloba* on Antitubercular drugs induced hepatotoxicity in rats. *Indian Drugs*, 42 (3): 167-70.
- Jayashree P Joshi, Jayashree P Kamat, Mohan G H, Chintalwar, Chattopadhyay S. 2004. BARC ewslatter 249: 183-187.
- Powell, W. 1994. Modified jendrassik and Grof's Method. *Am J Clin Path.*, 8: 55.
- King E J, Jagatheesan KA. 1959. Acid Phosphatase. *J Clin Path.*, 12: 85.
- Laura P J, Philip R M, Jack A H. 2003. Acetaminophen induced Hepatotoxicity. *Drug metabolism and disposition*. 31(12): 1499-1506.
- Lawson JA, Fisher MA, Simmons CA, Farhood A, Jaeschke H. 1999. Inhibition of Fas receptor (CD95)-induced caspase activation and apoptosis by acetaminophen in mice. *Toxicol Appl Pharmacol.*, 156: 179-186.
- Litovitz TL, Klein-Schwartz W, Rodgers GC, Cobaugh DJ, Youniss J, Omslaer JC, May ME, Woolf AD, Benson BE. 2001. Annual report of the American Association of Poison Control Centers Toxic Exposure Surveillance System. *Am J Emerg Med.*, 20: 391-452.
- Meenakshi S, Srivastava SK, Kumar TRS, Ateeque Ahmad, Merajuddin Khan, Khanuja SPS. 2006. Activity guided isolation of antibacterial agents from *Convolvulus pluricaulis*. *J Med Aromatic Plant Sci.*, 28(1): 1-4.
- Michael D, Leise MD, John J, Poterucha MD, Jayant A, Talwalkar MD. 2014. Drug-Induced Liver Injury Mayo Clinic Proceedings 95-106.
- Mitchell JR, Jollow DJ, Potter WZ, Gillette JR, Brodie BB. 1973. Acetaminophen-induced hepatic necrosis IV, Protective role of glutathione. *J Pharmacol Exp Ther.*, 187: 211-217.
- Mitchell RM, Matthew RS, David CW, Mohammed T, Steven CC, Hartmut J. 2012. The mechanism underlying acetaminophen induced hepatotoxicity in humans and mice involves mitochondrial damage and nuclear DNA fragmentation. *J Clin. Invest*, 122(4): 1574-1583.
- Nelson SG, Wan Z, Stan MA. 2002. S(N) 2 ring opening of beta-lactones: an alternative to catalytic asymmetric conjugate additions. *J Org Chem.*, 67: 4680-4683.
- Nyblom H, Berggren U, Balldin J, Olsson R. 2004. High AST/ALT ratio may indicate advanced alcoholic liver disease rather than heavy drinking. *Alcohol Alcohol* 39(4): 336-339.
- Nyblom H, Bjornsson E, Simrén M, Aldenborg F, Almer S, Olsson R. 2006. The AST/ALT ratio as an indicator of cirrhosis in patients with PBC. *Liver Int.* 26 (7): 840-845.
- Parul A, Bhawna S, Amreen F, Sanjay K J. 2014. An update on Ayurvedic herb *Convolvulus pluricaulis* Choisy. *Asian Pac J Trop Biomed* 4(3): 245-252.
- Pawar SA, Dhuley JN, Naik SR, 2001. Neuropharmacology of an extract derived from *Convolvulus microphyllus*. *Pharm Biol.*, 39(4): 253-58.
- Rajesh MG, Latha MS. 2004. Preliminary evaluation of the antihepatotoxic activity of Kamilari, a polyherbal formulation. *J Ethnopharmacol.*, 91: 99-104.
- Sairam K, Rao CV, Goel RK. 2001. Effect of *Convolvulus pluricaulis* Choisy on gastric ulceration and secretion in rats. *Indian J Exp Biol* 39(4): 350-354.
- Sallie R, Tredger JM, Williams R. 1991. Drugs and the liver. Part 1: Testing liver function. *Biopharm Drug Dispos* 12: 251-9.
- Sharma VN, Barar FSK, Khanna NK, Mahawar MM. 165. Some pharmacological actions of *Convolvulus pluricaulis* Choisy: An Indian indigenous herb. *Ind J Med Res.*, 53(9): 871-876.
- Singh MP, Panda H. 2005. Medicinal herbs with their formulations 1st ed. Daya Publishing House: Delhi 1: 286-87.
- Sristi V, Vijay S, Shivani T. 2012. Pharmacognostic validation of whole plant of *Convolvulus pluricaulis* choisy (convulvulaceae) *Int J Pharm Pharm Sci.*, 4(1): 241-246.
- Tietz NW. 1995. Clinical guide to laboratory tests, 3rd Ed, W.B. Saunders eds. Philadelphia USA. 76.
- Tietz NW. 1976. Fundamentals of Clinical Chemistry. WB Saunders and Company, Philadelphia, PA 602.

\*\*\*\*\*