



## RESEARCH ARTICLE

### ECCRINE POROCARCINOMA IN A CHILD

**\*Dr. Neha Tyagi, Dr. Sufian Zaheer, Dr. Amit Kumar Yadav, Dr. Ashish Kumar Mandal and Dr. Himani Bhankar**

Department of Pathology, VMMC & Safdarjung Hospital, New Delhi, India

#### ARTICLE INFO

##### Article History:

Received 10<sup>th</sup> May, 2016  
Received in revised form  
23<sup>rd</sup> June, 2016  
Accepted 18<sup>th</sup> July, 2016  
Published online 20<sup>th</sup> August, 2016

##### Key words:

Eccrine porocarcinoma, Malignant tumour.

Copyright©2016, Dr. Neha Tyagi et al. This is an open access article distributed under the Creative Commons Attribution License, which permits unrestricted use, distribution, and reproduction in any medium, provided the original work is properly cited.

Citation: Dr. Neha Tyagi, Dr. Sufian Zaheer, Dr. Amit Kumar Yadav, Dr. Ashish Kumar Mandal and Dr. Himani Bhankar, 2016. "Eccrine porocarcinoma in a child", *International Journal of Current Research*, 8, (08), 36097-36099.

#### ABSTRACT

Eccrine porocarcinoma is a rare malignant tumour of the sweat glands. It is most commonly seen in elderly individual and it mostly involves lower extremities. It can arise de novo or from pre-existing eccrineporoma. We report a case of Eccrine porocarcinoma in a 13 year old boy over lateral aspect of face.

## INTRODUCTION

Eccrine porocarcinoma is a rare malignant tumour of sweat gland arising from the terminal cells of intraepithelial portion of eccrine duct (acrosyringium). Primary adenocarcinoma arising from eccrine sweat glands accounts only 0.005% of epithelial cutaneous neoplasm (Vandeweyer *et al.*, 2006). The first case was reported in 1963 by Pinkus and Mehregan and they named it as "epidermotropiceccrine carcinoma" and since then presentation has been limited due to rarity of this tumour. The term "Eccrine porocarcinoma" was introduced by Mishma and morioka in 1969 (Oliver Chang *et al.*, 2011). It is usually located in the lower extremities (more than 50%), but may occur on scalp, face and ear (less than 20%), upper extremities (11%) and trunk and abdomen (9%) (Asghar H Asghar *et al.*, 2009). It can arise de novo or from pre-existing eccrineporoma (Manimaran *et al.*, 2014). We report a case of Eccrine porocarcinoma in a 13 year old child.

#### Case report/Result

A 13 year old boy presented with a painful swelling over lateral aspect of face since two years. On examination, a nodular swelling of 3X2cm was noted. Overlying skin was ulcerated at places. Excisional biopsy was done and we received a skin

covered soft tissue piece measuring 3.5X3X2cm. Histopathological examination revealed a nodular tumour arising from epidermis and going into deeper dermis and subcutaneous tissue (Fig 1). The cells were round to polygonal with vesicular nucleus. Mitotic rate was 2-3/hpf including atypical ones. Tumour showed no evidence of keratinization. Immunohistochemistry was done and cells were EMA,CK7 (Fig. 2) positive and negative for S-100, HMB-45, LCA, Desmin, CD10 and CD99. Final diagnosis of Eccrine porocarcinoma was made.

## DISCUSSION

Eccrine glands develop directly from the embryonic epidermis in early months of foetal development (Serhrouchini *et al.*, 2013). Eccrine porocarcinoma is a rare cutaneous neoplasm arising from cells of acrosyringium with metastatic potential. It can manifest clinically as a solitary lesion with non characteristic macroscopic appearance as an ulcerated nodule or as plaque, polypoid or verrucous lesion (Shaw *et al.*, 1982). In our case was a solitary ulcerated nodule. It may arise de novo or develop as a malignant transformation of an eccrineporoma, nevus sebaceous, chronic lymphatic leukemia and actinic lesions (Roshani *et al.*, 2005). It is commonly found in elderly patients and most cases being in 6<sup>th</sup> decade to 7<sup>th</sup> decade of life. Men and women are equally affected (Kuladeepa Ananda Vaidya *et al.*, 2014). In contrast to the literature our case was a 13 year old boy with no pre-existing

\*Corresponding author: Dr. Neha Tyagi,  
Department of Pathology, VMMC & Safdarjung Hospital, New Delhi, India.

lesion. Matloub reported a case of ulcerative porocarcinoma of occipital region involving pericranium. Only 6 cases of Eccrine porocarcinoma have been reported in head and neck region (Matloub *et al.*, 1988). Our case was reported as Eccrine porocarcinoma face, a rare presentation.

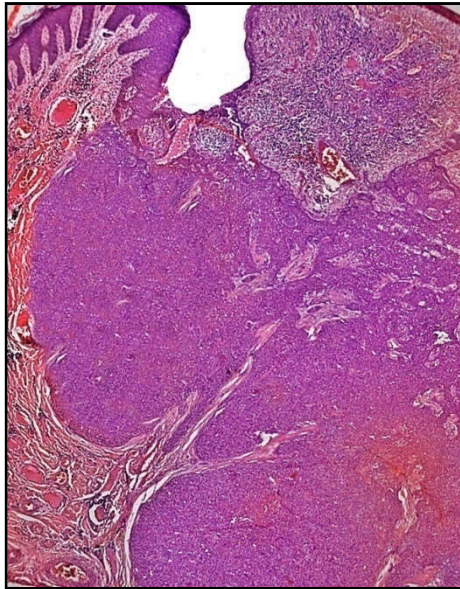


Fig. 1. Epidermal neoplasm extending into dermis (H&E x10)

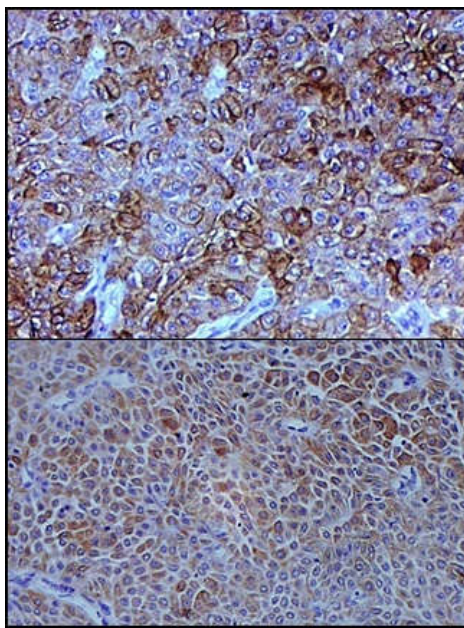


Fig 2(a). Immunopositivity for EMA and Fig 2(b) Immunopositivity for CK 20 (20X)

Histologically, majority of Eccrine porocarcinoma have acanthotic epidermis associated to neoplastic epithelial cells that invade the dermis forming intraepidermal and dermal nests and cords of epithelial cells (Kuladeepa Ananda Vaidya *et al.*, 2014). Some islands of tumour cells may lie free in the dermis and there will be cystic lumina within tumour nests. There is nuclear atypia with frequent mitosis and necrosis (Roshani *et al.*, 2005). Tumour cells have pleomorphic nucleus and clear cytoplasm. Small squamoid cells that form ducts lined by

cuticle are often found (Fung, 1999). Because of staining of Eccrine porocarcinoma cells with CEA, the lumen and the cytoplasm of the malignant glands are mostly demonstrated. Positive staining with PAS/dPAS and/or CEA/EMA or cytokeratins may also be detected without observation of eccrine ducts under light microscopy (11). Immunohistochemistry in our case was CK 7 and EMA positive. It was negative for S-100,CK20,CD10,HMB-45,CD99, desmin and CD117. Histological findings predictive of the aggressive clinical course were the evidence of lymphovascularinvasion, existence of >14 mitosis per field and a tumoral depth of >7mm (Robson *et al.*, 2001). In our case lymphovascular invasion was not seen, mitosis was 2-3/hpf and tumour depth was 2.5cm. Histopathologically, differentials include metastatic adenocarcinoma, trabecular carcinoma, merkel cell carcinoma, basal cell carcinoma, amelanotic melanoma and verruca vulgaris (Elder *et al.*, 2008). Treatment is wide local excision. Prophylactic lymph node dissection is sometimes considered if porocarcinoma is poorly differentiated and if there is any intra-lymphatic permeation. Radiotherapy is not of much help. In case of metastasis, combination chemotherapy with doxorubicin and cyclophosphamide has been used (Fung, 1999).

### Conclusion

Eccrine porocarcinoma is a rare tumour clinically commonly misdiagnosed, hence histopathological evaluation of all skin tumours is required for better and specific treatment.

### Acknowledgements

None

### REFERENCES

- Asghar H Asghar, HumeraMahmood, MohammadFaheem, SadiaRizvi, Khursheed A Khan, JavaidIrfan, 2009. Porocarcinoma: A rare sweat gland malignancy. *Journal of College of Physicians and Surgeons Pakistan*, 19(6):389-90.
- DenizArslan, Ali Murat Tatlı, MukreminUysal, Muhammet ali Kaplan. 2013. Eccrine porocarcinoma: A Case report and review of literature. *JCEI*, 4(3):370-73.
- Elder DE, Lenitsas R, Johnson BL, Murphy GF. 2008. *Lever's Histopathology of skin*. 10<sup>th</sup> edition, Philadelphia. Lippincott Williams and Wilkins, 1154-55.
- Fung, Y P. 1999. Eccrine porocarcinoma of face. *Hongkong Dermatology & Venereology Bulletin*. 2:71-3.
- Kuladeepa AnandaVaidya and MedhaShankarling. 2014. Eccrine porocarcinoma of skin:A rare case report with review of literature. *Sch J App Med Sci.*, 2(1):125-27.
- Manimaran D, ThulasiRaman, Hemanathan G, Ishwarya S, Anuradha S. 2014. Eccrine porocarcinoma associated with eccrineporoma. *Online J Allied Scs.*, 13(2):5.
- Matloub HS, Cunningham Mw, Yousif NJ, SangerJ R, Romano JA. 1988. Eccrine porocarcinoma. *Ann Plast Surg.*, 20:351-5.
- Oliver Chang, Asraf Elnawawi, Bernard Rimpel, Armand Asarian, Nadeem Chaudhry, 2011. Eccrine porocarcinoma of the lower extremity: A case report and review of literature. *World Journal of Surgical Oncology*, 9:94-6.

- Robson A, Greene J, Ansari N, Seed PT, Mckee PH. 2001. Eccrine porocarcinoma: A clinicopathological study of 69 cases. *Am J Surg Pathol.*, 25:710-20.
- Roshani E, Sachin S, Vinita A, Amresh S. 2005. Sweat gland tumour (Eccrine porocarcinoma) of scalp. *Indian J Plastic Surg.*, 38(1):51-3.
- Serhrouchini *et al.* 2013. Eccrine porocarcinoma: A rare cutaneous neoplasm. *Diagnostic Pathology*, 8:15-8.
- Shaw M, Mckee PH, Lowe D, Black MM. 1982. Malignant eccrine poroma: A study of 27 cases. *Br J Dermatol.*, 107:675-80.
- Vandeweyer E, C Renoirte, S Musette, A Gilles. 2006. Eccrine porocarcinoma: A case report. *Acta cherbelt*, 106:121-3.

\*\*\*\*\*