



## RESEARCH ARTICLE

### COMPARATIVE EVALUATION OF EFFICACY OF PLATELET RICH PLASMA AND PLATELET RICH FIBRIN COMBINED WITH BONE GRAFT IN REGENERATION OF BONE IN PERI-IMPLANT DEFECTS- A QUANTITATIVE STUDY

\*<sup>1</sup>Dr. Prithviraj K., <sup>2</sup>Dr. Prof H. P. Raghuvver, <sup>3</sup>Dr. Dilip Kumar, R., <sup>4</sup>Dr. Shobha, E. S.,  
<sup>5</sup>Dr. Prashanth, N. T. and <sup>6</sup>Dr. Vinod Rangan

Department of Oral and Maxillofacial Surgery, Dayananda Sagar College of Dental Sciences, Shavige Mallige Hills, Kumaraswami Layout, Bangalore-560078

#### ARTICLE INFO

##### Article History:

Received 24<sup>th</sup> March, 2016  
Received in revised form  
17<sup>th</sup> April, 2016  
Accepted 05<sup>th</sup> May, 2016  
Published online 30<sup>th</sup> June, 2016

##### Key words:

Freeze dried bone graft,  
True peri implant defect,  
Bone formation.

#### ABSTRACT

**Purpose:** To assess bone regeneration in peri-implant bone defects grafted by demineralized freeze-dried bone graft using platelet-rich plasma and platelet-rich fibrin.

**Methods:** Twenty patients who were to be rehabilitated by implant supported prosthesis were considered for the study. During placement of implants, the implant site was assessed for any peri implant defect and these patients with peri implant defect were divided into two equal groups randomly, one group to receive platelet-rich plasma with bone graft and other group to receive platelet-rich fibrin with bone graft. Immediate and three months post-operative CBCT was taken to compare the bone formation in the peri-implant defect. The CBCT image is screen captured and imported into a picture editing software and linear measurements of the bone is measured.

**Results:** The mean vertical facial bone height formed by using Platelet rich plasma and Platelet rich fibrin with bone graft was  $0.17 \pm 0.19$  mm and  $0.56 \pm 0.38$  mm respectively ( $P = 0.015$ ). The mean value in vertical lingual bone height formed was  $0.15 \pm 0.27$  mm and  $0.72 \pm 0.68$  mm for Platelet rich plasma and Platelet rich fibrin respectively ( $P = 0.033$ ).

**Conclusion:** Based on the results it was concluded that Platelet rich fibrin is efficacious in the treatment of a peri- implant defect.

Copyright©2016, Dr. Prithviraj et al. This is an open access article distributed under the Creative Commons Attribution License, which permits unrestricted use, distribution, and reproduction in any medium, provided the original work is properly cited.

Citation: Dr. Prithviraj K., Dr. Prof H. P. Raghuvver, Dr. Dilip Kumar, R., Dr. Shobha, E. S., Dr. Prashanth, N. T. and Dr. Vinod Rangan, 2016. "Comparative evaluation of efficacy of platelet rich plasma and platelet rich fibrin combined with bone graft in regeneration of bone in Peri-implant defects- A quantitative study", *International Journal of Current Research*, 8, (06), 33464-33470.

## INTRODUCTION

The use of dental implants to replace natural teeth has become commonplace in contemporary restorative and surgical dental practices throughout the world. During the last decade, implantology has become an indispensable part of mainstream dentistry, helping dentists to improve the quality of life of large patient populations. An adequate quantity of bone for implant placement is a prime criteria for long-term successful oral implant rehabilitation. Lack of height and width of bone in the implant site results in an exposed implant surface, with consequent peri-implant defect, decreased bone implant surface, leading to implant failure (Lee *et al.*, 2012). The lack of bone adjacent to an implant can be considered a true "bony defect" (Vijayalakshmi *et al.*, 2012) and several techniques

have been proposed to promote defect fill which helps in new bone formation and long term success of the implants. There are many reasons for a peri-implant bone defect to occur like, bone resorption after tooth extraction reduces height and width of the alveolar crest, bad periodontal condition where there is already a defect in the bone height and width, traumatic bone loss or bone loss due to bone pathology (Simonpieri, Alain *et al.*, 2012). Various technique and materials have been proposed for the management of these inadequate bone volumes. A recent Innovation in dentistry is the preparation and use of Platelet Concentrates (PRP, PRF), a concentrated suspension of growth factors found in platelets (Tozum, TolgaFikret, and BurakDemiralp, 2003; Choukroun, Joseph *et al.*, 2006). Concentrated platelets contain many growth factors including: platelet-derived growth factor (PDGF), transforming growth factor b (TGF-b), insulin-like growth factor (IGF), epidermal growth factor (EGF), fibroblast growth factor (FGF), and bone morphogenic protein (BMP). These growth factors promotes angiogenesis, immune control, stem

\*Corresponding author: Dr. Prithviraj, K.

Department of Oral and Maxillofacial Surgery, Dayananda Sagar College of Dental Sciences, Shavige Mallige Hills, Kumaraswami Layout, Bangalore-560078

cells trapping, and epithelialization which helps in wound healing which are postulated as promoters of tissue regeneration (Kim, Tae-Hoon *et al.*, 2014). These platelet concentrates have been previously tested around dental implants and have been demonstrated to have an osteoregenerative effect on peri-implant bone because of their pro-angiogenic effects and enhancing the differentiating effects on osteoblasts. Demineralized freeze-dried bone graft (DFDBG) is the commonly used allograft which has both osteoinductive and osteoconductive potential and also overcome the drawbacks of autogenous graft materials like longer surgical procedure and morbidity in the donor site<sup>7</sup>. In particular, grafting materials mixed with platelet concentrates (PRP and PRF) has been reported to enhance the osseointegration and particularly favors the physiologic architecture to support the healing process around implants, leading to good quantity and quality of bone formation in peri-implant defects which in turn helps in the long term success of the implant in the rehabilitation of severe functional, anatomical or aesthetic problems arising from tooth loss. Thus the present experimental study was therefore designed for evaluating the efficiency of platelet rich plasma and platelet rich fibrin in combination with Demineralized freeze-dried bone graft in a peri-implant bone defect.

## MATERIALS AND METHODS

The study was done on twenty out patients who visited the Department of Oral & Maxillofacial Surgery, Dayananda Sagar College of Dental Sciences, Bangalore, with single/multiple missing teeth and who were to be rehabilitated by implant supported prosthesis were taken for the study. Patients with uncontrolled systemic illness, previous history of undergoing radiotherapy or chemotherapy were not taken up for the study

### Pre-operative assessment

A standardized Pre-surgical and surgical protocol was followed for all the patients. Pre-operative evaluation of bone height and bone width was done using Cone Beam Computed Tomographic scan in the edentulous areas of the mandible and maxilla for selection of the appropriate implants. The bone height and width measurements were achieved using the "Carestream Dental Imaging Software v6.13.3.3 CS imaging software" (Fov-15x9cm)" using CBCT scans obtained by "KODAK 9500 machine" (10ma 90 Kvp, 200 micron resolution, 10.9sec exposure, 605mgy per cm<sup>2</sup>). Root form implants with lengths ranging from 8 to 16 mm and diameters from 3 to 5 mm were used for the study

### Surgical procedure of implant placement

In all cases Implants were placed under local anesthesia (2 % Lignocaine hydrochloride with 1:2, 00,000 adrenaline). Surgical preparation and isolation of surgical field was accomplished according to standard operative protocols. Surgical template was prepared on the models pre-operatively which was used to identify the implant placement site. A crestal incision was placed and mucoperiosteal flap was reflected and the implant placement site was identified by the

marking made with the aid of the surgical probe through the template. Osteotomy site was prepared using a physiodispenser and Reduction gear hand piece (1:64) with standard sequential drills as per the requirement of the dimensions of the implant. The orientation of osteotomy was checked with paralleling pins. If two or more implants were being placed long axis of the adjacent teeth were used as the reference plane. The Implant was driven into the osteotomy site using the manual torque wrench till the final depth was reached. The cover screw over the implant was placed. After placement of implants into osteotomy site, the implant site was assessed for any peri implant defect and these patients with peri implant defect were divided into two equal groups, one group to receive platelet-rich plasma with bone graft and other group to receive platelet-rich fibrin with bone graft in peri-implant defect area. Patients were selected randomly to be included into these groups.

### Method of preparing platelet rich plasma

5ml of venous blood is drawn from a patient into a citrated sample tube with the help of a syringe. The sample tube is then spun in a standard centrifuge for ten minutes at 2400rpm to produce platelet-poor plasma (PPP) as the top layer and RBC in the lower layer. The platelet-poor plasma is taken up into a syringe with a long cannula. A second centrifugation at 3600rpm for fifteen minutes is performed to concentrate the platelets. The second supernatant is also taken up by a long cannula which is the platelet-rich plasma (Tozum, Tolga Fikret, and Burak Demiralp, 2003).

### Method of preparing platelet-rich fibrin

The 5ml of venous blood is collected into a sterile sample tube with the help of a syringe without an anticoagulant. The sample tube is then spun in a standard centrifuge at 3000rpm for ten minutes. RBC settle into a red lower fraction and the upper straw colored cellular plasma while middle fraction containing the fibrin clot. The fibrin clot 2mm below the lower dividing line of the middle fraction is the platelet-rich fibrin. The collected Platelet Rich Fibrin is placed in a lint free cloth and compressed to obtain a membrane form, for ease of placement in peri-implant defect<sup>5</sup>. Platelet rich plasma thus obtained is in the form of liquid, is mixed with bone graft and is placed in the area of peri-implant defect in group of patients who are selected in PRP group. While patients selected for platelet rich fibrin with bone graft, bone graft is placed in the peri-implant defect and platelet rich fibrin which is obtained in the form of membrane is placed over the bone graft (Fig.1). Flap closure was done using 3-0 vicryl and care is taken to avoid any displacement or dislodgement of the bone graft with platelet rich plasma or platelet rich fibrin. Immediate post-operative CBCT is taken to measure the linear measurements of the bone defect in peri-implant region.

### Post operative procedure

Routine Antibiotics and anti-inflammatory drugs were prescribed along with oral hygiene maintenance instructions. At three months post-operative CBCT was taken and

Radiological assessment was done using CBCT scans done immediately after surgery and three months post-operatively.

### Data reconstruction and image acquisition

Following the CBCT scan, in the axial view, the image was rotated so that the reference line bisected the implant in the faciopalatal direction according to the implant position on the arch. In sagittal plane image is rotated so that the reference line is parallel to the long axis of the implant. Image is screen captured in sagittal plane and imported into a presentation program (Microsoft office 2013) at a resolution of 1920 X 1080 pixels. The lines are drawn using a drawing tools and the measurement of the defects are calculated (Fig – 2).

### Horizontal and vertical bone measurements (Fig. 3)

The line was drawn bisecting the implant along its long axis representing the implant length. A line perpendicular to the implant long axis was drawn at alveolar crest level. Lines were drawn across both facial and lingual sides from the alveolar crest level to the height of alveolar bone which shows the measurement of the bone defect in the peri implant area on facial and lingual sides respectively. Lines were drawn on both facial and lingual side at 6mm from the alveolar crest perpendicular to the long axis of the implant up to the outer border of the cortical plates and these will give the measurements of the horizontal thickness of the facial and lingual bone at 6mm from alveolar crest. The same measurements were taken in immediate post-operative and three months post-operative CBCT scans. Thus for each subject VFBH (vertical defect on facial side), VLBH (vertical defect on lingual side), HFBT and HLBT were evaluated immediately following surgery (T1) and at 3months following implant placement (T2) (Table – 1, 2). Then VFBHF, VLBHF

was calculated by T1- T2 and HFBTF, HLBTF was calculated by T2- T1.

### Statistical analyses

Bone regeneration in peri-implant bony defect grafted by Demineralized freeze-dried bone graft (DFDBG) with platelet-rich plasma was compared with demineralized freeze-dried bone graft with platelet-rich fibrin. The linear measurements obtained were statistically analyzed using student t test. The mean vertical facial bone height formed (VFBHF) by using PRP and PRF with bone graft is  $0.17 \pm 0.19$  mm and  $0.56 \pm 0.38$  mm respectively with  $p = 0.015$ . The mean value in vertical lingual bone height formed (VLBHF) is  $0.15 \pm 0.27$  mm and  $0.72 \pm 0.68$  mm for PRP and PRF respectively with  $p = 0.033$ . For VLBHF and VFBHF there is increased bone regeneration in PRF with bone graft when compared with PRP with bone graft when used in peri implant bone defect. The bone defect on an average in PRF group is 1.28mm on buccal side and 1.23mm on the lingual side while the bone formed is 0.56mm on buccal side and 0.72 mm on lingual side, which shows that there is more amount of bone formed on the lingual side compared to buccal side. The bone defect on an average in PRP group is 1.25mm on buccal side and 0.96mm on the lingual side while the bone formed is 0.16mm on buccal side and 0.14mm on lingual side. In PRF group maximum defect healed was 2.4mm in one case and most of the cases recorded was around 1.0mm, but with PRP there is no such case recorded with any high values, whereas almost all the cases have shown a vertical bone defect healing of  $\leq 0.5$ mm. The horizontal bone thickness formed in PRF and PRP is  $0.30 \pm 0.21$ mm,  $0.38 \pm 0.32$  mm on buccal side and  $0.30 \pm 0.27$  mm,  $0.21 \pm 0.12$  mm on the lingual side. The p value is 0.53 and 0.38 on buccal and lingual respectively which signifies that there is no significant difference in the bone thickness formed by using PRP and PRF with bone graft.

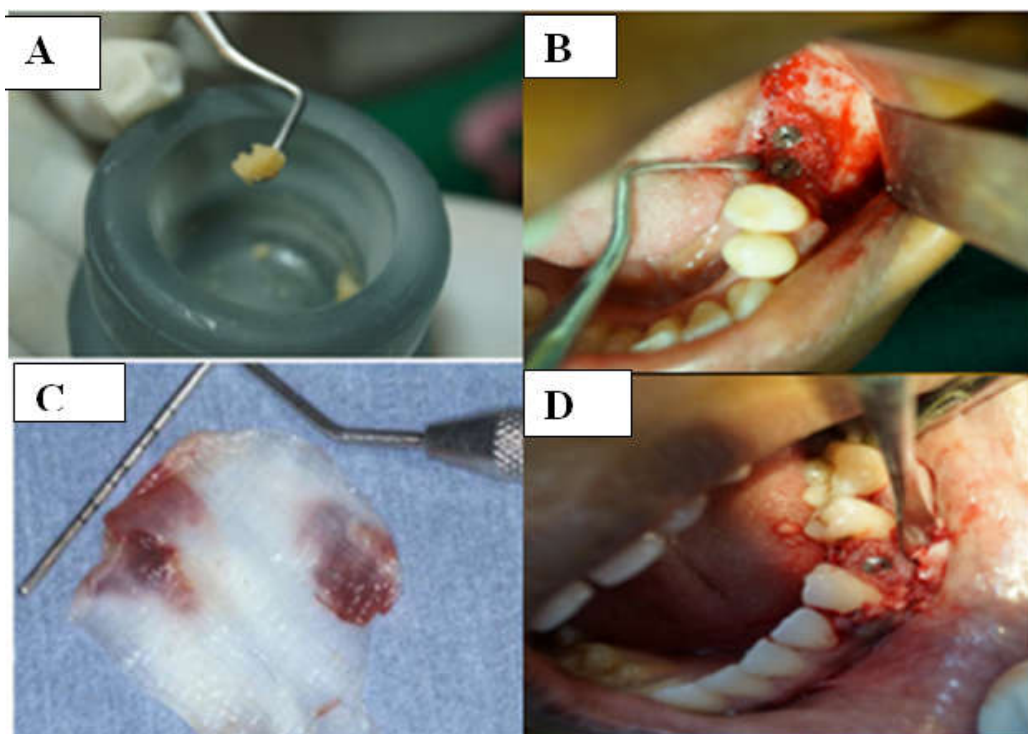


Fig. 1. Placing PRP(A,B) and PRF(C,D) in the Peri implant defect area

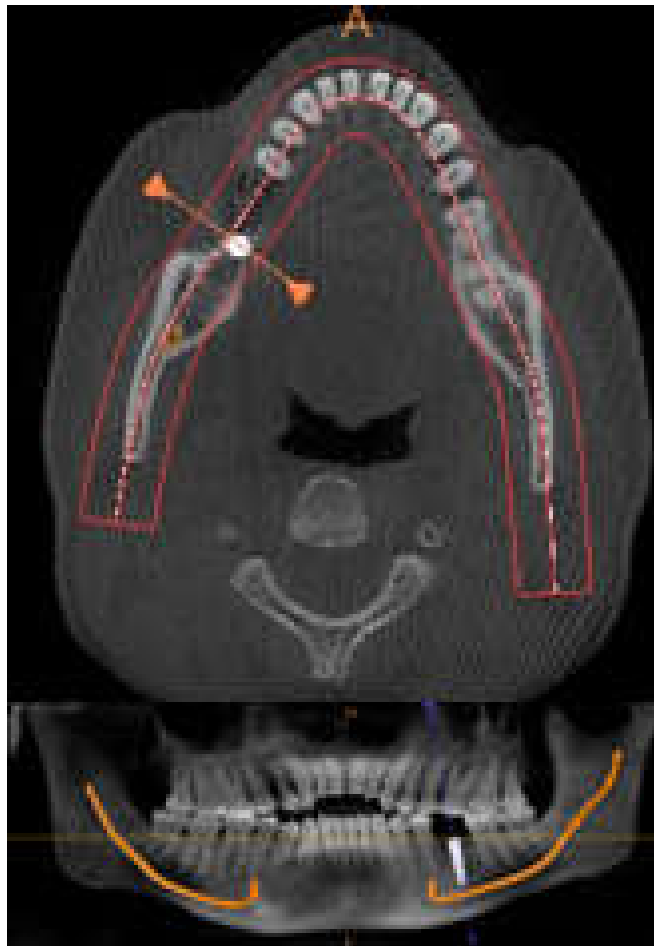


Fig.2. In the axial view sections is taken to measurement

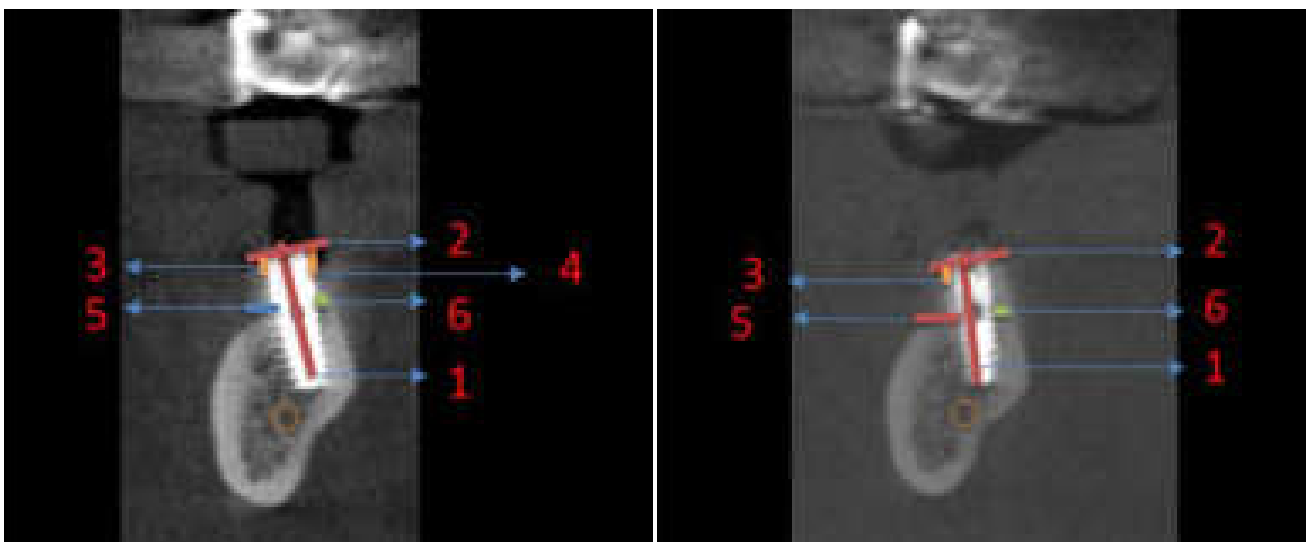
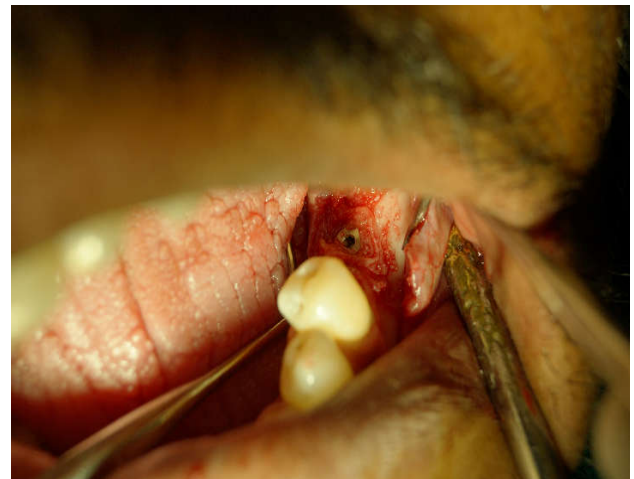
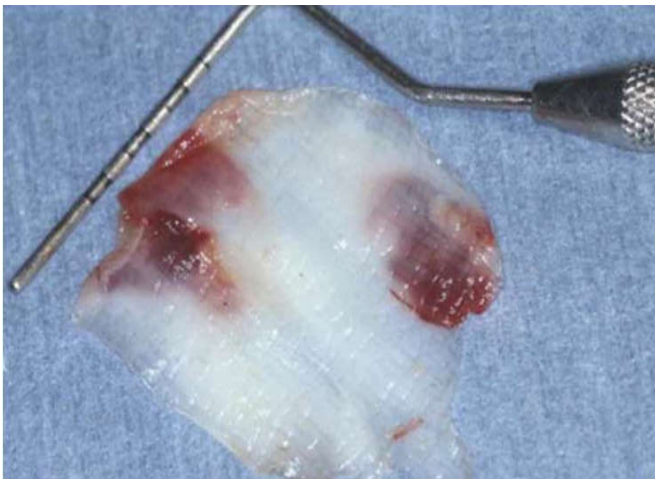
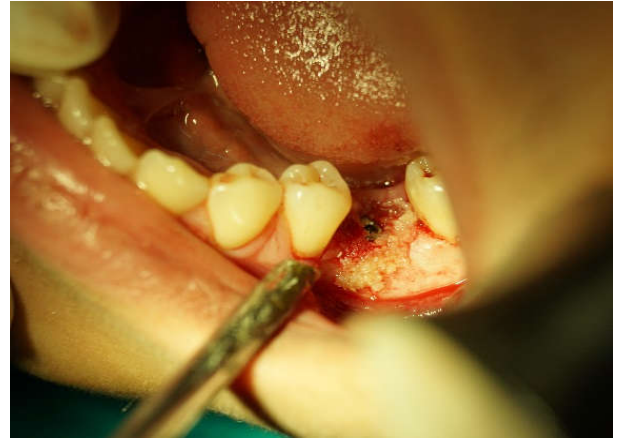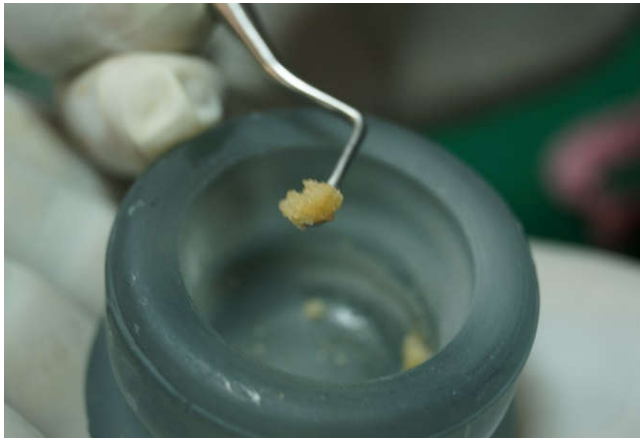Fig. 3. Immediate post operative 3months post operative

1. Line along the long axis of implant
2. Line showing the alveolar crest level
3. Line showing the alveolar bone height from alveolar crest level on buccal side
4. Line showing the alveolar bone height from the alveolar crest level on lingual side
5. Line showing the horizontal facial bone thickness
6. Line showing the horizontal lingual bone thickness





**Table 1. Final values of bone formed in Peri-implant defect using PRP with bone graft**

CASE	IMPLANT SITE	IMPLANT SIZE	VFBHF(in mm) T1-T2	VLBHF(in mm) T1-T2	HFBTF(in mm) T2-T1	HLBTF(in mm) T2-T1
CASE1	35	3.75X13	0.2	0	0.1	0
CASE2	36	3.75X13	0	-0.1	0.1	0
CASE3	36	4.2X11.5	0.5	0	0.3	0.4
CASE4	16	3.75X8	0.1	0	0.4	0.7
CASE5	46	3.75X13	0.1	0.2	0.5	0.5
CASE6	26	3.75X13	0	0.3	0.2	0.5
CASE7	36	4.25X10	0.5	0	0.5	0.1
CASE8	37	4.25X10	0.2	0.2	0	0
CASE9	36	3.75X16	0	0.8	0.6	0.5
CASE10	21	3.75X13	Implant failure			

VFBHF – VERTICAL FACIAL BONE HEIGHT FORMED  
 VLBHF – VERTICAL LINGUAL BONE HEIGHT FORMED  
 HFBTF – HORIZONTAL FACIAL BONE THICKNESS FORMED  
 HLBTF – HORIZONTAL LINGUAL BONE THICKNESS FORMED

**Table 2. Final values of bone formed in Peri-implant defect using Prf with bone graft**

CASE	IMPLANT SITE	IMPLANT SIZE	VFBHF(in mm) T1 – T2	VLBHF(in mm) T1- T2	HFBTF(in mm) T2 – T1	HLBTF(in mm) T2 – T1
CASE1	46	3.75X13	0.9	1.0	0.5	0.1
CASE2	47	3.75X13	0.4	2.4	1.2	0.2
CASE3	36	4.2X16	0	0.9	0.3	0.1
CASE4	26	3.75X8	0	0.3	0	0.2
CASE5	14	3.75X13	1.0	0.6	0.2	0.4
CASE6	16	3.75X8	0.7	0.5	0.5	0.3
CASE7	34	3.3X13	0.3	0	0.3	0.2
CASE8	36	3.75X13	1.0	0.7	0.2	0
CASE9	37	3.75X11	0.8	0.8	0.4	0.2
CASE10	46	3.75X10	0.5	0	0.2	0.4

VFBHF – VERTICAL FACIAL BONE HEIGHT FORMED  
 VLBHF – VERTICAL LINGUAL BONE HEIGHT FORMED  
 HFBTF – HORIZONTAL FACIAL BONE THICKNESS FORMED  
 HLBTF – HORIZONTAL LINGUAL BONE THICKNESS FORMED

## DISCUSSION

Most preferred and common method of rehabilitation of edentulous area has been a partial or full denture, but low mastication efficiency of these prosthetic replacement compared with natural dentition makes a dental implant supported prosthesis reliable substitute. Many patients do not have an ideal alveolar ridge condition, because alveolar bone is resorbed after a loss of a tooth, periodontal and traumatic bone loss which lead to a peri implant defect while placing implant. Studies demonstrated that vertical and horizontal dimensions are reduced around 11–22% and 29–63%, respectively, due to alveolar resorption after 6 months following tooth extraction. To have a good implant success, good quantity and quality of bone is required for which various techniques, including bone grafts and guided tissue regeneration techniques have been proposed. Regenerative potential of platelets was studied by Ross *et al.* (1974). They were amongst the pioneers who first described growth factors from platelets. Growth factors released after activation from the platelets trapped within fibrin matrix, and have shown to stimulate the mitogenic response in the periosteum for bone repair during normal wound healing<sup>8</sup>. Last two decades has seen the better understanding of physiologic properties of platelets in wound healing that led to an increase in the therapeutic applications of various forms with varying results. Knowledge about growth factors and wound healing has been enhanced by the development of an autologous platelet concentrates (PRP and PRF), which is used in various surgical fields, including head and neck surgery, otolaryngology, cardiovascular surgery, oral and maxillofacial surgery, and in various other specialties of dentistry, to enhance wound healing and regeneration. (Tozum, TolgaFikret and BurakDemiralp, 2003) This autologous plasma is a rich source of growth factors and its application has been reported as an effective way to induce tissue repair and regeneration. (Tozum, TolgaFikret, and BurakDemiralp, 2003) Marx *et al.* first introduced in 1998, the technique of platelet concentration to create the first autologous PRP for its use in dental surgery (Lynch *et al.*, 1999).

It has proved to be an effective osteopromoter in several standard bone regeneration and osseointegration techniques. PRP contains platelet and plasma growth factors involved in the repair process; it also contains sticky plasma proteins such as fibrin, fibronectin, and vitronectin. Some researchers have even reported that the high concentration of transforming growth factor  $\alpha$  (TGF- $\alpha$ ) present in platelets *via* PRP can give rise to better repair of the emerging tissue and to enhanced bone reconstruction. They claim that the growth factors released by platelets play an important role in improving the bone response and in the transformation of marrow bone cells into osteoblasts. PRF is developed in France by Choukroun *et al.* in 2001, The PRF production protocol attempts to accumulate platelets and released cytokines in a fibrin clot. Though platelets and leukocyte cytokines play an important part in the biology of this biomaterial, the fibrin matrix supporting them certainly constitutes the determining element responsible for the real therapeutic potential of PRF. The membranes of PRF are able to simultaneously support the development of these 3 phenomena.

1. Fibrin is the natural guide of angiogenesis
2. Fibrin constitutes a natural support to immunity
3. Fibrin matrix guides the coverage of injured tissues (Choukroun, Joseph *et al.*, 2006)

Recent clinical and histologic findings suggest that the use of platelet concentrates have technical benefits and may enhance bone regeneration when used in conjunction with bone grafts (Pinsky *et al.*, 2006). The amplification of platelet derived growth factor (PDGF) and transforming growth factor (TGF) beta is seen as an available and practical tool for enhancing the rate of bone formation and the final quality of bone formed (Vijayalakshmi, *et al.*, 2012; Kassolis *et al.*, 2000). At present, bone defects are regularly augmented with autogenous bone grafts. The ideal bone graft should present readily available source, lack of morbidity in the donator site, no risk to disease transmission, efficient bone repair, immediate stability, versatility, easy manipulation, appropriate lifetime, and accessible cost. The use of allografts and synthetic materials would result in lower surgical risks and lower morbidity in the augmentation procedure and would represent an important step forward in simplifying bone regeneration techniques. DFDBG which is an allogenic graft material which has both osteoinductive and osteoconductive potential and also overcome the drawbacks of autogenous graft materials like longer surgical procedure and morbidity in the donator site. In a study DFDBG alone and PRF with DFDBG is used to perform sinus floor augmentation to accelerate bone regeneration and allow implant placement, which showed that healing time between sinus graft and implant placement could be considerably reduced by using PRF with DFDBG when compared to DFDBG alone (Choukroun, Joseph *et al.*, 2006). In our study we have used Demineralized freeze-dried bone graft (DFDBG) which is allograft with PRP and PRF.

PRP and PRF are the autologous materials which promote bone healing especially when used in conjunction with allografts. In our study the patients with peri implant defect were identified during implant placement and were randomly divided into two groups. Radiological evaluation of two groups using CBCT scans showed that there is increase in the quantity of bone formed in both PRP and PRF with bone graft groups. The mean vertical facial bone height formed by using PRP and PRF with bone graft is  $0.17 \pm 0.19$  mm and  $0.56 \pm 0.38$ mm respectively. The mean vertical lingual bone height formed by using PRP and PRF with bone graft is  $0.15 \pm 0.27$  and  $0.72 \pm 0.68$  respectively. The results indicate that PRF can induce stronger peri implant bone formation than PRP with bone graft in the treatment of peri implant bone defects around the titanium implants. In a similar experimental study done which used osteoblast cell cultures to investigate the influence of PRP and PRF on proliferation and differentiation of osteoblasts, it was also found that PRF had a superior influence over PRP (He, Ling *et al.*, 2009; Jeong, Kyung-In *et al.*, 2013). However PRF can be used in conjunction with bone grafts, which offers several advantages including promoting wound healing, bone growth and maturation, graft stabilization, wound sealing and hemostasis as well as improving the handling properties of graft materials.

## Conclusion

After comparing the CBCT scans of two groups it can be concluded that regeneration of new bone in peri implant defect is more in the group of patients who have received PRF with bone graft group than in the group of patients who have received PRP with bone graft group. There is a significant difference between two groups in relation to the vertical bone regeneration. Our findings support the use of Platelet rich fibrin along with bone graft in peri implant deficient regions when compared to platelet rich plasma with bone graft. PRF is an autologous preparation and found to be clinically effective and economical than any other available regenerative materials.

## Future recommendations

Our study group consisted of a limited number of patients with a limited follow up period. Hence a more extensive study with more number of patients and a longer period of follow up is required to come to a definitive conclusion.

## REFERENCES

- Choukroun, Joseph *et al.* 2006. 'Platelet-Rich Fibrin (PRF): A Second-Generation Platelet Concentrate. Part IV: Clinical Effects On Tissue Healing'. *Oral Surgery, Oral Medicine, Oral Pathology, Oral Radiology, and Endodontology*, 101.3 e56-e60. Web.
- Choukroun, Joseph *et al.* 2006. 'Platelet-Rich Fibrin (PRF): A Second-Generation Platelet Concentrate. Part V: Histologic Evaluations of PRF Effects on Bone Allograft Maturation In Sinus Lift'. *Oral Surgery, Oral Medicine, Oral Pathology, Oral Radiology, and Endodontology*, 101.3 299-303. Web.
- Gupta, Vivek. 2015. 'Regenerative Potential of Platelet Rich Fibrin in Dentistry: Literature Review'. *Asian Journal of Oral Health & Allied Sciences* 1.1, 22-28. Print.
- He, Ling *et al.* '2009. A Comparative Study Of Platelet-Rich Fibrin (PRF) And Platelet-Rich Plasma (PRP) On The Effect Of Proliferation And Differentiation Of Rat Osteoblasts In Vitro'. *Oral Surgery, Oral Medicine, Oral Pathology, Oral Radiology and Endodontology*, 108.5, 707-713. Web.
- Jeong, Kyung-In *et al.* 2013. 'Effect Of Platelet-Rich Plasma And Platelet-Rich Fibrin On Peri-Implant Bone Defects In Dogs'. *Journal of Biomedical Nanotechnology*, 9.3, 535-537. Web.
- Kassolis JD, Rosen PS, Reynolds MA. 2000. Alveolar ridge and sinus augmentation utilizing platelet rich plasma in combination with freeze dried bone allograft; case series. *J Periodontol.*, 71:1654-61.
- Kim, Tae-Hoon *et al.* 2014. 'Comparison Of Platelet-Rich Plasma (PRP), Platelet-Rich Fibrin (PRF), And Concentrated Growth Factor (CGF) In Rabbit-Skull Defect Healing'. *Archives of Oral Biology*, 59.5, 550-558. Web.
- Lee, Jong-Won *et al.* 2012. 'Restoration of a Peri-Implant Defect by Platelet-Rich Fibrin'. *Oral Surgery, Oral Medicine, Oral Pathology and Oral Radiology*, 113.4, 459-463. Web
- Lynch SE, Genco RJ, Marx RE. 1999. *Quinte; Tissue engineering: Applications in maxillofacial surgery and periodontics*. London: Quintessence Publishing Co, Inc; pp. 71-82.
- Pinsky, HM *et al.* 2006. 'Accuracy Of Three-Dimensional Measurements Using Cone-Beam CT'. *Dentomaxillofacial Radiology* 35.6, 410-416. Web.
- Santos, Pâmela Leticia *et al.* 2013. 'Bone Substitutes For Peri-Implant Defects Of Postextraction Implants'. *International Journal of Biomaterials*, 1-7. Web.
- Simonpieri, Alain *et al.* 2012. 'Current Knowledge And Perspectives For The Use Of Platelet-Rich Plasma (PRP) And Platelet-Rich Fibrin (PRF) In Oral And Maxillofacial Surgery Part 2: Bone Graft, Implant And Reconstructive Surgery'. *Current Pharmaceutical Biotechnology*, 13.7, 1231-1256. Web.
- Tozum, Tolga Fikret, and Burak Demiralp, 2003. 'Platelet Rich Plasma : A Promising Innovation In Dentistry'. *Journal of Canadian Dental Association*, 69.10, 664. Print.
- Vijayalakshmi, R *et al.* 2012. 'Use of Platelet Rich Fibrin in a Fenestration Defect Around An Implant'. *Journal of Indian Society of Periodontology*, 16.1, 108. Web.

\*\*\*\*\*