



ISSN: 0975-833X

Available online at <http://www.journalcra.com>

International Journal of Current Research  
Vol. 8, Issue, 10, pp.39826-39829, October, 2016

INTERNATIONAL JOURNAL  
OF CURRENT RESEARCH

## CASE STUDY

### ZYGOMATIC IMPLANT HOW EFFECTIVE ALTERNATIVE

<sup>2</sup>Fernando Ravazzi, <sup>2</sup>Regis Manzini, <sup>\*</sup><sup>2</sup>Idiberto José Zotarelli Filho,  
<sup>2</sup>Wesley Antonio Galhardo Fornazari and <sup>1,2</sup>Elias Naim Kassis

<sup>1</sup>Unorp - University Center North Paulista - São José do Rio Preto – SP, Brazil

<sup>2</sup>Unipos - Post graduate and Continuing education, Street Ipiranga, 3460, São José do Rio Preto SP,  
Brazil 15020-040

#### ARTICLE INFO

##### Article History:

Received 20<sup>th</sup> July, 2016  
Received in revised form  
22<sup>nd</sup> August, 2016  
Accepted 28<sup>th</sup> September, 2016  
Published online 30<sup>th</sup> October, 2016

##### Key words:

Zygomatic Implant,  
Dental Implant,  
Alternative Success,  
Quality of life.

#### ABSTRACT

**Background:** The lack of bone in the alveolar ridge has been a major problem in aesthetic functional recovery in patients who have suffered traumas dentoalveolar, traumatic dental extractions, dental congenital absence pathologies involving the jaws. Thus, the zygomatic implant is an excellent alternative in the dental implant process with bone loss. Still, the zygomatic implant also applies when there is poor bone quality and quantity.

**Objective:** To show through a case report the success of the zygomatic implant compared to the previous failure and graft osseointegration. Case report: Patient MFSS did 2 years ago treatment for placement of dental implants and grafts had already done more than once without success osseointegration. Thus, the conduit was to perform a surgical repair to remove any material in the sinuses and zygoma implants fixation.

**Results and Discussion:** The results presented by the patient of this study showed success in the zygomatic implant, consistently to literature results. Also remained stable in the implant and considerable improvement in quality of life after tracking a year and a half.

**Conclusion:** it was concluded that the patients in this study showed success in the zygomatic implant. Also remained stable in the implant and considerable improvement in quality of life after tracking a year and a half.

*Copyright © 2016, Fernando Ravazzi et al. This is an open access article distributed under the Creative Commons Attribution License, which permits unrestricted use, distribution, and reproduction in any medium, provided the original work is properly cited.*

**Citation:** Fernando Ravazzi, Regis Manzini, Idiberto José Zotarelli Filho, Wesley Antonio Galhardo Fornazari and Elias Naim Kassis, 2016. "Zygomatic implant how effective alternative", *International Journal of Current Research*, 8, (10), 39826-39829.

## INTRODUCTION

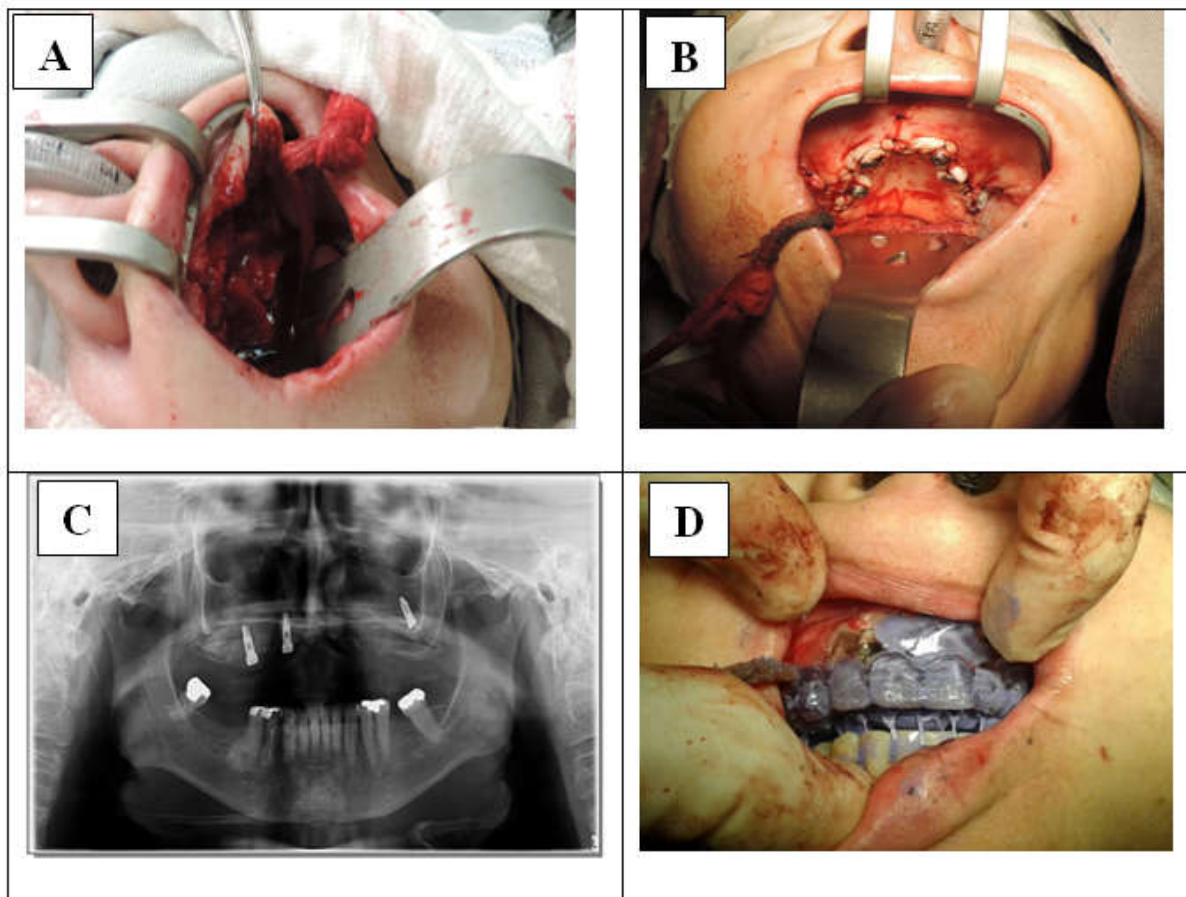
The lack of bone in the alveolar ridge has been a great problem in practical aesthetic recovery in patients who have suffered traumas dentoalveolar, traumatic extractions, congenital dental absence pathologies involving the maxilla and mandible, infections due to emotional consequences and the possibility of deformity (Wu *et al.*, 2015; Lopes *et al.*, 2015; Ozaki *et al.*, 2015). Thus, the edentulousness impacts negatively the quality of life, which are compromised aesthetic functions, such as smile and functional, such as chewing and speech. Thus, the partial or total absence of teeth is a social problem and public health worldwide (Ozaki *et al.*, 2015; Takamaru *et al.*, 2015). As a consequence, loss of teeth carries with progressive bone resorption, principally in the posterior maxillary sector. Similarly, the functional feature which further complicates the rehabilitation sector is the intensive forces generated during mastication on this anatomical region (Takamaru *et al.*, 2015).

**\*Corresponding author: Idiberto José Zotarelli Filho,**  
Unipos - Post graduateandcontinuingeducation, Street Ipiranga, 3460,  
São José do Rio Preto SP, Brazil 15020-040.

Thus, the zygomatic implant is an excellent alternative in the dental implant process with bone loss (Monteiro *et al.*, 2015). The zygomatic implant is long, threaded, oxidized and moderately rough, with lengths ranging from 30 to 52.5 mm. They have an inclined head that is designed to allow placement of the prosthesis 45 along the axis of the implant, providing an excellent ability to retain, support and stabilize the prosthesis while minimizing the leverage (Yates *et al.*, 2014; Goiato *et al.*, 2014; Fernandez *et al.*, 2014). The format of the neck is of greater width at the level of the alveolar crest, apical part of 4.0 mm diameter and crystal of 4.5 mm in diameter. Further, the zygomatic implant also applies when there is a poor bone quality and quantity, are required when large bony reconstructions, in the case of the maxillary sinus pneumatized exacerbated or even if there are large tumor recessions (Aparicio *et al.*, 2014). However, there may be complications with zygomatic implants. Complications arising from placing a zygomatic implant can be classified as intra-oral and extra-oral (Chrcanovic and Abreu, 2013; Ugurlu *et al.*, 2013; Balshi *et al.*, 2012; Rodriguez *et al.*, 2012). The intraoral can be oro-antral fistula, chronic gingivitis around the implant, the buccal

cortical fenestration, implant loss, intracranial penetration and has the extra-oral may be sinusitis acute maxillary or chronic, malar subcutaneous emphysema, nerve paresthesia infraorbital and facial zygomatic, Infection and inflammation of the soft tissue defects and transient nerve sensitivity (Balshi *et al.*, 2012; Rodriguez *et al.*, 2012). In the literature they cited two cases of adult siblings toothless, with severe alveolar bone atrophy and were treated with bone graft and zygomatic implant. Although there is no evidence of moderate resorption in the jaw bone graft, bone augmentation procedures were successful in 2 patients. After implantation, the functional and aesthetic results of oral rehabilitation were acceptable. More importantly, the restoration of oral function of the patients improved their quality of life (Wu *et al.*, 2015). Also proved to be a case of functional rehabilitation and aesthetics with maxillary prosthesis supported by only two zygomatic implants for a patient who suffered maxillectomy subtotal for malignant melanoma of the upper gum. Six months after tumor resection, two zygomatic implants were inserted into bilateral zygomatic bones. After application of these implants, prosthesis retention and stability was considerably improved. The patient became able to eat a normal diet. Moreover, the upper lip depressed was also restored suitably (Ozaki *et al.*, 2015). This study aimed to show through a case report the success of the zygomatic implant compared to the previous failure and graft osseointegration.

osseointegration. In addition, he also reported that he felt pain and discomfort in the naris and bad taste in the mouth. Still, in the first visit to MFSS had nasal discharge and Valsalva maneuver, much pus by aroantral communication. Image complemetares tests were requested (Cone Beam CT and RX Widescreen). The images was found lot of block graft in both breasts and deploy floating in the left side of the breast, one implateosteointegrated the right canine fossa and acute purulent sinusitis. Thus, the conduit was to perform a surgical repair to remove any material in the sinuses and zygoma implants fixation. As for the clinical examination, medical history should make indication of the general health of the patient according to the ASA (American society of anesthesiology) and its classification system (ASA ASA I to V). With regard to history, we assessed the following aspects: immunosuppression, cardiovascular conditions, liver disease and diabetes. The clinical history researched is still smoking habits, alcohol consumption and drug abuse. Tests were requested preoperative imaging and laboratory. The surgery was performed in hospital under general anesthesia with tracheal nasal tube, the cavity cleaning and implant placement, molding surgical guide and installation of the prosthesis in a week, it was conducted several returns and eight months was placed the final prosthesis. In follow up was made a clinical research that is based on the assessment of pain, infections, implant stability, card control and inflammation.



**Figure 1.** Images showing the graft remains cleaning process (A), the zygomatic implant (B), radiographic examination (C) and tooth placement (D)

### Case Report

The patient MFSS did 2 years treatment for placement of dental implants and grafts had done more than once without success

Occlusal adjustments were made after one week and then the first, third and ninth month, continuous from year to year checks. It was also recommended a soft diet for four months, proper oral hygiene and careful rinsing with chlorhexidine after each meal.

## RESULTS

The patient had success from the process of the zygomatic implant until after 1½ years of follow up, without presenting considerable complications (Figure 1). Furthermore, after application of these implants, retention and stability of the prosthesis was significantly improved. The patient was able to eat a normal diet and also the upper lip depressed was also restored properly. Thus, there was significant improvement in patient quality of life of the present study.

## DISCUSSION

The results presented by the patient of this study showed success in the zygomatic implant, befitting the literature results. Also remained stable in the implant and considerable improvement in quality of life after tracking a year and a half. Thus, the zygomatic implant, although it may also have complications and risks, is a strong alternative to achieve success in the dental implant process in patients with significant bone loss. The amount of zygomatic bone is intrinsic to each patient, and remains, largely independent of age or loss of teeth. Alongside this statement, the zygomatic features a compact and regular trabecular bone with 98% density. The proper occlusal stress caused by the forces is supported by implanting transferred mainly through the crest and below the zygomatic process divided into the frontal and temporal zygomatic bone (Wu *et al.*, 2015; Lopes *et al.*, 2015). The contact bone / implant is referred to as BIC (bone-implant-contact) and is correlated with the survival of the implant. Digital and simple measurement of BIC proceeds to the export of postoperative CT scan of a cone beam and the subsequent measurement of the apical portion of the zygomatic implant contact the zygomatic bone. (Ozaki *et al.*, 2015) Thus, as a justification of the above, male patient has a BIC zygomatic bigger than a female patient gender. Another variable that changes the BIC zygomatic is the angle that the implant is placed (Takamaru *et al.*, 2015; Monteiro *et al.*, 2015; Yates *et al.*, 2014). In accordance with the change of angle, the implant contacts with different anatomical portions of the fractured bone, which can lead to increased or decreased BIC. The insertion angle is estimated by preoperative tests of computed tomography (Goiato *et al.*, 2014; Fernandez *et al.*, 2014; Aparicio *et al.*, 2014). According Balshi *et al.* (2012) there is a need to develop criteria to evaluate the bone-implant contact in the zygomatic area, since this parameter in this region is difficult. Thus, the BIC is an important study topic, since a greater understanding of this involves a better understanding of the factors relating to osseointegration. From the loss of a tooth regardless of its cause as caries, periodontal disease or trauma there is the beginning of bone resorption, leading to complex docking problems (Chrcanovic and Abreu, 2013; Ugurlu *et al.*, 2013; Balshi *et al.*, 2012; Rodriguez *et al.*, 2012). The lack of alveolar bone may prevent the retention of a conventional prosthesis anchoring this can only be achieved by means of osseointegration (Candel *et al.*, 2012; Anandakrishna and Rao, 2012; Bidra and Huynh-Ba, 2011; Aparicio *et al.*, 2010). In 1990, Branemark introduced a technique called the zygomatic attachment (Stievenart and Malevez, 2010). The goal was to achieve these new implants a fixation in the zygomatic bone dense and thus rehabilitate these areas, in combination or not with other types of implants (Malo *et al.*, 2008; Rodríguez-Ciurana *et al.*, 2008; Galan Gil *et al.*, 2007). This new protocol was first developed in a multicenter study and obtained a high survival rate (Stievenart and

Malevez, 2010; Vrielinck *et al.*, 2003; Aparicio *et al.*, 2001). Thus, the zygomatic implant provides anchorage because cross the maxillary tuberosity, pass through the pyramidal apophysis of the palatine bone and are part of the pterygoid apophysis of the sphenoid bone, thus enabling the success of the implants.

## Conclusion

It was concluded that the patients of this study had success in the zygomatic implant. Also remained stable in the implant and considerable improvement in quality of life after tracking a year and a half.

## REFERENCES

- Anandakrishna, G.N., G. Rao 2012. Pterygomaxillary implants: a graftless solution to deficient maxillary bone. *J Indian Prosthodont Soc*, 12(3): p. 182-6. 11.
- Aparicio, C., *et al.* 2010. Immediate/Early loading of zygomatic implants: clinical experiences after 2 to 5 years of follow-up. *Clin Implant Dent Relat Res.*, 12 Suppl 1: p. e77-82. 3.
- Aparicio, C., *et al.* 2014. Zygomatic implants: indications, techniques and outcomes, and the zygomatic success code. *Periodontol.*, 2000, 66(1): p. 41-58. 16.
- Aparicio, C., P. Perales, and B. Rangert 2001. Tilted implants as an alternative to maxillary sinus grafting: a clinical, radiologic, and periotest study. *Clin Implant Dent Relat Res*, 3(1): p. 39-49. 6.
- Balshi, T.J., *et al.* 2012. Zygomatic bone-to-implant contact in 77 patients with partially or completely edentulous maxillas. *J Oral Maxillofac Surg*, 70(9): p. 2065-9. 7.
- Bidra, A.S. and G. Huynh-Ba, 2011. Implants in the pterygoid region: a systematic review of the literature. *Int J Oral Maxillofac Surg.*, 40(8): p. 773-81. 23.
- Candel, E., D. Penarrocha, M. Penarrocha 2012. Rehabilitation of the atrophic posterior maxilla with pterygoid implants: a review. *J Oral Implantol*, 38 Spec No: p. 461-6. 8.
- Chrcanovic, B.R. and M.H. Abreu 2013. Survival and complications of zygomatic implants: a systematic review. *Oral Maxillofac Surg.*, 17(2): p. 81-93. 17.
- Fernandez, H., *et al.* 2014. Zygomatic implants for the management of the severely atrophied maxilla: a retrospective analysis of 244 implants. *J Oral Maxillofac Surg.*, 72(5): p. 887-91.
- Galan Gil, S., *et al.* 2007. Rehabilitation of severely resorbed maxillae with zygomatic implants: an update. *Med Oral Patol Oral Cir Bucal*, 12(3): p. E216-20. 10.
- Goiato, M.C., *et al.* 2014. Implants in the zygomatic bone for maxillary prosthetic rehabilitation: a systematic review. *Int J Oral Maxillofac Surg*, 43(6): p. 748-57. 12.
- Lopes, L.F., *et al.* 2015. Placement of dental implants in the maxillary tuberosity: a systematic review. *Int J Oral Maxillofac Surg.*, 44(2): p. 229-38. 21.
- Malo, P., A. Nobre Mde, I. Lopes 2008. A new approach to rehabilitate the severely atrophic maxilla using extramaxillary anchored implants in immediate function: a pilot study. *J Prosthet Dent*, 100(5): p. 354- 66. 15.
- Monteiro, D.R., *et al.* 2015. Posterior partially edentulous jaws, planning a rehabilitation with dental implants. *World J Clin Cases*, 3(1): p. 65- 76. 2.
- Ozaki H, Ishikawa S, Kitabatake K, Yusa K, Sakurai H, Iino M 2015. Functional and aesthetic rehabilitation with maxillary prosthesis supported by two zygomatic implants for

- maxillary defect resulting from cancer ablative surgery: a case report/technique article. *Odontology*.
- Rodriguez, X., et al. 2012. Modified surgical protocol for placing implants in the pterygomaxillary region: clinical and radiologic study of 454 implants. *Int J Oral Maxillofac Implants*. 27(6): p. 1547-53. 22.
- Rodríguez-Ciurana, X.V.N., V.Mendez, M.Segalá 2008. Alternatives to maxillary sinus lift: posterior area of the atrophic maxilla rehabilitation by means pterigoideal implants. *Rev Esp Cir Maxilofac.*, 412-419. 5.
- Stievenart, M. and C. Malevez 2010. Rehabilitation of totally atrophied maxilla by means of four zygomatic implants and fixed prosthesis: a 6-40-month follow-up. *Int J Oral MaxillofacSurg*, 39(4): p. 358-63. 9.
- Takamaru N, Nagai H, Ohe G, Tamatani T, Sumida K, Kitamura S, Miyamoto Y 2015. Measurement of the zygomatic bone and pilot hole technique for safer insertion of zygomaticus implants. *Int J Oral Maxillofac Surg*.
- Ugurlu, F., et al. 2013. Rehabilitation of posterior maxilla with zygomatic and dental implant after tumor resection: a case report. *Case Rep Dent*, p. 930345. 4. X.
- Vrielinck, L., et al. 2003. Image-based planning and clinical validation of zygoma and pterygoid implant placement in patients with severe bone atrophy using customized drill guides. Preliminary results from a prospective clinical follow-up study. *Int J Oral MaxillofacSurg*, 32(1): p. 7-14. 24.
- Wu Y, Zhang C, Squarize CH, Zou D 2015. Oral Rehabilitation of Adult Edentulous Siblings Severely Lacking Alveolar Bone Due to Ectodermal Dysplasia: A Report of 2 Clinical Cases and a Literature Review. *J Oral Maxillofac Surg.*, 73(9):1733.e1-12.
- Yates, J.M., et al. 2014. Treatment of the edentulous atrophic maxilla using zygomatic implants: evaluation of survival rates over 5-10 years. *Int J Oral MaxillofacSurg*, 43(2): p. 237-42.

\*\*\*\*\*