



RESEARCH ARTICLE

MAXILLARY AND MANDIBULAR ARCH REHABILITATION WITH FIXED CEMENT RETAINED IMPLANT SUPPORTED PROSTHESIS

*¹Dr. Vaibhav Joshi, ²Dr. Varun Suhag, ²Dr. Jainendra Kumar, ²Dr. Nidhi Bhatia and ³Dr. Shalini Gupta

¹Assistant Professor, Department of Periodontics, Santosh Dental College, Ghaziabad, India
²Post Graduate Student, Department of Periodontics, Santosh Dental College, Ghaziabad, India
³Private Practitioner, Joshi Dental Implant Centre, Ghaziabad, India

ARTICLE INFO

Article History:

Received 28th January, 2016
Received in revised form
19th February, 2016
Accepted 16th March, 2016
Published online 26th April, 2016

Key words:

Fixed partial prosthesis,
Implants supported prosthesis,
Oral rehabilitation.

ABSTRACT

There is an increasing fixed prosthetic and esthetic demand for full arch oral rehabilitation and it requires precise treatment planning. Replacement of teeth should overcome the patient's functions like mastication, phonetics and esthetics. Earlier conventional dentures were considered better option to replace multiple missing teeth in an arch till full arch implant supported fixed rehabilitation became popular in dentistry for better patient acceptance and esthetics. In this case series multidisciplinary treatment planning of oral maxillary and mandibular implant supported rehabilitation is described to optimize prosthetic success and patient satisfaction. Patients having faulty fixed partial prosthesis (FPD) in upper and lower jaws were successfully treated with implant supported fixed prosthesis and patient's functional and esthetic demands were achieved.

Copyright © 2016, Dr. Vaibhav Joshi et al. This is an open access article distributed under the Creative Commons Attribution License, which permits unrestricted use, distribution, and reproduction in any medium, provided the original work is properly cited.

Citation: Dr. Vaibhav Joshi, Dr. Varun Suhag, Dr. Jainendra Kumar, Dr. Nidhi Bhatia and Dr. Shalini Gupta, 2016. "Maxillary and mandibular arch rehabilitation with fixed cement retained implant supported prosthesis", *International Journal of Current Research*, 8, (04), 29896-29899.

INTRODUCTION

Partial or complete edentulism is accompanied by lot of adverse esthetic and biomechanical sequelae. Missing teeth can be restored by various options depending upon patient's clinical findings and demands (Douglass, 2002). Implant assisted rehabilitation has become contemporary choice for the replacement of the natural teeth and to restore the patient to normal contour, esthetics and comfort. As a result of continued research, diagnostic tools, treatment planning, implant designs, materials and technique; predictable success is now a reality for the restoration of partially edentulous patients with implants in many challenging clinical situations. The use of osseointegrated implants to support prosthesis in partially or completely edentulous patients is a now an established treatment modality based on documented long-term success in restoring edentulous jaws (Adell, 1981; Ericsson, 1986 and Van Steenberghe, 1989).

Fabrication of prosthesis over osseointegrated implants can be of two main types: a removable implant supported overdenture or an implant supported fixed bridge. Fixed bridge over implants is better treatment option for maladaptive patients (George, 2004). Following clinical factors should be considered before taking decision to treat an edentulous upper arch with implant supported fixed prosthesis:

- Facial and lip support
- Smile line and Lip line
- Thickness of ridge mucosa
- Bone quality and quantity

Case Report 1

A 41 years old female patient reported with a chief complaint of loose upper artificial teeth and inability to masticate. Proper case history was recorded. Medical history was not significant. On clinical examination, mobility was found in maxillary anterior porcelain fused to metal (PFM) Bridge in relation to 11, 12, 13, 14, 21, 22, and 23. Multiple root stumps were

*Corresponding author: Dr. Vaibhav Joshi

Assistant professor, Department of Periodontics, Santosh Dental College, Ghaziabad, India

present in the region of 15, 24, 25, 38 and grossly carious teeth in the region of 28, 44 and 48. The periodontal condition of remaining natural mandibular teeth was found to be satisfactory. Anatomic landmarks, facial measurements and the resting positions of lower jaw were used to determine appropriate vertical dimension for the patient. After thorough clinical and radiographic examination patient was informed about the need for removal of the mobile anterior prosthesis, extraction of root stumps and carious broken teeth. The advantages and disadvantages of various prosthetic treatment modalities ranging from conventional removable partial denture (RPD) to implants were explained and discussed with the patient. Treatment option selected was upper implant supported fixed porcelain fused to metal bridge. Patient's consent was taken. After complete clinical and radiographic analysis appropriate sized implants were selected. Upper and lower alginate impressions were made for temporary immediate removable partial denture. Two stage surgical protocols were planned and patient was asked to have antibiotics and analgesics prior to surgery. Faulty upper anterior bridge was removed. Extractions irt 14, 15, 23, 24, 25, 28, 38, 44, 48 were done. Sequential drills were used and implants were placed in the osteotomy sites. Cover screws were placed and suturing was done. Post operative instructions and care was given. Immediate dentures were delivered and maintenance of oral hygiene was advised. Second stage surgery was done after 6 months (Figure 1). Healing abutments were placed and soft tissue healing around implants was achieved (Figure 2).

prosthesis was fabricated. After checking in oral cavity, final cementation was done (Figure 4). Patient was advised to maintain oral hygiene and recalled for proper follow up. Final OPG X ray was done and evaluated. (Figure 5)

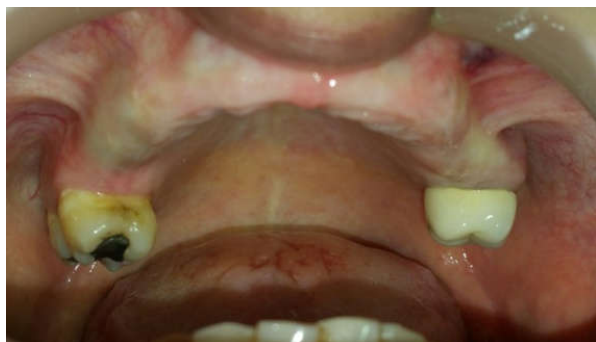

Figure 1. Healed site after six months for second stage surgery

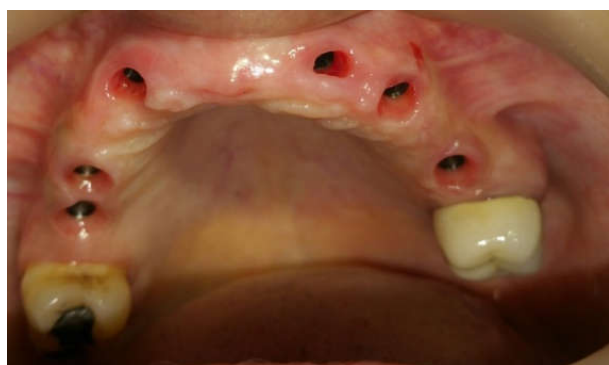

Figure 2. Soft tissue profile after placement of healing abutments

Impression analogues were placed; open tray impression was made with elastomeric impression material. First the abutments were placed into the mouth (Figure 3) and the metal framework was tried in for fit and later final cement retained

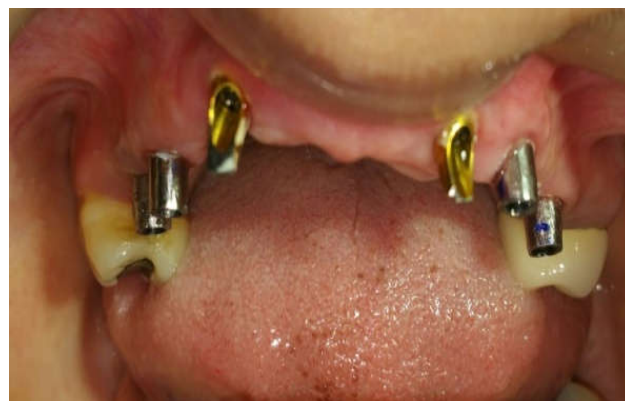

Figure 3. Final abutments in place

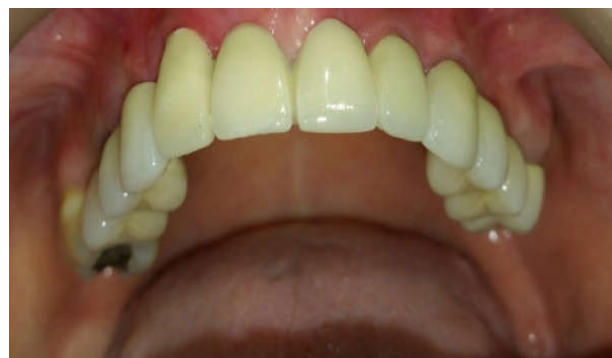


Figure 4. Post operative view after final prosthesis

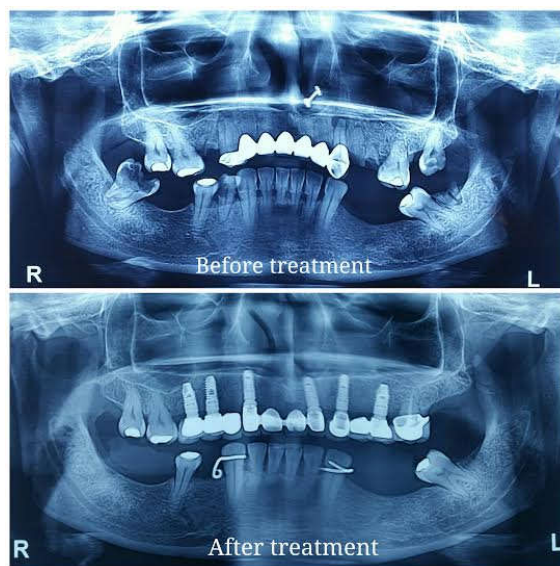


Figure 5. OPG X ray before and after treatment

Case Report 2

A 62 years old male patient presented with chief complaint of pain in lower jaw region. Patient had a history of lower anterior mobile prosthesis irt 31, 32, 41, 42, 43. Root stump was present irt 47. On clinical examination periodontal

condition of remaining teeth 33, 34, 35 found to be compromised. Proper case history was recorded. Patient's medical history was not significant. The treatment option advised to the patient was removal of faulty mandibular anterior prosthesis followed by extraction of 33, 34, 35, 47 and implant placement for fixed prosthesis in mandibular arch. Thorough clinical and radiographical evaluation was done. Upper and lower alginate impressions were made for immediate temporary removable partial denture fabrication. Patient consent was obtained and prophylactic antibiotic coverage was given. Lower anterior mobile bridge was removed, extractions were done and implants were placed after sequential drillings. Cover screws were placed, flap was closed and sutures were done. Post operative instructions were given. Suture removal was done after ten days. After a waiting period of 4 months, healing was assessed (Figure 6) second stage surgery was performed under local anaesthesia, cover screws were exposed and healing abutments were placed (Figure 7). After healing, impression copings were connected to the implants. Impression was made with elastomeric impression material. Metal framework was first evaluated for fit and later final abutment was placed (Figure 8) and Prosthesis cementation was done (Figure 9). Patient was recalled on regular basis for follow up.

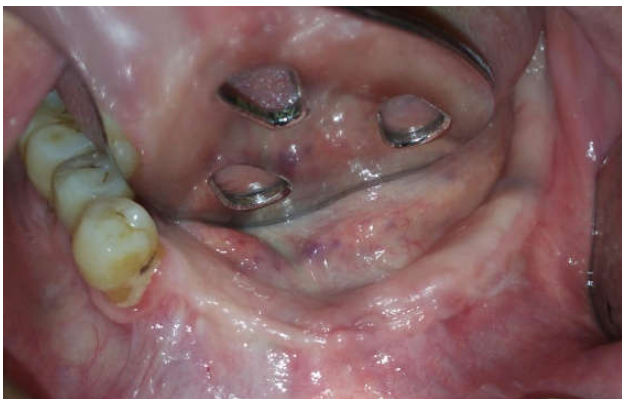


Figure 6. Healed site after four months for second stage surgery

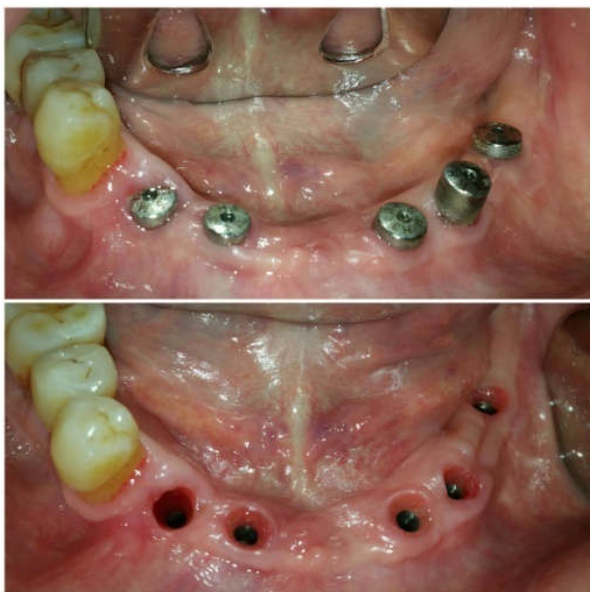

Figure 7. Healing abutments in place

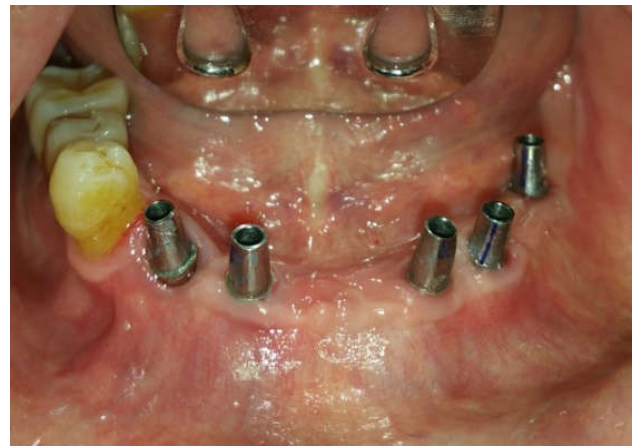


Figure 8. Final abutments in place

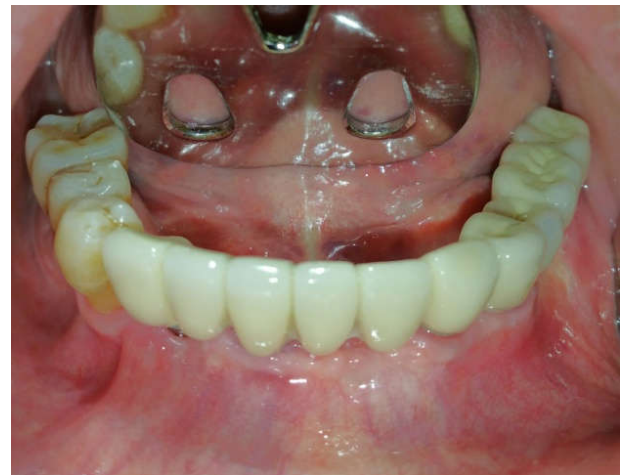

Figure 9. Cement retained final prosthesis

DISCUSSION

Several treatment options have been described for long span partially edentulous maxillary arch. Partially edentulous maxilla and mandible has anatomic limitations which should be considered before designing the prosthesis, and the selected design should result in proper biomechanical stress distribution, better esthetics and patient acceptance (Chee, 2005). Treatment of partial edentulism with dental implants has evolved into a predictable procedure and is expected to play a revolutionary role in oral rehabilitation (Adell, 1990). Implant supported fixed prosthesis has high success rate and postoperative complications are relatively modest (Vaibhav Joshi, 2015). Implant supported fixed prosthesis can be cement retained or screw retained. Cement-retained implant-prosthesis offers several advantages, including absence of unesthetic screw access holes and has greater resistance to porcelain fracture. Standard crown & bridge procedures can also be used in most situations (Weber, 2006). The prosthesis in both the cases were sectioned in such a way that the biting forces are properly distributed and stress overload on the implants are reduced to greater extent. The maximum biting force is in the molar region and decreases as measurements progress anteriorly (Misch, 2008 and Carlsson, 1974). The situation of overload has been reduced as the cantilevers are in the anterior region where forces would be less. Using the principles of

implant-protected occlusion, the crowns were adjusted to have light centric contact along the long axis of the implant, with the patient in the clenched position. This took into account compression of the natural dentition within the alveolar sockets. There were no contacts on the buccal cusp tips, which would create off-axis loading of the implant and place it under unfavorable shearing forces. The crowns were cemented with Zinc polycarboxylate cement, allowing for easy retrievability. Periodic clinical assessment of the implant fixture, prosthesis, and surrounding tissue is critical for clinical success. In these cases professional removal of Supragingival and subgingival deposits on a regular basis was done.

Conclusion

Availability of implant supported fixed treatment options for replacing multiple missing teeth is a remarkable advance in dentistry but it demands considerable skill and judgement and a high degree of patient commitment and understanding. Various clinical factors should be considered before the selection of fixed prosthesis design. This case series showed the sequence of events involved in restoring a maxillary and mandibular arch with fixed porcelain fused to metal bridge supported by dental implants. The patients were fully satisfied with the treatment outcome.

REFERENCES

- Adell, R., Errikson, B., Lekholm, U., Branemark, P.I., Jemt, T. 1990. Long-term follow-up study of osseointegrated implants in the treatment of totally edentulous jaws. *Int J Oral Maxillofac Implant*; 5: 347-59.
- Adell, R., Lekholm, U., Rockler, B., Brånemark, P.I. 1981. A 15-year study of osseointegrated implants in the treatment of the edentulous jaw. *Int J Oral Surg*;10:387-416.
- Carlsson, G.E.1974. Bite force and masticatory efficiency. In: Kawamura Y, ed. *Physiology of Mastication*. Basel, Switzerland: Karger; 1974.
- Chee, W.W. 2005. Treatment planning: Implant-supported partial overdentures. *J Calif Dent Assoc*;33:313-6.
- Douglass, C.W., Watson, A.J. 2002. Future needs for fixed and removable partial dentures in the United States. *The Journal Prosthetic Dentistry*, 2002; 87(1):9-14
- Ericsson, I., Lekholm, U., Branemark, P.I., Lindhe, J., Glantz, P.O., Nyman, S. 1986. A clinical evaluation of fixed-bridge restorations supported by combination of teeth and osseointegrated titanium implants. *Journal of Clinical Periodontology*, 13(4):307-312.
- George, A.J. 2004. The Edentulous Predicaments. In: Zarb, editor. *Text book of prosthodontic Treatment for Edentulous Patients*, 12th ed. Noida: Elsevier publishers, p. 3-5.
- Misch, C.E. 2008. The completely edentulous mandible: treatment planning: force factors related to patient conditions. In: Misch CE, ed. *Contemporary Implant Dentistry*. 3rd ed. St Louis, Mo: Elsevier Mosby;105-129.
- Vaibhav Joshi, Shalini Gupta. 2015. Immediate implant placement in anterior aesthetic region and assessment using cone beam computed tomography scan technology. *Int J oral health*; 7(suppl 2):99-102.
- Van Steenberghe, D. 1986. A retrospective multicenter evaluation of the survival rate of osseointegrated fixtures supporting fixed partial prostheses in the treatment of partial ; 61(2):217-223.
- Weber, H.P., Kim, D.M., Ng, M.W., et al. 2006. Peri-implant soft-tissue health surrounding cement- and screw-retained implant restorations: a multi-center, threeyear prospective study. *Clin Oral Implants Res*. 17:375-79.
