



## RESEARCH ARTICLE

### CORRELATION OF ELONGATED STYLOID PROCESS WITH SERUM CALCIUM LEVELS

<sup>1</sup>Dr. Kuber Tyagi, <sup>2</sup>Dr. Ravi prakash sm, <sup>3</sup>Dr. Vinod Kumar Tyagi, <sup>4</sup>Dr. Sumeet Shah, <sup>5</sup>Dr. Bellona Thiyam, <sup>6</sup>Dr. Marilia Marceliano-Alves and <sup>7,\*</sup>Dr. Sankalp Verma

<sup>1</sup>Senior Lecturerr, Department of Oral Medicine and Radiology, Teerthankar Mahaveer dental College and Research Center, Moradabad, UP, India

<sup>2</sup>Professor, Department of Oral Medicine and Radiology, Subharati Dental College, Meerut, UP, India

<sup>3</sup>Reader, Department of Prosthodontics, Mahatma Gandhi Dental College and Hospital, Jaipur, Rajasthan, India

<sup>4</sup>3rd Year post graduate student, Department of Oral Medicine and Radiology, Teerthankar Mahaveer Dental College and Research Center, Moradabad, UP, India.

<sup>5</sup>3rd Year post graduate student, Department of Oral Medicine and Radiology, Teerthankar Mahaveer Dental College and Research Center, Moradabad, UP, India

<sup>6</sup>Professor of Specialization Course in Endodontics at Brazilian Dental Association - Niterói - RJ; Professor of specialization course in Endodontics at Santos Dumont Air Force \ Dental Clinic - Rio de Janeiro, Brazil

<sup>7</sup>Reader, Department of oral Medicine and Radiology, Bhabha College of Dental Sciences, Bhopal, MP, India

#### ARTICLE INFO

##### Article History:

Received 09<sup>th</sup> January, 2016  
Received in revised form  
07<sup>th</sup> February, 2016  
Accepted 17<sup>th</sup> March, 2016  
Published online 26<sup>th</sup> April, 2016

##### Key words:

Digital Panoramic Radiograph,  
Elongated Styloid Process,  
Serum Calcium Levels,  
Eagle Syndrome.

#### ABSTRACT

**Aims & objectives:** The aim of the present study is to evaluate the prevalence of styloid process and its correlation with serum calcium levels. The objectives are to evaluate the prevalence of clinical symptoms of elongated styloid process; prevalence of history of trauma to head and neck region and tonsillectomy of elongated styloid process; prevalence of elongated styloid process in age group, male and female and right and left; prevalence of pattern of calcification of stylohyoid complex; evaluate the relationship between body weight, height and elongated styloid process.

**Materials & methods:** Digital panoramic radiographs of 500 patients in age group of 40-89 years were taken. Serum calcium estimation of all these patients was done. All the measurements and findings were compared and statistically analysed.

**Results:** The statistical data revealed that, majority of subjects were males aged 40-49 years. Out of total 500 subjects, 41 had elongated styloid process. The incidence of elongated styloid process ranged from 0% to 28.6% in different age groups. The proportion of males with elongated styloid process (19.7%) was higher as compared to those of females (14.9%). Pattern E was most common. Mean body weight as well as mean height of subjects with elongated styloid process was observed to be significantly higher as compared to those having normal styloid process. Serum calcium levels were significantly higher ( $p < 0.001$ ) in subjects having styloid process as compared to subjects having normal styloid process.

**Conclusion:** With increasing age, there was an increase in proportion of subjects with elongated styloid process, more common in males with bilateral involvement. Pattern E was the commonest pattern followed by pattern L. A very poor correlation between length of styloid process and serum calcium levels was observed signifying that serum calcium levels were not dependent on the length of styloid process.

Copyright © 2016, Dr. Kuber Tyagi et al. This is an open access article distributed under the Creative Commons Attribution License, which permits unrestricted use, distribution, and reproduction in any medium, provided the original work is properly cited.

Citation: Dr. Kuber Tyagi, Dr. Ravi prakash sm, Dr. Vinod Kumar Tyagi, Dr. Sumeet Shah, Dr. Bellona Thiyam, Dr. Marilia Marceliano-Alves and Dr. Sankalp Verma 2016. "Correlation of elongated styloid process with serum calcium levels", *International Journal of Current Research*, 8, (04), 29545-29550.

## INTRODUCTION

The styloid process is a slender, cylindrical spur of the bone fused with the inferior aspect of temporal bone immediately in front of stylomastoid foramen. It normally lies between the internal carotid artery and external carotid artery.

\*Corresponding author: Dr. Sankalp Verma,

Reader, Department of oral Medicine and Radiology, Bhabha College of Dental Sciences, Bhopal, MP, India

It consists of two parts: basal which in adults is concealed by tympanic part, and a projecting portion. The projecting portion gives attachment to three muscles and two ligaments. The stylopharyngeus muscle arises near the base from the mesial and slightly posterior aspect, the stylohyoid from the posterior and lateral aspects near the middle and the styloglossus from the front near the tip. The tip is continuous with the stylohyoid ligament that runs down to lesser cornu of hyoid bone. A band of soft tissue, the stylomandibular ligament, passes from the

process below the origin of the styloglossus to the angles of mandible (Marano and Fenster, 1972). It is generally agreed that in embryo logically the styloid process, the hyoid bone and their interconnecting ligament are derived from the second branchial arch (Reichert cartilage). The chain of pieces with which we are concerned consist of four elements; the tympanohyal (base of styloid process), the stylohyal (the greater part of styloid process), the ceratohyal and the hypohyal (the lesser cornu of hyoid bone). The ceratohyal becomes the stylohyoid ligament which is basically connective tissue, in the intrauterine stage but because of its embryonic origin from the cartilage, it retains some area of persistent embryological cartilage which has the potential to grow and mature into bone (Marano and Fenster, 1972; Gossman *et al.*, 1977). There has been some controversy in the literature as to whether the stylohyoid ligament becomes ossified or calcified. There is no justification for referring to this condition in any other terms than ossified as the distal part of the elongated styloid process are always true bone. There have been observations in the literature of muscular fibres in the stylohyoid ligament; one anatomist has found an entire right "stylohyoid ligament" represented not as fibrous cord but as a distinct muscle. The opposite side of the dissection disclosed both a ligament and anomalous muscle and the anomalous muscle were termed as an "accessory stylohyoidei" (Gossman *et al.*, 1977).

Comparative anatomist have shown that in certain group of animals, such as birds, the ceratohyal does not undergo regressive metamorphosis into the stylohyoid ligament as in man, but is transformed from embryological cartilage into a chain of ossicles known as epihyal bone. In light of this, the styloid process may be considered a normal feature that forms a portion of the tonsillar bed and has the function of supporting the muscles of deglutition (Gossman *et al.*, 1977). The human styloid chain which includes the styloid process, the stylohyoid ligament and the hyoid bone has been studied for at least 400 years. The components of the chain are embryologically derived from three paired cartilages, epihyal, ceratohyal, hypohyal and single median basihyal cartilage. The epihyal cartilage also known as Reichert's cartilage ossify in two parts: the proximal (tympanohyal) forms a short bone that fuses to the squamous temporal bone at approximately the time of birth and the distal (stylohyal) becomes a larger endochondral bone that fuses into the tympanohyal in the late teens. The tympanohyal and stylohyal form the styloid process (Marano and Fenster, 1972; Omnell *et al.*, 1998). In human beings the ceratohyal cartilages are variable and may be absent. They are initially situated within the stylohyoid ligament, distal to the Reichert's cartilage. They ossify endochondrally to form another bone as large as, or larger than stylohyal bone. This ceratohyal bone may fuse to the distal end of the stylohyal bone to become a very long styloid process, or it may fuse to the lesser cornu of the hyoid bone, or it may remain suspended within the stylohyal ligament. The hypohyal cartilages ossify to form the lesser cornu of hyoid bone. Finally the single median basihyal cartilage usually fuses with the cartilages of the third pharyngeal arch. Together they ossify endochondrally to form the body of the hyoid bone (Omnell *et al.*, 1998). The normal length of the styloid process is 20-25mm in adults, the mean radiographic length of the styloid process has been reported to be between 20-35 mm (Bozkir *et al.*, 1997).

Elongation of the styloid process and/or ossification of the stylohyoid ligament can result in styloid-stylohyoid syndrome. This case is known as either "Eagle's syndrome", "elongated styloid process syndrome", "styloid process-carotid artery syndrome", "stylohyoid syndrome" or "styloid process neuralgia". Eagle reported several cases of cervicalpharyngeal symptoms associated with radiographic diagnosis of an elongated ossified styloid process occurring few months post tonsillectomy. He described the symptoms as nagging or aching sensation in the throat, similar to the chronic pharyngitis and pain spreading to the ear and the sensation of a foreign object lodged in the throat. It may develop inflammatory changes or impinge on the adjacent arteries or sensory nerve endings, leading to the symptoms described. A diagnosis of eagle's syndrome is applied only when the ossification develops within a period of time after trauma, with accompanying symptoms. Eagle's syndrome may be caused by tonsillectomy or traumatic fracture of a mineralised stylohyoid ligament.

A diagnosis of stylohyoid syndrome is applied only when patients have stylohyoid chain ossification and/or styloid process elongation with symptoms; there is no history of cervicopharyngeal trauma.<sup>4</sup> Diagnosis can usually be made on physical examination by digital palpation of the styloid process in the tonsillar fossa, which exacerbates the pain and with radiographic workup. In addition relief of symptoms with injection of an anesthetic solution into the tonsillar fossa is highly suggestive of diagnosis.<sup>4</sup> Oliver, in four cases found complete ossification of the process with absence of the muscles of stylohyoideus profundus (Kulvin, 1949). The normal length styloid process is not palpable beneath the tonsillar fossa after tonsillectomy because of the depth of the submucosal tissues (Eagle, 1958). A styloid process is always present but it may not be demonstrable in roentgenograms when it is short and superimposed on other skeletal structures (Stafne and Hollinshead, 1962). Discovery of this condition through palpation of the tonsillar fossae and roentgenographic examination is easily accomplished (Lincoln, 1969). The resulting carotidynia was also alleviated by surgical shortening of the styloid process (Shira, 1974). Radiographs will confirm the presence of the structure and arteriograms with the head in various positions will show the effects of the elongated process in the area (Messer, 1975). The clinical diagnosis of styloid process or stylohyoid ligament can be substantiated with antero-posterior, lateral and oblique Xrays (McCorkell, 1985). However, in the short processes, the poor haversian remodelling and the presence of a cartilaginous shell surrounding the compact bone formation during the development of this type of styloid process (Lengele and Dhem 1989). A neck x-ray should be done to confirm the cause postoperatively or if neck x-ray is available, calcification of the stylohyoid ligament should be looked for immediately as the possible cause of the difficult intubation (Aris *et al.*, 1992). The position and contour of the styloid process may be more important than length, the process may be smooth and well corticated or it may be bulky with an irregular contour (Bafaqeeb and Fachartz, 2000). Computed tomography (CT) is useful in that it provides complementary information to that provided by plain radiographic studies (Murtagh *et al.*, 2001).

The most frequent methods of detection of a mineralised stylohyoid ligament complex are panoramic and cephalometric lateral skull radiographs (Luz *et al.*, 2003). Although conventional radiographs provide a rough idea of the anatomy, it is difficult to get to the actual diagnosis due to superimposed anatomical structures (Saranlar *et al.*, 2005). CT and 3D-CT can provide both the chain itself and ossifications, as well as the possible relationship to adjacent structures like the carotid artery (Ramadan *et al.*, 2007). Appropriate choice of therapy, for symptomatic cases depends on pain intensity or dysphagia and it can be conservative or invasive (Paraskevas *et al.*, 2009). In conclusion, panoramic radiography should be evaluated not only for pathosis of the teeth and jaws, but also for other incidental findings, especially in the soft tissue region of the neck. The incidental findings could provide potentially lifesaving information for aged persons (Ohba *et al.*, 2003).

## METHODOLOGY

Digital panoramic radiographs were taken in five hundred patients aged forty to eighty five years. The subjects were randomly selected from the outpatient department of Kothiwal dental college and research centre. These radiographs were saved in most accurate form and printed only when positive findings were present. Estimation of serum calcium levels was performed in all 500 patients including those subjects showing calcification of stylohyoid complex. Then inter-relationship between serum calcium and elongated stylohyoid complex was assessed. Prior written and informed consent was taken from all the subjects. Ethical clearance was sought from institutional ethical committee. Inclusion criteria included patients aged 40-90 years who have already been advised for a radiograph. Patients less than 40 years, pregnant, with occupational x-ray exposure or with history of previous extensive radiographs, medical history of any disease in which serum calcium levels are altered were excluded.

## Viewing Conditions

The viewing conditions were standardised for each observer in a quiet room free from distractions. For radiographs, the observers used an illuminated view box (Medi-X view) in which extraneous light was masked. The glossy paper images were examined under proper lighting condition. Each observer had the option of using a magnification lens to view the radiographs. The image order was randomized for each block of images and to minimise learning effects, the observers received the each set image formats (glossy paper and film) in random order. Anatomical landmarks to be taken under consideration were styloid process and external auditory meatus.

## RESULTS

A total of 500 subjects aged between 40 to 89 years were enrolled in the study (Table 1). Majority of subjects were males. In both the genders, maximum number of subjects were in age group 40-49 years while minimum were in age group 80-89 years. (Graph 1). Out of 500 subjects evaluated, 41 had elongated styloid process. The incidence of elongated styloid process ranged from 0% to 28.6% in different age groups. It was observed that with increasing age there was an increase in proportion of subjects with elongated styloid process. Statistically, the difference in proportion of subjects with elongated styloid process was significant ( $p=0.049$ ). (table 2, graph 2). Table 3 shows the distribution of subjects according to type of styloid process. Pattern E was the commonest followed by pattern L in both the sides as well as total. Pattern J and K were the least common (Fig. 1). A total of 11 patients had presence of clinical symptoms, all of them had elongated styloid process, thereby showing a significant association with elongated styloid process ( $p<0.001$ ).

**Table 1. Distribution of patients according to age and gender**

S. NO	Age group (years)	Female (n=175)		Male (n=325)		Total (n=500)	
		No	%	No	%	No	%
1	40-49	72	31.4	157	68.6	229	45.8
2	50-59	53	39.8	80	60.2	133	26.6
3	60-69	33	35.5	60	64.5	93	18.6
4	70-79	12	42.9	16	57.1	28	5.6
5	80-89	5	29.4	12	70.6	17	3.4

**Table 2. Distribution of subjects with elongated styloid process in different age groups**

S. NO	Age group (years)	Normal styloid process (n=410)		Elongated styloid process (n=90)		Total (n=500)	
		No	%	No	%	No	%
1	40-49	193	84.3	36	15.7	229	45.8
2	50-59	110	82.7	23	17.3	133	26.6
3	60-69	70	75.3	23	24.7	93	18.6
4	70-79	20	71.4	8	28.6	28	5.6
5	80-89	17	100	0	0	17	3.4

## Image Acquisition

Every patient was adjusted accordingly in the OPG machine (Villa Sistemi Medicali Strato 2000 D) and radiographs were recorded. The orthopantomographic radiographs were adjusted in their best quality by adjusting the brightness and contrast on the monitor display. The image was saved in the most accurate form and printed in cases showing elongated styloid process.

Although all the 4 patients with history of trauma to head and neck had elongated styloid process yet the association was not significant statistically ( $p=0.347$ ). It was found that mean body weight as well as mean height of subjects with elongated styloid process was significantly higher as compared to those having normal styloid process. (Table 4) As compared to those having normal styloid process, the serum calcium levels of the

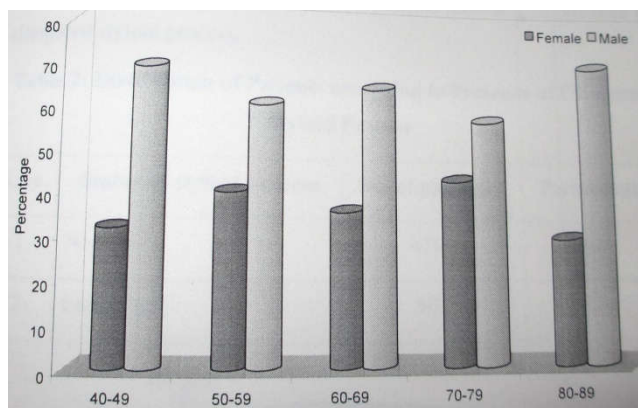
**Table 3. Distribution of subjects according to the pattern of styloid process**

S. NO	Pattern	Left side (n=500)		Right side (n=500)		Total (n=1000)	
		No	%	No	%	No	%
1	A	36	7.2	38	7.6	74	7.4
2	B	45	9.0	45	9.0	90	9.0
3	C	27	5.4	28	5.6	55	5.5
4	D	72	14.4	71	14.2	143	14.3
5	E	175	35.0	180	36.0	365	36.5
6	F	05	1.0	2	0.4	07	0.7
7	G	10	2.0	8	1.6	18	1.8
8	H	06	1.2	5	1.0	11	1.1
9	I	20	4.0	19	3.8	39	3.9
10	J	02	0.4	2	0.4	04	0.4
11	K	02	0.4	2	0.4	04	0.4
12	L	100	20.0	100	20.0	200	20.0

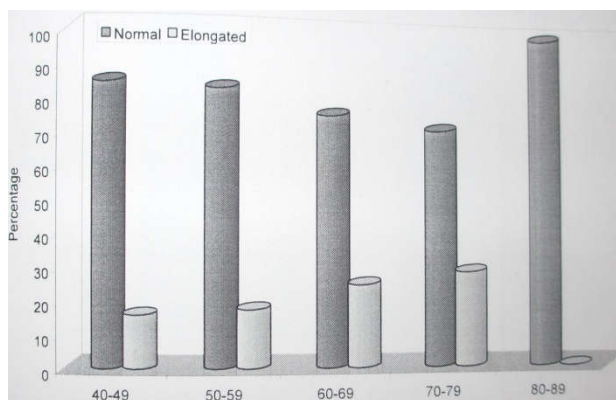
**Table 4. Association of body weight and height with elongated styloid process**

S. NO	Variable	Normal styloid process (n=410)		Elongated styloid process (n=90)		Total (n=500)	
		Mean	SD	Mean	SD	“t”	“p”
1	Body weight (Kg)	68.38	8.54	71.54	8.30	3.200	0.001
2	Height (Cm)	160.71	7.31	163.19	6.90	2.939	0.003

subjects having elongated styloid process were significantly higher( $p < 0.001$ ), as shown in Graph 3.



**Graph 1. Distribution of subjects according to age**

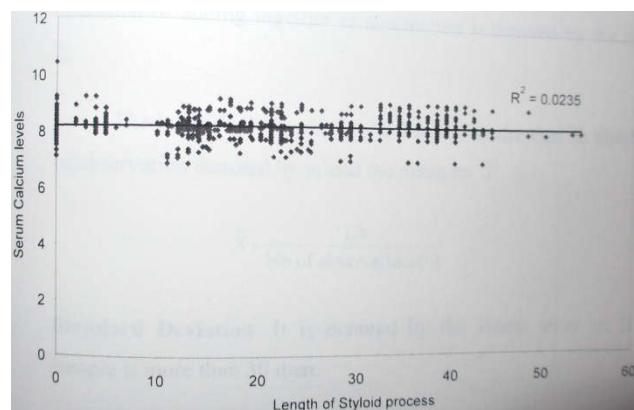


**Graph 2. Elongated styloid process in different age groups**

**DISCUSSION**

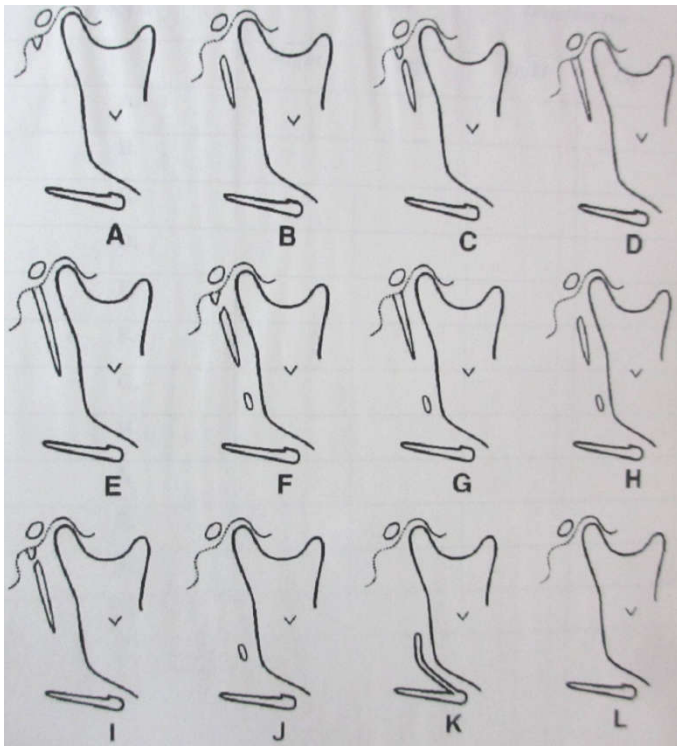
Elongated styloid process is a term used since the publication by Eagle in reports concerning findings in both dento-maxillofacial and ear-nose-throat patients. The term denotes a styloid process exceeding its normal length.

According to Eagle, “the normal styloid process measures between 2.5cm and 3 cm”. (Eagle, 1958) Reports concerning the styloid process and measurements of its length are mostly based on panoramic radiographs. Before considering a styloid process to be elongated, a range of normal styloid must be defined (Stafne et al., 1962; Shira, 1974). Moffat *et al* claimed that a length between 15.2mm and 44.7 mm should be considered as normal (Prabhu *et al.*, 2007).



**Graph 3. The correlation of serum calcium levels with length of styloid process**

Other studies accept length of over 30mm as elongated while another call it elongated if length exceeds 40mm (Jung *et al.*, 2004). The first one to describe a case of stylohyoid ligament ossification was Manchetti of Pauda in 1652. Diagnosis can be estimated by bimanual palpation of tonsillar fossa (normal styloid process is not palpable), panoramic radiography and computed tomography (Correll *et al.*, 1979). An elongated process or ossified stylohyoid ligament is not symptomatic in all cases. Eagle syndrome is always associated with symptoms (Paraskevas *et al.*, 2009; Jung *et al.*, 2004). Moreover ossified stylohyoid ligament may be associated with other conditions like cervical osteophytes, cervical spondylosis, anomalies in Atlantic section of vertebral artery and fracture of ossified ligament (Jung *et al.*, 2004). Mineralisation in the area of stylohyoid ligament was the result of continued growth and



**Fig. 1. The various patterns of styloid process**

subsequent ossification of the second branchial arch cartilage rather than mineralisation of the fibrous stylohyoid ligament (a degenerative or aging process) (Lengele and Dhem, 1989). Mineralisation in the area of the stylohyoid ligament complex is important because of its potential for causing clinical symptoms. Vague facial pain, especially upon swallowing, turning the head, opening the mouth, dysphagia, otalgia, headache, dizziness, sometimes transient syncope all have been associated with elongated styloid process or mineralised stylohyoid ligaments (Lengele and Dhem, 1989). The apex of the styloid process is clinically important because it is located between internal and external carotid arteries. The facial nerve runs anterior and medial to styloid process. The glossopharyngeal nerve exists through jugular foramen and curves and runs in proximity under styloid process. The accessory and vagus nerves also run medial to the styloid process. The approximation of the glossopharyngeal nerve with the stylohyoid ligament is the basis for the glossopharyngeal neurological symptoms seen in Eagle's syndrome. The persistent angulations of the cranial and stylohyoid segment or Reichert's cartilage and its important neurovascular relationship may help explain the symptomatology of Eagle's syndrome (Jung *et al.*, 2004; Correll *et al.*, 1979).

In this study, 500 subjects' participated, out of which 62.5% were males and 37.5% were females. In both the genders, 40-49 age group was most common. It was in accordance with study conducted by Correll *et al.* Their study consisted of 1702 subjects (97% males and 3% females) with median age of 55 years (Correll, 1979). However, female preponderance (57% females' vs 43% males) was seen in similar study conducted by Kelvin Carroll (Carroll Kelvin, 1984). In the present study, the prevalence of elongated styloid process was 18% and it was found to increase with increasing age.

It was in accordance with studies conducted by Kelvin Carroll and Mansour (Correll, 1979; Mansour *et al.*, 1986). Segmentation of the styloid process is a variation of the normal and should not be mistaken for a fracture of the process, as mentioned by Manson-Hing (Lincoln, 1969). It probably represents one pattern of progressive ossification, because approximately 40% subjects younger than 20 years of age had segmentation and its incidence diminished with age. Segmentation has not been previously reported in subjects younger than 20 years of age. Kaufman *et al* reported segmentation present in 12.9% of adults.

Partial ossification of the stylohyoid ligament was moderately common in adults (9.4%). It is interesting that no examples were found in subjects younger than 18 years of age, since this further suggests that ossification progresses with age (Saranlar *et al.*, 2005). Ferrario *et al* in their study found that there is an increased incidence and length of calcified segments with age (Ferrario *et al.*, 1990). T Jung *et al* found that expected length of styloid process increases by 0.5mm per year (Jung *et al.*, 2004). In this study, all subjects had bilateral involvement. Ferrario *et al* and Kaufman *et al* found a tendency of bilateral involvement and explained by degeneration of ligamentous complex linked to general tendency towards deposition of calcium salts (Ferrario *et al.*, 1990). Scaf *et al* found that majority of elongated styloid process was unilateral, located on the right side (76.2%) (Scaf *et al.*, 2003). In this study a very poor correlation between the length of styloid process and serum calcium levels was observed signifying that serum calcium levels were not dependant on length of styloid process (Scaf *et al.*, 2003; Okabe *et al.*, 2006).

## REFERENCES

- Aris, A.M., Elegbe, E.O. and Krishna, R. 1992. Difficult intubation stylohyoid ligament calcification. *Dept of Anaesth*, 33:204-5
- Bafaqeeb, S.A. Fachartz. 2000. Eagle syndrome: classic and carotid artery types. *Otolaryngology*;29:2
- Bozkir, M.G., Boga, H. and Dere, F. 1997. The evaluation of elongated styloid process in panoramic radiograph in edentulous patients. *Dept of Anatomy*, 32:14-17
- Carroll Kelvin. Calcification in the stylohyoid ligament. *Oral Surg.*, 1984;58:617-21
- Correll, R.W., Jensen, J.L., Taylor, J.B. 1979. Robert R R. Mineralisation of the stylohyoid-stylomandibular ligament complex. *Oral Surg.*, 48:4
- Eagle, W.W. 1958. Elongated styloid process. *Otorhinology*; 67:5-8
- Ferrario, V.F., Sigurta, D., Daddona, A., Dalloca, L., Miani, A. and Tafuro, F. 1990. Calcification of the stylohyoid ligament: incidence and morphoquantitative evaluation. *Oral Surg Oral Med Oral Pathol.*, 69:524-9
- Gossman, R.J., Homestead, Tarsitano, J.J. 1977. The styloid-stylohyoid syndrome. *Oral Surg.*, 35:7-10
- Jung, T., Tschernitschek, H., Hippen, H., Schneider, B. and Borchers, L. Elongated styloid process: when it is really elongated. *Dentomaxillofacial radiol* 2004;33:119-124

- Kulvin, M.M. Elongated styloid processes; their formation and clinical significance. *The laryngoscope*, 1949 ;40(12);907-909
- Lengele, B. and Dhem, A. 1989. Microradiography and histological study of the styloid process of the temporal bone. *Acta Anat.*, 135:193-99
- Lincoln, R. 1969. Manson-hing. The stylohyoid chain. *Oral Surg Oral Med Oral Pathol.*, 27:3
- Luz, J.G., Rodrigues, I., Chilvarquer, J. and Soler, M.P. 2003. Mineralisation of stylohyoid ligament complex in patients with temporomandibular disorders and asymptomatic individuals: a comparative study. *Oral Rehab.*, 30:909-13
- Marano, P.D. and Fenster, G.F. 1972. Eagle's syndrome necessitating bilateral styloid amputation. *Oral Surg.*, 33:6
- Mccorkell, S.J. 1985. Fractures of the stylohyoid process and stylohyoid ligament: an uncommon injury. *Dept of Radiology*, 25:10
- Messer, E.J. and Abramson, A.M. 1975. The stylohyoid syndrome. *Oral Surg.*, 33
- Monsour, P.A., and Young, W.G. 1986. Variability of the stylohyoid process and stylohyoid ligament in panoramic radiographs. *Oral Surg Oral Med Oral Pathol.*, 61:522-26
- Murtagh, R.D., Caracciolo, J.T. and Fernandez, G. 2001. CT findings associated with Eagle syndrome. *AJNR*; 22:1401-02
- Ohba, T., Takata, Y., Ansai, T., Morimoto, Y., Tanaka, T. and Kito, S. 2003. Evaluation of calcified carotid artery atheromas detected by panoramic radiograph among 80 years old. *Oral Surg Oral Med Oral Pathol Oral Radiol Endod*, 96:647-50
- Okabe, S., Morimoto, T., Ansai, T., Yamada, K., Tanaka, T. and Awano, S. 2006. Clinical significance and variation of the advanced calcified stylohyoid complex detected by panoramic radiographs among 80 year old subjects. *Dentomaxillofacial Radiol.*, 35:191-98.
- Omnell, K.H., Gandhi, C. and Omnell, M.L. 1998. Ossification of the human stylohyoid ligament. *Oral Surg Oral Med Oral Pathol Oral Radiol Endod.*, 85:226-32
- Paraskevas, G.K., Raikos, A., Lazos, L. M. 2009. Panagiotis. Unilateral styloid process: a case report. *Dept of anatomy* 2:9135
- Prabhu, L.V., Kumar, A., Nayak, S.R., Pai, M.M., Yadgaonkar R. and Krishnamurthy, A. *et al.* 2007. Unusually lengthy styloid process. *Dept of Anatomy*, 48:2
- Ramadan, S.U., Gokharman, D., Kacar, M. and Kosar, U. 2007. Diffuse stylohyoid chain ossification. 13:176-78
- Saranlar, A., Uzun, L., Ugur, M.B. and Ozer, T. 2005. Three dimensional CT of eagle's syndrome. *Dept of Radiol*, 11:206-09
- Scaf, G., Queiroz, D. and Castro, L.D. 2003. Diagnostic reproducibility of the elongated styloid process. *Oral Sci.*, 11(2):120-24
- Shira, R.B. 1974. Anatomic variations in the stylohyoid chain and their possible clinical significance. *Oral Surg Oral Med Oral Pathol.*, 38:5
- Stafne, E.C., Hollinshead, W.H. Rochester. 1962. Roentgenographic observation on the styloid chain. *Oral Surg Oral Med Oral Pathol*, 15:10

\*\*\*\*\*