



ISSN: 0975-833X

Available online at <http://www.journalcra.com>

*International Journal of Current Research*  
Vol. 8, Issue, 02, pp.26877-26880 February, 2016

**INTERNATIONAL JOURNAL  
OF CURRENT RESEARCH**

## CASE STUDY

### IMMEDIATE IMPLANT PLACEMENT IN ESTHETIC ZONE WITH EARLY LOADING AND PERI-IMPLANT ESTHETIC ASSESSMENT

**\*Dr. Vaibhav Joshi, Dr. Nidhi Bhatia, Dr. Shalini Gupta and Dr. Mamta Joshi**

Santosh Dental College, Ghaziabad, India

#### ARTICLE INFO

##### Article History:

Received 27<sup>th</sup> November, 2015  
Received in revised form  
15<sup>th</sup> December, 2015  
Accepted 07<sup>th</sup> January, 2016  
Published online 27<sup>th</sup> February, 2016

##### Key words:

Implants, Gingival architecture,  
CBCT, Periimplant esthetics.

#### ABSTRACT

Esthetic zone restoration with implant supported tooth replacement is one of the most difficult procedures to execute and has high esthetic challenges because loss of tooth leads to bone resorption and collapse of gingival architecture, causing esthetic compromise and inadequate bone for implant placement. Immediate implant placement is considered one of the conservative and predictable methods to achieve harmonious gingival architecture that also helps in preservation of bone height, soft tissue and esthetic profile. This case report demonstrates the assessment of immediate implant placement in the maxillary anterior region along with early loading using Cone Beam Computed Tomography (CBCT) scan technology and maintaining patient's high esthetic demands and adjacent soft tissue.

*Copyright © 2016 Vaibhav Joshi et al. This is an open access article distributed under the Creative Commons Attribution License, which permits unrestricted use, distribution, and reproduction in any medium, provided the original work is properly cited.*

**Citation:** Dr. Vaibhav Joshi, Dr. Nidhi Bhatia, Dr. Shalini Gupta and Dr. Mamta Joshi, 2016. "Immediate Implant Placement in Esthetic Zone with Early Loading and Peri-Implant Esthetic Assessment", *International Journal of Current Research*, 8, (02), 26877-26880.

## INTRODUCTION

Dental implants have been used as a best treatment modality for replacement of missing natural teeth in terms of stability and esthetic outcome. The success of dental implant therapy is no longer based only on functional osseointegration but positive patient outcomes of creating a restoration which resembles a natural tooth in all respects (Higginbottom and Wilson, 2002). Implant placement in esthetic zone requires careful preoperative treatment planning, hard and soft tissue augmentation and complete knowledge of surgical and prosthetic techniques. Immediate implant placement reduces the overall treatment time, prevents bone and soft tissue resorption and has better patient acceptance due to less trauma (Quirynen *et al.*, 2007). Early loading of implants facilitates formation of interproximal papillae, helps in maintaining the gingival margin levels and achievement of an appropriate clinical crown height (Schropp *et al.*, 2005). Due to challenging anatomy of the maxillary anterior tooth region, proper diagnosis, thorough knowledge and radiographic investigations are necessary. CBCT scan offer the clinician further insight into the anatomical structures providing 3 dimensional information (Vaibhav Joshi and Shalini Gupta, 2015).

To predict better peri-implant esthetics, following points should be considered before removing the failing tooth:

#### Patient's smile line

A patient's esthetic expectations should be evaluated together with their lip activity and lip length. Patients with gummy smile have extensive display of gingival tissues which can result in complete exposure of implant restoration in esthetic zone and it can be of concern to both clinician and the patient. Low smile line is a less challenging situation as the implant restoration interface will be hidden behind the upper lip (Tjan *et al.*, 1984).

#### Tooth position and biotype of periodontium

The tooth needs to be examined in all planes. The existing tooth position will significantly influence the presenting gingival architecture. If the tooth to be removed is apically positioned, the gingival margin is likely to migrate apically resulting in visible metal margins of the restoration thus compromising esthetics (Kois, 1998). A tooth positioned too buccally results in very thin gingival biotype or nonexistent labial bone. A tooth positioned more lingually would benefit from the presence of a thick gingival biotype and increased amount of buccal bone.

**\*Corresponding author: Dr. Vaibhav Joshi,**  
Santosh Dental College, Ghaziabad, India.

### Bone anatomy of the implant site

For esthetic restoration of implants to be successful, the extraction socket must have a three dimensional configuration that permits proper implant placement in a restoratively ideal position (D'Addona and Nowzari, 2001). The height and thickness of facial wall and the height of interproximal alveolar crest are significant structures that plays important role in predicting soft tissue profile (Kois, 1994; Tarnow et al., 1992). Before implant placement, the three dimensional configuration of hard and soft tissue should be analysed which allows placement of implants in an ideal position. Placement of two adjacent implants in the region of maxillary central incisors poses an additional challenge to attain pleasing esthetics as placing neighboring implants are critical for restorative contours. A minimum of 3 mm of bone should be retained between two adjacent implants placed in esthetic zone (Tarnow et al., 2000). Recreating interdental papilla between two adjacent implants in esthetic zone is a challenging task.

### CASE REPORT

A 35 year old male patient presented with chief complaint of fractured upper front teeth due to trauma caused by an accident one day back. Patient had a history of root canal treatment with porcelain fused to metal crowns of upper both central incisors (figure 1). The patient's medical history was not significant. On extra oral examination, there was no extra oral swelling seen. On intra oral examination, maxillary central incisors were mobile. Clinical and radiographic examination revealed fractured teeth with no peri apical lesion and bone quality and gingival architecture were favorable. Patient's oral hygiene was satisfactory, no marginal gingival inflammation and periodontal pockets were seen.

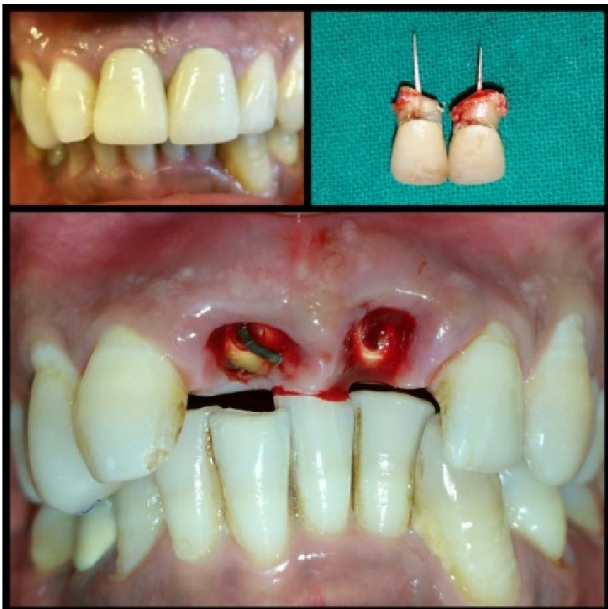

Figure 1. Pre operative view: fractured maxillary teeth 11# and 21#

The gingival biotype was thin and scalloped with triangular tooth form. Based on this a treatment plan of immediate implant supported restorations following atraumatic extractions

was planned. The challenge was to achieve a symmetrical smile with reference to hard and soft tissues. The patient was given detailed explanation about the treatment and an informed consent was taken for the same.

Pre surgical radiographic evaluation was carried out with CBCT scan for proper treatment planning (figure 2). After that endoosseous implants measuring diameter 4.5mm and length 13mm dimension were selected for both the sites. Patient was draped and anaesthetized with local anaesthetic agent. Both the roots were atraumatically removed and the sockets were debrided using a curette. The sockets were evaluated for any remaining granulation tissue and osseous defects. The facial and palatal plates were found to be intact.

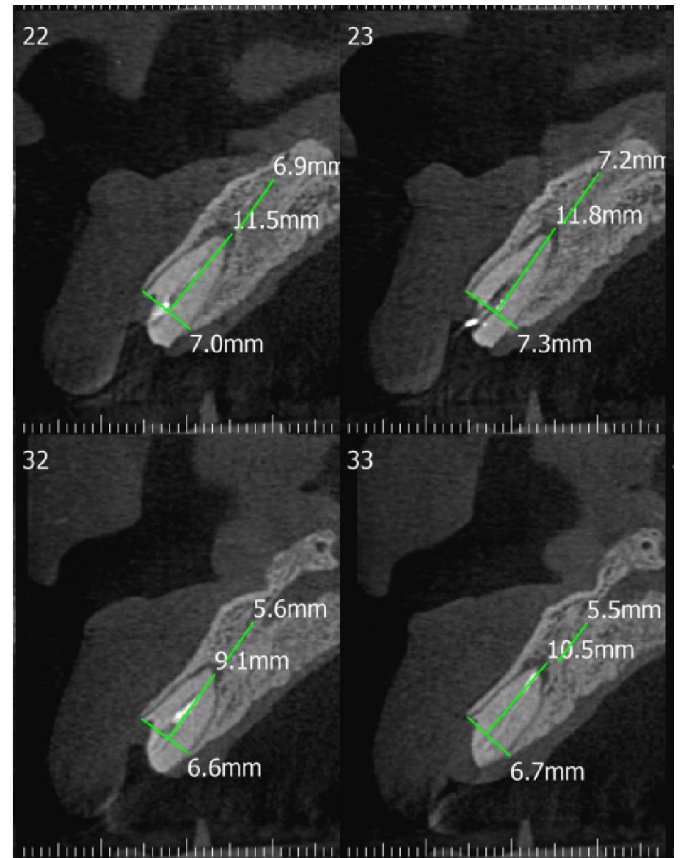


Figure 2. CBCT revealing remaining root stumps with intact buccal and palatal cortical plate

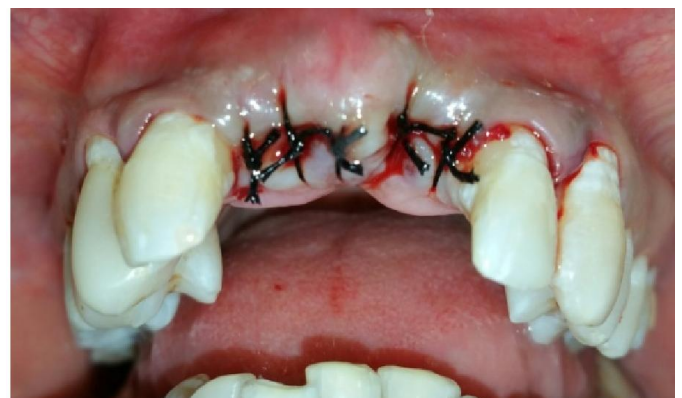

Figure 3. Immediate implant placement in maxillary 11 and 21

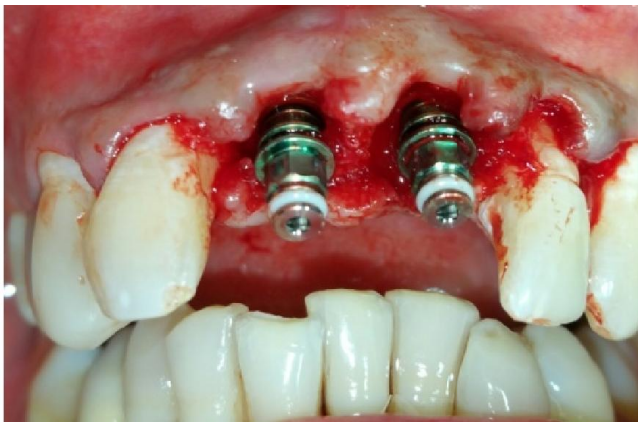


Figure 4. Sutures given

in the labiolingual direction and in the mesiodistal direction. The drilling procedures were initiated on the palatal socket walls and apical to the socket depth to avoid damage to the labial plate as well as for apical bony engagement.

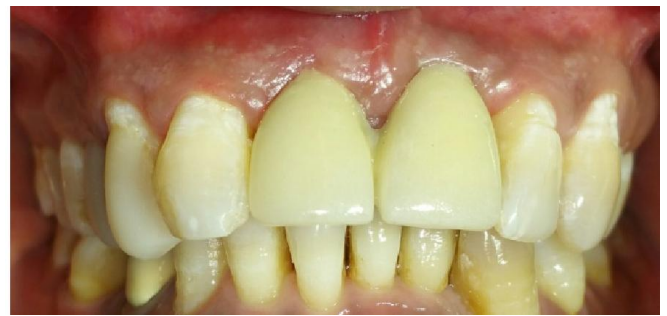

Figure 7. Post operative view after final prosthesis

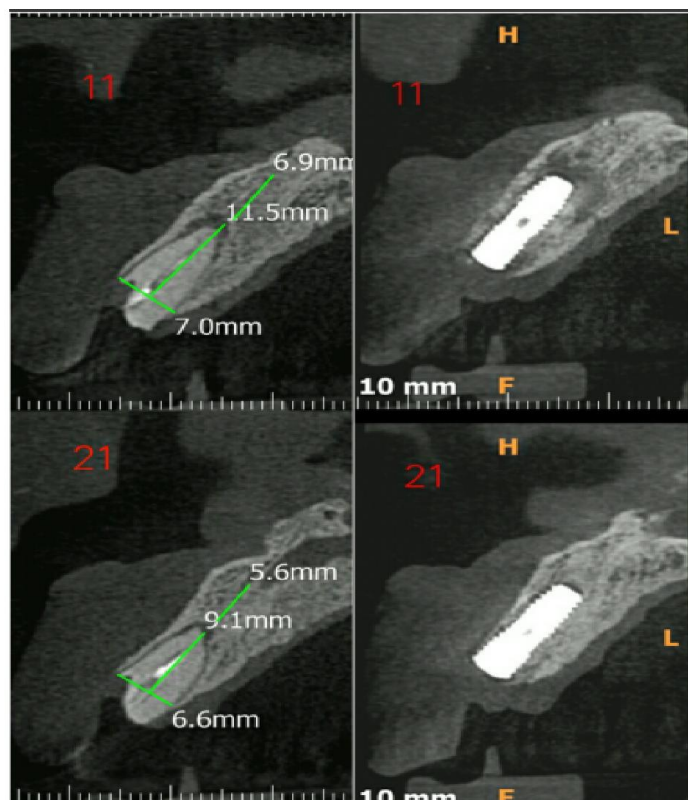


Figure 5. CBCT after 8 weeks of placement revealing peri implant bone adaptation

Drilling was done in sequential manner. Implant site were flushed with normal saline to remove any debris and the implants were placed in the sockets (Figure 3). The primary stability of the implants was satisfactory and the radiograph revealed correct placement. Sutures were given (figure 4) and immediate removable partial denture was delivered to the patient. Proper antibiotic and analgesics were prescribed and post operative instructions were given. After 8 weeks of implant placement, CBCT was repeated to evaluate peri implant bone adaptation (Figure 5). Second stage surgery was performed, gingival formers were placed, soft tissue profile was satisfactorily achieved (Figure 6). After that final prosthesis was delivered (Figure7). The patient was recalled for follow up after a week and was advised post operative care.

## DISCUSSION

Immediate implant placement and early loading is a better treatment option in the loss of anterior teeth having success rate upto 100 % (Uribe *et al.*, 2005). Immediate implant placement is indicated in trauma, root fracture, root resorption, root perforation and when the bony walls of alveolus are still intact. However, absolute contraindications are the presence of periodontal disease, acute/ sub acute periodontal or periapical infections, and unfavorable anatomy. The evaluation of bone with CBCT helps the implantologist to assess the quality and quantity of bone hence it has increased the success of implant therapy in modern times. Tooth position and shape, biotype of the periodontium and three dimensional evaluation of the alveolar bone are the parameters which should be examined before making a treatment plan to attain desired esthetics (Paolantonio *et al.*, 2001). The implant placed can be immediately or early loaded when primary stability is achieved, bone density is type I or II, the length of the implant is atleast 13 mm with minimum 3mm apical bone present, the diameter of implant almost matches with the diameter of the coronal aspect of the socket, no need for any bone grafting, and intended to initially load nonfunctional (Hahn *et al.*, 2001). The establishment of a peri-implant soft tissue contour with intact papillae and gingival margins is a major esthetic concern. In this case report the interdental space was completely filled with papilla and the harmony of soft and hard tissue was achieved by immediate implant placement in esthetically challenging

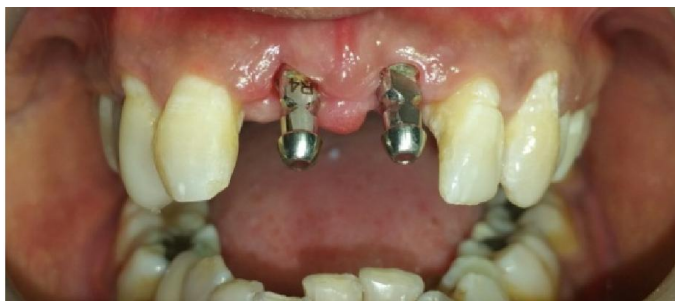

Figure 6. Soft tissue profile at 8 weeks

The osteotomy sites were marked. A small 2.0 diameter and cutting drill was used to continue with the bone preparation, parallel pin were placed in the drill hole to check the angulation

situation. Further evaluation is needed to monitor hard and soft tissue changes on a long-term basis.

### Conclusion

The implant restoration in the esthetic zone is one of the most demanding and complex treatment due to the necessity to obtain esthetic result. Although osseointegration and restoration of function and soft tissue esthetics dictate implant success, the patient's satisfaction is a key element of the success of implant therapy. This case report demonstrates that immediate implant placement and early loading is a viable option to give patient sound, timely and comfortable treatment.

### REFERENCES

- D'Addona, A., Nowzari, H. 2001. Intramembranous autogenous osseous transplants in aesthetic treatment of alveolar atrophy. *J Periodontol.*, 2000, 27):148–61.
- Hahn, J., Babbush, C. A. 2001. Dental implants: The art and science. Immediate implant placement after extraction: Contemporary materials and techniques. 2nd ed. United States of America: W.B. Saunders, pp. 305–34.
- Higginbottom, F. L., Wilson, T. G. 2002. Successful implants in the esthetic zone. *Tex Dental J.*, 119:1000-1005
- Kois, J. C. 1994. Altering gingival levels: The restorative connection part I: Biologic variables. *J Esthetic Dent.*, 6:3–9.
- Kois, J. C. 1998. Aesthetic extraction site development: The biologic variables. *Contem Aesthet Resto Pract.*, 2:10–8.
- Paolantonio, M., Dolci, M., Scarano, A., D'Archivio, D., Di Placido, G., Tumini, V., et al. 2001. Immediate Implantation in Fresh Extraction socket: A Controlled Clinical and Histological study in man. *J Periodontol.*, 72: 1560–71.
- Quirynen, M., Van Assche, N., Botticelli, D., Berglundh, T. 2007. How does the timing of implant placement to extraction affect outcome? *Int J Oral Maxillofac Implants*, 22(suppl):203-23.
- Schropp, L., Isidor, F., Kostopoulos, L., Wenzel, A. 2005. Interproximal papilla levels following early versus delayed placement of single-tooth implants: A controlled clinical trial. *Int J Oral Maxillofac Impl.*, 20:753-761.
- Tarnow, D. P., Cho, S. C., Wallace, S. S. 2000. The effect of inter-implant distance on the height of inter-implant bone crest. *J Periodontol.*, 71: 546-549.
- Tarnow, D. P., Magner, A. W., Fletcher, P. 1992. The effect of distance from the contact point to the crest of bone on the presence or absence of the interproximal dental papilla. *J Periodontol.*, 63:886–995.
- Tjan, A. H., Miller, G. D. 1984. The JG: Some esthetic factors in a smile. *J Prosthet Dent.*, 51:24-8.
- Uribe, R., Peñarrocha, M., Balaguer, J., Fulgueiras, N. 2005. Immediate loading in oral implants. Present situation. *Med Oral Patol Oral Cir Bucal.*, 10(Suppl 2): E143–53.
- Vaibhav joshi, shalini gupta, 2015. Immediate implant placement in anterior aesthetic region and assessment using cone beam computed tomography scan technology. *J Int Oral Health*, 7(Suppl 2):1-4.

\*\*\*\*\*