



## LAPAROSCOPY IN THE DIAGNOSIS OF CHRONIC PELVIC PAIN IN WOMEN

<sup>1</sup>Dr. Sheikh Mustafa, <sup>2,\*</sup>Dr. Neha Mahajan, <sup>3</sup>Dr. Perveena Fareed, <sup>4</sup>Dr. Samiya Tabassum

<sup>1</sup>Assistant Professor, Department of Obstetrics and Gynecology, LD Hospital, GMC Srinagar, J&K. India

<sup>2</sup>Senior Resident, Department of Obstetrics and Gynecology, LD Hospital, GMC Srinagar, J&K. India

<sup>3</sup>Senior Resident, Department of Obstetrics and Gynecology, LD Hospital, GMC Srinagar, J&K, India

<sup>4</sup>Senior Resident, Department of Obstetrics and Gynecology, LD Hospital, GMC Srinagar, J&K. India

### ARTICLE INFO

#### Article History:

Received 16<sup>th</sup> November, 2015

Received in revised form

07<sup>th</sup> December, 2015

Accepted 15<sup>th</sup> January, 2016

Published online 14<sup>th</sup> February, 2016

#### Key words:

Chronic Pelvic Pain,  
Endometriosis,  
Laparoscopy,  
Pelvic Adhesions.

### ABSTRACT

**Introduction:** Laparoscopy because of its availability and safety provides a valuable tool in the evaluation of undiagnosed chronic pelvic pain. It is a simple and definitive means of establishing the presence or absence of pelvic pathology without resorting to major abdominal surgery.

**Objective:** To evaluate the causes of chronic pelvic pain using laparoscopy and to correlate between clinical examination, ultrasonography, and laparoscopy.

**Settings and Design:** The present prospective study was done in the Department of Obstetrics and Gynecology of LD Hospital, GMC Srinagar.

**Materials and Methods:** Sixty cases of chronic pelvic pain of more than 6 months duration attending gynecology OPD were included in the study. After detailed history, examination, investigations, and ultrasonography, the patients were subjected to laparoscopy

**Results:** Ultrasonography could detect abnormality in 38.33% of patients as compared to Laparoscopy which had abnormal findings in 78.33%. Most common pelvic pathology was PID in 26.67% followed by adhesions in 23.33% cases which could not be detected clinically and on sonography.

**Conclusion:** The study revealed laparoscopy is a more sensitive and superior method for evaluation of chronic pelvic pain as compared to ultrasonography. Laparoscopy can establish a definitive diagnosis, modify and provide treatment without resorting to exploratory laparotomy.

Copyright © 2016 Dr. Sheikh Mustafa et al. This is an open access article distributed under the Creative Commons Attribution License, which permits unrestricted use, distribution, and reproduction in any medium, provided the original work is properly cited.

**Citation:** Dr. Sheikh Mustafa, Dr. Neha Mahajan, Dr. Perveena Fareed, Dr. Samiya Tabassum, 2016. "Laparoscopy in the diagnosis of chronic pelvic pain in women", *International Journal of Current Research*, 8, (02), 26250-26253.

### INTRODUCTION

Chronic pelvic pain is best defined as the non-menstrual pelvic pain for at least six months which is severe enough to cause functional disability and requires medical or surgical treatment (Howard, 2003). This pain may be episodic or continuous with variations in intensity but never or rarely completely absent. The causes are often obscure and the patients of chronic pelvic pain are often depressed and distressed because of the significant disruption of their social, marital and occupational lives (Sebanti et al., 2008). Chronic pelvic pain is one of the commonest symptomatology in gynaecological outpatient clinics. It accounts for 10% of office visits to gynaecologists and general clinics (Hebbar and Chawla, 2005). Management of patients with chronic pelvic pain presents a major challenge for the managing physician, especially to yield a diagnosis.

Patients are frequently anxious and depressed (Kumar and Malhotra, 2008). A thorough history and clinical examination no doubt provide considerable information but that is not sufficient in arriving at the diagnosis because the physical signs may not be specific i.e. pelvic tenderness, questionable pelvic mass and adnexal fullness.

Ancillary aids like imaging studies and direct visualization of the pelvic organs by laparoscopy are often required<sup>2</sup>. Sensitivity of ultrasonography (USG) for evaluation of chronic pelvic pain is poor. Laparoscopy can establish a definitive diagnosis, modify and provide treatment without resorting to exploratory laparotomy. It is also an extremely valuable adjunct in gynaecologist's armamentarium especially in confirming minimal disease and adhesion, which cannot be revealed sonographically. The present study is an attempt in understanding the aetiology of such a complex and perplexing problem in day-to-day gynaecological practice.

\*Corresponding author: Dr. Neha Mahajan,  
Senior Resident, Department of Obstetrics and gynecology, LD  
Hospital, GMC Srinagar, J&K. India.

**MATERIALS AND METHODS**

The present study was conducted in the department of Obstetrics and Gynecology LD. hospital, Govt. Medical College, Srinagar over a period of twelve months (October 2014 – September 2015). Cases were selected from the outpatient department and those who were admitted in Gynaecology ward. Detailed history was taken including associated symptoms like abnormal vaginal bleeding or discharge, dysmenorrhea, dyspareunia, infertility, enterocolic , urologic and musculo skeletal symptoms. After recording history, clinical examination and routine investigation, USG was done. Patients with obvious nongynecologic etiology like enterocolic, urologic or musculo skeletal causes were excluded. The study cases 60 were subjected to diagnostic laparoscopy after ruling out exclusion criteria for laparoscopy i.e. extreme obesity, cardiac and respiratory diseases, Diaphragmatic hernia and very large intra abdominal masses (>24wks gestation size).

A written consent was taken from the patients before procedure. Laparoscopy was performed under general anesthesia. After placing patient in modified lithotomy position, a small incision of 1 cm was given over inferior margin of the umbilicus and Verres needle was introduced. Pneumoperitoneum was created by CO<sub>2</sub>. Once adequate pneumoperitoneum was formed Verres needle removed and trocar with cannula was introduced into the peritoneal cavity. Trocar was withdrawn and laparoscope was introduced through cannula and was connected to fibre optic illumination and the video camera. Additional port would be created in one of the iliac fossa medial to inferior epigastric vessel to allow passage of an instrument for manipulation of adenexa. Pelvic organs were systematically inspected for any abnormality. At the end of procedure, laparoscope was withdrawn and gas allowed to escape. Cannula was then withdrawn and the skin incision closed with a suture. When required, uterine manipulator was introduced into the uterine cavity from below to elevate it and move from side to side. Laparoscopic findings were recorded.

**RESULTS**

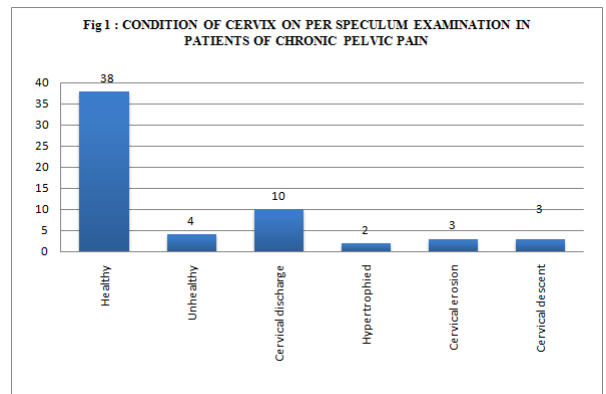
The main objective of this study was to correlate laparoscopic findings with preoperative pelvic findings, to determine the type of pathology existing and to re-evaluate the treatment strategy. Age wise distribution of the cases is shown in the Table 1.

**Table 1. Distribution of Cases According to Age**

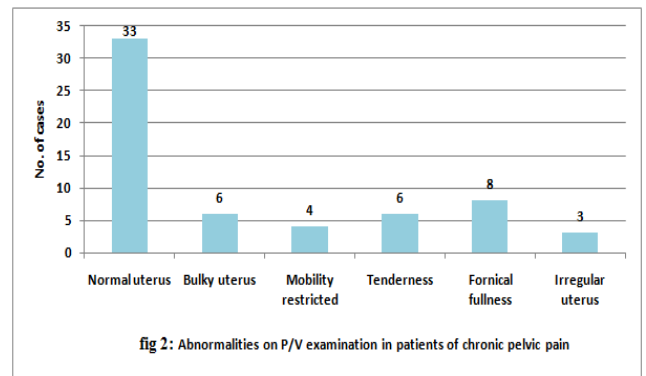
Age group (in years)	No. of cases (n)	Percentage (%)
20 – 25	6	10
26 – 30	21	35
31 – 35	14	23.33
36 – 40	12	20
> 40	7	11.67
Total	60	100.00

Half of women belonged to rural and half to urban area. Majority of cases 42 were multipara (70.00%) 14 primi para (23.33%) and 4 (6.67%) were nullipara .

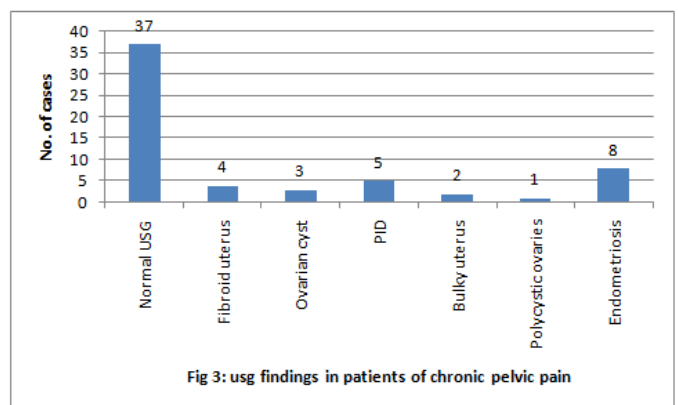
Mean Duration of pain was 5.46 year. 38 (63.33%) had normal cervix 22(36.67%) had abnormalities on per speculum examination which are shown in Fig. 1.



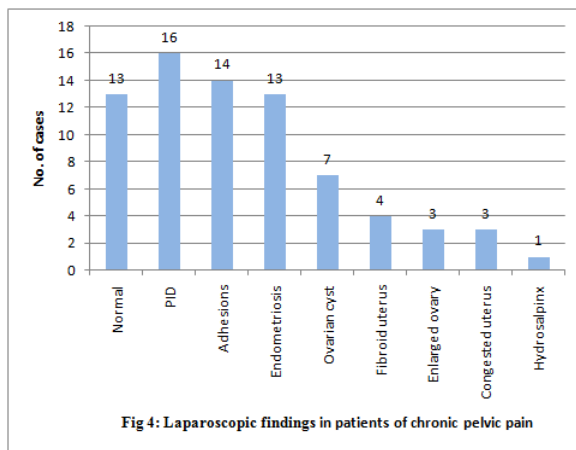
33 (55.00%) had normal uterus 27(45.00%) had abnormalities on P/V examination which are shown in Fig. 2.



All the patients were subjected to USG before diagnostic laparoscopy. In 37(61.67%) USG could not pick any abnormality. Various abnormalities detected on USG are shown Fig. 3.



On diagnostic laparoscopy 47(78.33%) cases showed positive findings are shown in Fig.4. Adhesions were found in 14 (23.33%) cases which could not be detected clinically or on USG. Out of 60 cases 47(78.33%) had positive findings on laparoscopy but USG could pick positive findings in 23(38.33%) cases which was statistically significant.



## DISCUSSION

Pelvic pain sometimes can be thought of as a puzzle that requires careful examination (Guo and Wang, 2006). It needs multidisciplinary approach for care and management of the cases. Proper history, examination should be considered in case of CPP (El-Mowafi, 2006). Diagnostic laparoscopy is one of the gold standards in the diagnosis of CPP (Newham *et al.*, 1996). In this study, the cause for CPP was identified in 47(78.33%) patients in form of PID adhesions, endometriosis, myomas, ovarian cysts, bulky uterus etc. which made the management of cases specific and targeted. Chhetri *et al.* (2009) in Diagnostic laparoscopy was able to detect pathology in 81.8%) patients (Chhetri *et al.*, 2009). Similarly study done by Swanton *et al.* (2006) which haws positive finding in 90%<sup>9</sup> Mara *et al.* (2002). Shows positive diagnostic laparoscopy in 82.3% (Mara *et al.*, 2002) and Hebbar and Chawla (2005), shows pelvic pathology in 58% Hebbar and Chawla (2005). Thus laparoscopy helps us to find out the cause of chronic pelvic pain which would be missed if we did not do diagnostic laparoscopy.

Various cause of CPP had been identified in different study done at different places. The commonest finding in present study was PID which was identified as cause in 16(26.67%) cases. PID has been demonstrated in 17.7% of cases by Mara *et al.* (2002). Sebanti *et al.* (2008) noted PID in 30.3% cases, Jyotsana Lamba *et al.* (2012) noted PID in 26.92% whereas PID as cause of chronic pelvic pain was found to be significantly less (3%) in study of Kontoravdis *et al.* (1996). Increase incidence of PID in our study probably reflects changing sexual behavior of women in reproductive age group. Adhesions were noted in 23.33% patients almost similar to Jyotsana Lamba *et al.* (2012) 23.07%, where as 34.1% were reported by Sebanti *et al.* (2008), 20.4% by Hebbar and Chawla (2005), 22.3% by Mara *et al.* (2002), 24.6% by Kontoravdis *et al.* (1996). While endometriosis was more common in the studies from other parts of the world like Razia Iftikar *et al.* (2008) showed 56.6% endometriosis, Kreisch *et al.* (1981) showed 32% , 32.5% by Vercellini *et al.* (1990), 38% by Howard *et al.* (1994), 35.4% by Kontoravdis *et al.* (1996). In our study it was only 21.67%comparable with20.47% by Mara *et al.* (2002). 18% in Sharma D *et al.*, (2011) and 13.9% by Sebanti *et al.* (2008).

This may be due to prevalence of early marriages, early child bearing and prolonged breast feeding in our women. Adhesions and many cases of PID and endometriosis were not detected clinically or on USG and this study shows superiority of laparoscopy over USG in detecting adhesions, PID and endometiosis which are among the important and common etiological factor in pain causation.

## Conclusion

The study revealed laparoscopy is a more sensitive and superior method for evaluation of chronic pelvic pain as compared to ultrasonography. Laparoscopy can establish a definitive diagnosis, modify and provide treatment without resorting to exploratory laparotomy.

## REFERENCES

- Chhetri, S., Khanna, S. and Poonam, Sen, B. April 2009. Laparoscopic Evaluation of Chronic Pelvic Pain in Women. *J Nepal Health Res Counc.* 7(14):45-8.
- El-Mowafi, D.M. 2006. Laparoscopic management of endometriosis. In *Progress in Obstetrics and Gynaecology* (edited by Studd J *et al.*). Churchill Livingstone, New Delhi, Vol. 17 : 345.
- Guo, S.W. and Wang, Y. 2006. The prevalence of endometriosis in women with chronic pelvic pain. *Gynecol Obstet Invest.* 62:121-30.
- Hebbar, S. and Chawla, C. 2005. Role of laparoscopy in evaluation of chronic pelvic pain. *J Minimal Access Surg.* 1 (3): 116-120.
- Howard, F.M. 1993. The role of laparoscopy in chronic pelvic pain: promise and pitfalls. *Obstet Gynecol Surv;* 48 (6): 357-387.
- Howard, F.M. 2003. Chronic pelvic pain. *Obstet Gynecol* 101:594-611.
- Kontoravdis, A., Chryssikopoulos, A. and Hassiakos, D. *et al.* 1996. The diagnostic value of laparoscopy in 2365 patients with acute and chronic pelvic pain. *Int. J. Gynaecol Obstet;* 52 (3) : 243-248.
- Kresch, A.J., Seifer, D.B., Sachi, L.B *et al.* 1984. Laparoscopy in 100 women with chronic pelvic pain. *Obstet Gynecol* 64: 672-674.
- Kumar, P. and Malhotra, N. 2008. Low backache and chronic pelvic pain. In *Jeffcoate's Principles of Gynaecology*, 7th edition. Jaypee Brothers Medical Publishers (P) Ltd, New Delhi, 676, 678.
- Lamba, J., Kumar, S., Gupta, S. and Verma, N. Laparoscopic Evaluation of Chronic Pelvic Pain. *J K Science*, 2012; 14 (2):74-76
- Mara, M., Fucikova, Z., Kuzel, D., Dohnalova, A., Haakova, L. and Zivny, J. 2002. Laparoscopy in chronic pelvic pain—a retrospective clinical study. *Ceska Gynekol.* 7(1):38-46.
- Newham, A.P., van der Spuy, Z.M., Nugent, F. 1996. Laparoscopic findings in women with chronic pelvic pain. *S Afr Med J.* Sep; 86(9 Suppl):1200-3.
- Razia iftikhar. 2008. Outcome of laparoscopy in chronic pelvic pain. *JSP (International).*13(4):155-158.

- Sebanti, G., Sarathi, C.P. and Rekha, D. 2008. Laparoscopy in chronic pelvic pain. *J Obstet Gynecol India* 58 (5): 435-437.
- Sharma, D., Dahiya, K., Duhan, N. and Bansal, R. Feb 2011. Diagnostic laparoscopy in chronic pelvic pain. *Arch Gynecol Obstet*, 283(2):295-7.
- Swanton, A., Iyer, L. and Reginald, P.W. 2006. Diagnosis, treatment and follow up of women undergoing conscious pain mapping for chronic pelvic pain: a prospective cohort study. *BJOG*. 113:792- 96.
- Vercellini, P., Fedele, L. and Arcaini, L. et al. 1990. Laparoscopy in the diagnosis of gynecologic chronic pelvic pain. *Int J Gynaecol Obstet* 32 (3) : 261-265.

\*\*\*\*\*