



CASE STUDY

MAXILLARY RIDGE EXPANSION FOLLOWED BY IMMEDIATE IMPLANT PLACEMENT: A CLINICAL CASE REPORT

*Dr. Quaid Johar Shakir, Dr. Namrata Dattatraya Pailwan and Dr. Dipti Udaysing Patil

Department of Periodontology and Oral Implantology, D. Y. Patil School of Dentistry, Nerul, Navi Mumbai

ARTICLE INFO

Article History:

Received 26th November, 2015
Received in revised form
28th December, 2015
Accepted 26th January, 2016
Published online 14th February, 2016

Key words:

Narrow Ridge, Bone Expansion,
Implant placement.

ABSTRACT

Introduction: Narrow alveolar ridges in anterior maxilla remains a serious challenge for successful placement of endosseous implants.

Case Presentation: This case report addresses a surgical procedure for expansion of the atrophic pre-maxillary ridge 2.7 mm wide using the Esset kit. A dental implant was immediately buried post expansion.

Discussion: This segmental ridge-split procedure with gradual bone expansion provides a quicker method wherein an atrophic ridge can be predictably expanded and eliminating the need for a second surgical site. This technique also shows that immediate implantation in split ridge of pre-maxillary can be performed.

Copyright © 2016 Dr. Quaid Johar Shakir et al. This is an open access article distributed under the Creative Commons Attribution License, which permits unrestricted use, distribution, and reproduction in any medium, provided the original work is properly cited.

Citation: Dr. Quaid Johar Shakir, Namrata Dattatraya Pailwan and Dipti Udaysing Patil, 2016. "Maxillary ridge expansion followed by immediate implant placement: A clinical case report", *International Journal of Current Research*, 8, (02), 26223-26226.

INTRODUCTION

Tooth extraction may be the choice of treatment in cases of severe periodontitis with poor prognosis, fracture due to physical trauma or caries, failed root canals etc. (Jaw-MinYoon, 2011) After loss of teeth, the vertical & horizontal resorption of alveolar bone occurs. This leads to a) improper placement of implant, b) use of smaller diameter implants (Jaw-MinYoon, 2011) which result in compromised aesthetics. To ensure longevity and functionality of implant supported prosthesis a multidimensional assessment of the available bone in the edentulous region is the most important factor. Ridge width affect many parameters of final restorations, which can easily be overlooked without careful preoperative planning. (Guirado, 2005) For favourable clinical outcome there must be atleast 1mm bone surrounding the implant (Nedir, 2004 & Neophytos, 2011) (i.e. mesially, distally, facially and palatally/lingually). Therefore preoperative clinical & radiographic evaluation of ridge is necessary. If the residual ridge width is insufficient, clinician should determine surgical procedure to overcome the problem before implant surgery. There are many procedures that have been suggested for

augmentation of ridge like guided bone regeneration (Massoumeh, 2013; Gary, 2003), only bone grafting (Massoumeh, 2013; Gary, 2003), distraction osteogenesis (Massoumeh, 2013; Gary, 2003). These methods carry multiple drawbacks like second surgical site, unavoidable elevated treatment cost, morbidity of graft material etc. To overcome these drawbacks up to some extent ridge splitting is used for expansion of insufficient residual ridge width along with adequate height. Availability of bone is the major factor while considering ridge expansion procedure. According to Cral E. Misch available bone is divided into four divisions (Carl, 1991)

Out of these, Division B offers sufficient available bone height (at least 10mm) but reduced bone width (2-5mm). So the favourable treatment option to be considered for such case is ridge expansion. Ridge expansion can be defined as the manipulation of the bone to form a receptor site for an implant without a removal of any bone from the patient. (Sujata, 2009) The objective of this technique is to maintain existing cancellous bone by pushing the buccal bony plates of residual ridge laterally with minimal trauma while simultaneously developing an accurately shaped osteotomy. (Guirado, 2005) Indications of ridge expansion (Sujata, 2009):

*Corresponding author: Dr. Quaid Johar Shakir,
Department of Periodontology and Oral Implantology, D. Y. Patil School of
Dentistry, Nerul, Navi Mumbai.

Table 1. Division of available bone by Carl E Misch

Division	Dimension	Treatment options
A	>5mm width >10-13mm height >7mm length <30 degrees angulation C/I ratio <1	Division A root form
B	2.5-5mm width >10-13mm height >12mm length <20 degrees angulation C/I ratio <1	Osteoplasty : Division A root form Augmentation: Demanding esthetics Great force factor Narrow implant: Division B root form Plate form
C	Unfavourable in: Width(C-w) Height (C-h) Length Angulation (C-a) ≥ 30degrees C/I ratio ≥ 1	Osteoplasty (C-w) Augmentation: Fixed prosthesis Demanding esthetics Great force factors Endosteal: Root form Ramus frame Subperiosteal: Arch form Angulation Cost Time Transosteal
D	Severe atrophy Basal bone loss Flat maxilla Pencil thin mandible	Augmentation: Treatment of choice Endosteal: Root form Ramus frame Subperiosteal

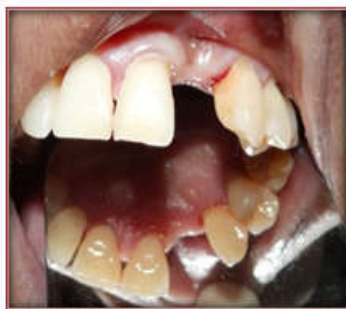

Figure 1

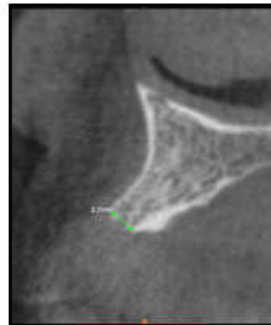


Figure 2

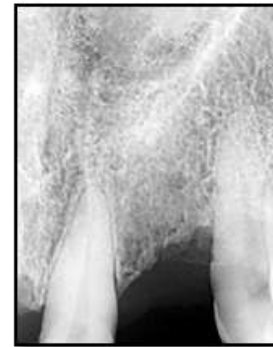

Figure 3

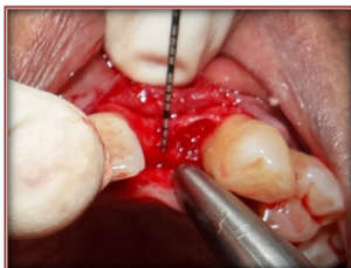

Figure 4

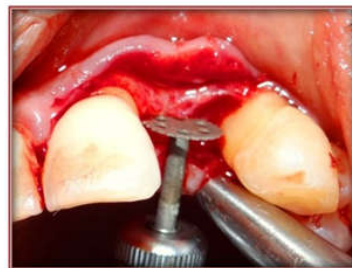

Figure 5

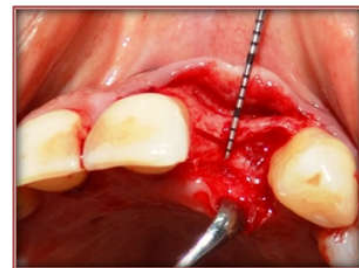


Figure 6

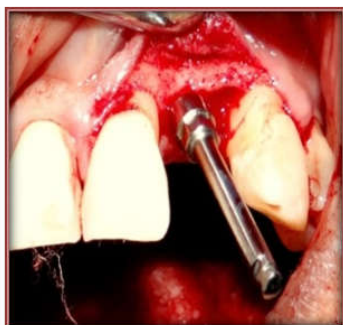


Figure 7

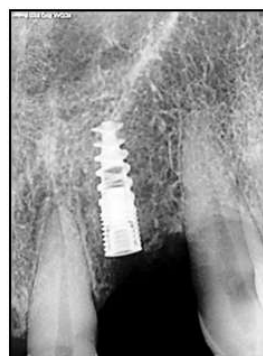

Figure 8

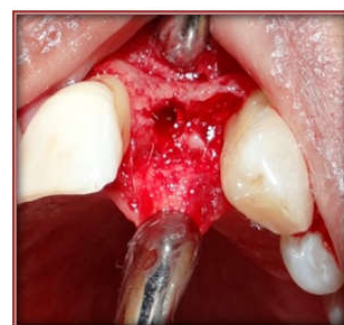

Figure 9

1. Atrophic ridges in maxilla with minimum of 2.5mm width and adequate height

Contraindications of ridge expansion (7):

1. Less than 2mm of available bone
2. Lack of marrow space between cortical plates

This clinical case report describes the technique for gradual ridge expansion in anterior maxilla (division B bone available) and simultaneous implant placement.

Case report

A 55 year old female with a chief complaint of a missing upper left lateral incisor, (Figure 1,2) requested fixed prosthesis, preferably an implant-supported. Her extra oral & intraoral examinations revealed an otherwise healthy condition. She was systemically healthy. Cone beam computed tomography was performed to evaluate the bone quality and quantity. CBCT scan revealed inadequate bucco-lingual dimension (2.7mm) of bone at the crest for implant placement (Figure 3). There was adequate cortical and cancellous bone to allow ridge expansion. It was decided to place immediate implant, using the ESSET KIT for ridge split technique. Antibiotics and Anti-inflammatory drugs were prescribed for patient after the implant placement. 0.2% chlorhexidine mouth rinse was the preoperative protocol administered for the patient. Sutures were removed after 7days. Under local anaesthesia, Full thickness mucoperiosteal flaps were raised on the buccal and palatal aspects of cortical plates (Figure 4). Crestotomy was done with crest remover to get a plane surface for the twist drill. An initial osteotomy site was created with a twist drill (1.8×10mm) in the centre between the central incisor and canine in the second quadrant. A horizontal osteotomy line was then cut along the narrow crest using a thin separating saw (7mm diameter), leaving 1mm distal to the left central incisor and 1mm mesial to the left canine of the maxilla under continuous saline irrigation (Figure 5,6). A sequence of expansion drills (1.6×10mm, 2.2×10mm, 2.7×10mm) of increasing width in the selected site was used to allow more gradual bone expansion. Then the implant site was prepared using final drill (2.8×10mm) (Figure 7) and implant of 3.3 mm × 10 mm was placed in left lateral incisor region. The cover screw was placed. (Figure 8, 9) Then tension free sutures were placed using 3-0 non-resorbable silk. Analgesics, Antibiotics and 0.2% Chlorhexidine mouth wash was prescribed. Patient recalled after 7 days for removal of sutures at the same time healing of the wound was evaluated which was satisfactory.

DISCUSSION

Narrow alveolar ridge remain a serious challenge for the successful placement of endosseous implants. It is well established that alveolar ridge less than 5 mm requires augmentation procedure in order to receive endosseous implant with healthy peri-implant bone of 1.5-2mm. (Mayor, 2014) In the past, onlay grafts harvested from hip, maxillary tuberosity, symphysis of the chin, or external oblique ridge have all been used with success in reconstruction of atrophic ridges. However bone onlay grafting procedures require a secondary

surgical site which exhibit typical postoperative morbidity associated with bone harvesting performed with chisels and burs. Additionally onlay grafts often require a healing period of 6 months to a year before dental implants can be placed, and onlay graft sometimes fails to fuse to the augmented site. The ridge split procedure provides a quicker method where in an atrophic ridge can be predictably expanded and grafted with bone allograft, eliminating the need for second site. Advantages of ridge expansion rather than onlay grafting include simultaneous implant placement, lower cost, lower possibility of cross infection from graft material and lower morbidity. This technique is only suitable for enhancing ridge width. There must be adequate available bone height (division B) for implant placement and no vertical bone defect should be present. The thinner cortical plates and softer medullary bone make the maxillary ridge easier to expand. The risk of malfracture of the osteotomised segment is high in mandible due to thicker cortical plates. (Hollinger, 1996) There are several disadvantages of this technique. It cannot achieve vertical bone height only width is possible. It is operator dependant technique, with substantial learning curve and is difficult to perform on a single tooth than on entire ridges, where the operator can take advantage of the elasticity of a long alveolar ridge. (Mayor, 2014) While many studies have shown positive outcomes with the single-stage split ridge technique, Elian *et al.* (Mayor, 2014) and Enislidis *et al.* (Elian, 2008) reported that the two-stage approach is preferable to simultaneous ridge expansion with implant placement. The authors report that although it increases the necessary time until case completion, the two-stage approach reduces operative and postoperative complications and provides a generally more stable outcome.

Again if the complication arises and bone loss occurs, the patient is left with a larger bone defect than before (Eni Slidi, 2006). If favourable conditions are not present, clinician might prefer Onlay augmentation. Therefore, appropriate case selection and surgical technique is of great importance when considering the application of this technique

Conclusion

There are many methods for augmentation for implant placement in deficient alveolar ridges of which ridge split or spreading are advocated in cases where present ridge width is minimum of 2.5 mm (Sujata, 2009) The most important factor for successful ridge split cases is careful patient selection and bone evaluation. Generally site heals similar to fracture repair of bone. Although this surgical approach may be used in both the jaws. It is better suited for maxilla. thus to satisfy the ideal goals of implant dentistry augmentation of deficient alveolar ridges is an important aspect of dental implant therapy with the end goal to provide functional restoration that is in harmony with the adjacent natural dentition as in this case report.

REFERENCES

- Carl E. Misch 1991. Contemporary Implant Dentistry 2nd edition:89-10
- Elian N, Jalbout Z, Ehrlich B *et al.* 2008. A two stage full arch ridge expansion technique: Review of Literature & Clinical Guidelines. *Implant Dent*, 17:16-23.

- EniSlidis, Wittwer G, Ewers R. 2006 Preliminary report on staged ridge splitting technique for implant placement in the mandible: A technical note. *Int J. Oral Maxillofac Implants*, 21:445-449.
- Gary W. Coatoam & Angelo Mariotti. 2003 The segmental ridge split procedure. *J Periodontol.*, 74(5):757-770.
- Guirado JL, Yoguero MR, Carrion, Valle MJ, Zamora GP. 2005 Mar. A Maxillary ridge splitting technique followed by immediate placement of implants: A case report. *Implant Dent.*, 14(1):14-20
- Hollinger J, Wong ME. 1996. The Integrated process of hard tissue regeneration with special emphasis of fracture healing. *Oral Surg Oral Med Oral Pathol Oral Radiol Endod.*, 82(6):594-606.
- Jaw-Min Yoon, Yong-ju Jang et al. 2011. The long term clinical stability of implants placed with ridge splitting technique. *The Journal of Korean academy of Implant Dentistry*, 30(1):1-8
- Massoumeh Khoshhal, Parviz Tarkzaban, V. Faribarz, Shilan Razaghi, 2013. December Mandibular ridge splitting & Gradual bone expansion Technique for Immediate Placement of Implant in Posterior Thin Region: A Clinical Report. *Avicenna J Dent Res.*, 5(2) : e19463
- Mayor S Khairnar, Darshana Khairnar, Kedar Bhakshi, 2014. Modified ridge splitting and bone expansion osteotomy for placement of dental implant in esthetic zone. *Contemp Clin Dent.*, 5(1);110-114
- Nedir R, Bischof M, Briaux JM, Beyer S, Szmukler-Monclear S, Bernard JP. 2004. A 7 year life table analysis from a prospective study on ITI implants with special emphasis on the use of short implants. Results from a private practice. *Clin Oral Implants Res.*, 15(2):150-157.
- Neophytos Demetriades, Jong IL park, Constantinos Laskorides, 2011. Alternative bone expansion technique for implant placement In Atrophic Edentulous Maxilla & Mandible. *Journal of oral Implantology.*, 37(4):463-471.
- Sujata Goyal, Shankar Iyer. Bone manipulation technique. January-April 2009 *International Journal of Clinical Implant Dentistry*, 1(1):22-31.
