



ISSN: 0975-833X

Available online at <http://www.journalcra.com>

International Journal of Current Research  
Vol. 8, Issue, 02, pp.26841-26842 February, 2016

INTERNATIONAL JOURNAL  
OF CURRENT RESEARCH

## CASE STUDY

### IMAGE IN MEDECINE: SOLID PSEUDOPAPILLARY TUMOR OF PANCREAS REVEALED BY ACUTE PANCREATITIS

\*<sup>1</sup>Hedfi Mohamed, <sup>2</sup>Charfi Mehdi, <sup>1</sup>Messaoudi Ikram, <sup>2</sup>Bouhawala Habib and <sup>1</sup>Chouchene Adnene

<sup>1</sup>Department of Surgery, FSI Hospital Marsa, Tunisia

<sup>2</sup>Department of Radiology, FSI Hospital Marsa, Tunisia

#### ARTICLE INFO

##### Article History:

Received 27<sup>th</sup> November, 2015  
Received in revised form  
25<sup>th</sup> December, 2015  
Accepted 11<sup>th</sup> January, 2016  
Published online 27<sup>th</sup> February, 2016

##### Key words:

Solid,  
Pseudopapillary,  
Tumor,  
Pancreas.

#### ABSTRACT

Solid pseudopapillary tumors (SPTs) are unusual neoplasms of the pancreas of uncertain histogenesis that occur mostly, but not exclusively, in young women. The pathologic features and immunophenotype of SPT are unique and well characterized. Despite its low malignant potential, proximately 15% of patients with SPT develop metastatic disease, mostly involving the liver or peritoneum. Even in the presence of disseminated disease, the clinical course is usually protracted, and the overall 5-year survival is reportedly 97%. We have encountered 2 cases of SPT possessing unusual pathologic features and exhibiting an aggressive clinical course.

Copyright © 2016 Hedfi Mohamed et al. This is an open access article distributed under the Creative Commons Attribution License, which permits unrestricted use, distribution, and reproduction in any medium, provided the original work is properly cited.

**Citation:** Hedfi Mohamed, Charfi Mehdi, Messaoudi Ikram, Bouhawala Habib and Chouchene Adnene, 2016. "Image in Medicine: Solid Pseudopapillary tumor of pancreas revealed by acute pancreatitis", *International Journal of Current Research*, 8, (02), 26841-26842.

## INTRODUCTION

Solid pseudopapillary tumor, otherwise known as solid and cystic tumor or Frantz tumor, is an unusual form of pancreatic carcinoma. Its natural history differs from the more common pancreatic adenocarcinoma in that it has a female predilection, is more indolent, and carries a better prognosis. Metastatic disease can occur, usually involving the liver, and its management is not well defined. (Coleman *et al.*, 2003; Liu *et al.*, 2011) Solid pseudopapillary tumor of the pancreas is a rare malignancy. Survival following primary resection approaches 95% at 5 years. Metastatic disease, although rare, usually involves the liver and/or peritoneum. Given the paucity of reported cases, the management of metastatic disease is, to date, poorly defined. This case demonstrates a favorable short-term outcome with aggressive surgical treatment of both the primary and metastatic tumor. Herein we report a case of a patient 62 years old admitted with abdominal pain, the CT scan

performed showed a cystic tumor of 6 cm size of left pancreas (Figure 1). Splenopancreatectomy was performed (Figure 2). histological exam of tumor showed pseudopapillary pancreatic tumor.

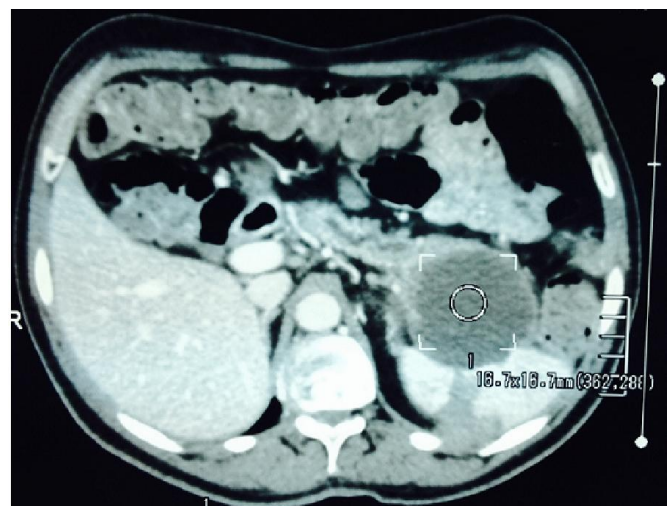
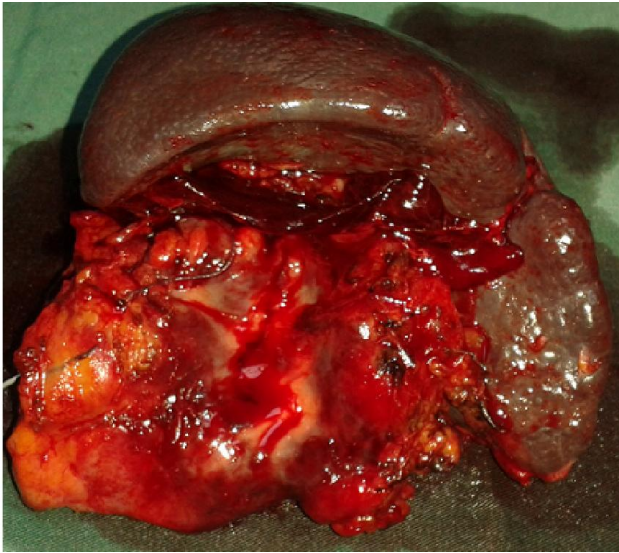


Fig. 1. CT scan cystic tumor of pancreas

\*Corresponding author: Hedfi Mohamed  
Department of Surgery, FSI Hospital Marsa, Tunisia.



**Fig. 2.** Splenopancreatectomy specimen

## REFERENCES

- Coleman KM, Doherty MC, Bigler SA. 2003. Solid-pseudopapillary tumor of the pancreas. *Radiographics.*, 23 (6): 1644-8.
- Liu W, Liang W, Xu S. Prevalence of small solid pseudopapillary tumors. *AJR Am J Roentgenol.*, 2011;197 (5): W964.

\*\*\*\*\*