



ISSN: 0975-833X

## RESEARCH ARTICLE

### FORGOTTEN BILIARY STENTS – AN AVOIDABLE COMPLICATION

**\*Dr. Nilay Chakrabarti, Dr. Shalaka Indap, Dr. Ratnakar Shetty and Dr. Mugdha Kowli**

Department of Surgery, K. J. Somaiya Medical College, Hospital and Research Centre, Sion,  
Mumbai 400022, India

#### ARTICLE INFO

##### Article History:

Received 26<sup>th</sup> September, 2015  
Received in revised form  
24<sup>th</sup> October, 2015  
Accepted 29<sup>th</sup> November, 2015  
Published online 30<sup>th</sup> December, 2015

##### Keywords:

Retained biliary stents,  
Complications,  
Stent Registry,  
Biodegradable stents,  
Poly-L-Lactic Acid Stent.

#### ABSTRACT

Endoscopic Retrograde Cholangio Pancreatography (ERCP) with biliary stenting is one of the most commonly performed endoscopic procedures for preoperative biliary decompression in obstructive jaundice of benign or malignant etiology. In patients with concomitant calculous cholecystitis, a laparoscopic cholecystectomy is performed soon after, and in the absence of a specific indication to the contrary, most such stents are removed 6-8 weeks later. In malignant disease however, the duration of stenting would be dictated by considerations related to the specific treatment modality used. However, some patients are lost to follow up for a stent removal having got almost immediate symptomatic relief from biliary obstruction, blissfully unaware of the complications that may ensue due to an unremoved stent. Retained stents may remain asymptomatic for years, or more commonly, present with blockage and delayed complications requiring another, and often more difficult intervention. Complications related to forgotten biliary endoprosthesis have been documented, some left behind for even as long as 10 years. Prevention is the best option in tackling this situation and detailed instructions to the patient along with thorough documentation of the indwelling stent can go a long way in achieving this. Creating a Stent Registry has also been suggested in this context. The recent invention of the biodegradable biliary stent, one which disintegrates in the biliary tree after a predetermined period and therefore does not require removal, can provide an answer in this scenario. While research has identified Poly-L-Lactic Acid (PLLA) as the material of choice for manufacture of such a stent, use of this device is limited at present with cost and availability being the main hurdles preventing its widespread use. However the way forward undoubtedly lies in its wider use thus preventing a perfectly avoidable complication arising out of a "forgotten stent".

Copyright © 2015 Nilay Chakrabarti et al. This is an open access article distributed under the Creative Commons Attribution License, which permits unrestricted use, distribution, and reproduction in any medium, provided the original work is properly cited.

**Citation:** Nilay Chakrabarti, Shalaka Indap, Ratnakar Shetty and Mugdha Kowli, 2015. "Forgotten Biliary stents – An avoidable complication", *International Journal of Current Research*, 7, (12), 24320-24327.

#### INTRODUCTION

Biliary stenting following Endoscopic Retrograde Cholangio Pancreatography (ERCP) for choledocholithiasis ensures free drainage of bile after common bile duct clearance, and occasionally, but not as commonly, pancreatic duct stenting is undertaken in pancreatic disease. In the former, it is a routine practice to subsequently subject the patient to an early laparoscopic cholecystectomy for the cholecystitis, followed by a stent removal 6-8 weeks later. However, a biliary stent may be kept longer if specifically indicated as in biliary strictures. Complications related to stents are well documented from the early days of biliary stenting as far back as in 1985 by Mueller *et al.* (1985). While it cannot be denied that complications may occur following routine stenting too, presence of a stent in the biliary tree left behind for a long duration is especially fraught with danger since, the stent though crucial in patient management, is undoubtedly a foreign body.

Retained or forgotten stents have been reported even after ten years after insertion, while stent migration requiring subsequent surgical intervention has also been reported (Bajbouj, 2008 and Diller, 2003). Biliary ascariasis in patients, especially those who have undergone sphincterotomy/stenting, is also a recognized phenomenon (Gupta *et al.*, 1998). Complications related to a forgotten stent documented in literature include recurrent cholangitis, biliary strictures and formation of a stone around the retained stent, the "stentolith" (Gupta, 2013). While every effort is made towards optimization of the duration of stenting, there is the occasional patient who plays truant and is lost to follow up for a stent removal. Here we review literature associated with a forgotten biliary stent with a brief reference to two of our patients who presented with a forgotten stent.

#### DISCUSSION

First performed by Professor Soehendra in 1979, biliary stenting is one of the most commonly performed endoscopic procedures today (Soehendra, 1979). Biliary (and urinary tract stenting) is now routine and in most instances the stenting

**\*Corresponding author: Dr. Nilay Chakrabarti**

Department of Surgery, K. J. Somaiya Medical College, Hospital and  
Research Centre, Sion, Mumbai 400022, India

precedes another therapeutic intervention, with subsequent endoscopic stent removal 6-8 weeks later. Very rarely would the stent be required to be kept longer, though there are situations such as that reported by Bajboj *et al.* where a patient with a biliary endoprosthesis followed up as long as 10 years after its insertion and Patel *et al.* who reported an emergency presentation of a stent forgotten in the biliary tract for 17 years presenting with acute cholecystitis and a 'stentolith' (Bajboj, 2008 and Patel, 2014).

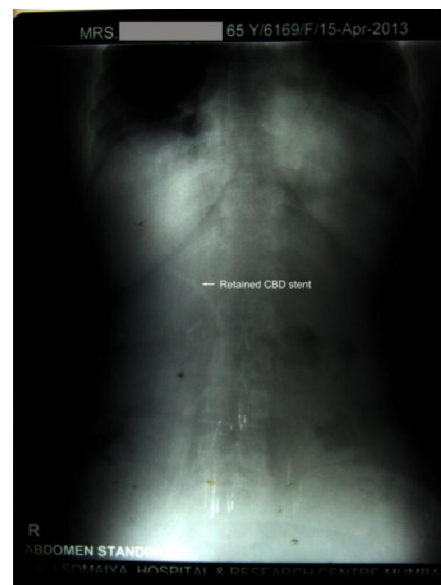Even though biliary stenting is routinely performed, complications have been reported, the most common being a blocked stent with cholangitis, and less commonly stent migration resulting in gut perforation, ascariasis of the biliary tree following the sphincterotomy, or a rare colo cutaneous fistula following stent migration (Storkson, 2000; Gupta *et al.*, 1998 and Figueiras, 2001). Most such complications follow stenting of long duration or a retained stent in the biliary tree; however these incidents certainly cannot detract from its mandatory use in the obstructed biliary system. While the presence of various foreign bodies in the biliary tree have been documented such as a fish bone, a gauze piece, cystic duct clips, or even shrapnel resulting in complications, an entirely different scenario arises due to a 'forgotten stent' where the patient himself fails to come back for stent removal at the prescribed time and only appears much later with a related or unrelated complaint (Kaji, 2004; Cipolletta, 1997; Kitamura, 1995 and Mitchell *et al.*, 1991). Stent removal being a day care procedure, the onus is on the patient to come back for a stent removal following discharge from hospital and such an oversight can result in a perfectly avoidable complication.

It would not be out of place here to make a brief mention of a useful corollary to this situation that has been reported by urologists where forgotten ureteral stents have been known to result in several complications, such as ureteric obstruction due to encrustation around the stent and even going as far as renal failure in some instances. Of the several studies highlighting this, is one reported by Ahmet Ali Sancaktutar *et al.* on forgotten and encrusted Double J ureteral stents in 22 children. While each of the stents were ultimately removed, it involved a mean of 1.5 endoscopic interventions ranging from ureteroscopy, endoscopic cystolithotripsy and retrograde intrarenal surgery with a mean hospital stay of 4.4 days (Ahmet Ali Sancaktutar *et al.*, 2013). Another such study is that reported by Aron *et al.* which reviewed ureteral stent records over a 10 year period from 1994 to 2004 in patients with forgotten stents in the only functioning kidney which had led to chronic renal failure. While a third of these patients were unaware of their stent, the others had chosen to 'ignore' it.

The median dwelling time of the stents was reported as 39 months while serum creatinine in these patients ranged from 4-14mg/dl. The study which quite understandably concluded that it was disastrous to have an unremoved, encrusted stent in the urinary tract, also noted that such cases are still seen in spite of increasing patient awareness (Aron *et al.*, 2006). Two other studies in this context are important since the suggestions in them can have a significant bearing in tackling the problem of the forgotten biliary stent too. One by Hoscan MB *et al.* who, while sharing the concern with complications arising out of a forgotten ureteral stent, looked at solutions to the problem in

the form of an electronic stent extraction reminder facility, or a possible computer based tracking system using a short message service based reminder to both patient and doctor (Hoscan, 2013). The second by Withington *et al.* suggested the use of a bar coded wrist band on the patient, details of which are scanned into a registry which automatically books an appointment for stent removal (Withington, 2014).

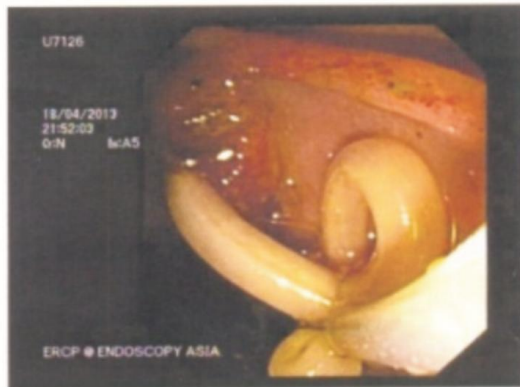
Forgotten biliary stents can result in several complications in the form of stent clogging with resultant cholangitis, ascariasis of the biliary tree, obstructive jaundice and pancreatitis. If retained long enough the stent may even result in a stone formation around itself. One of the more recent studies reviewing the long term effects of forgotten biliary stents is by Mehmet Odabasi *et al.* from Turkey in August 2014 which reported a series of cases with a wide range of complications resulting from a retained stent (Mehmet Odabasi *et al.*, 2014). It is well known that ascariasis of the biliary tree is not an uncommon occurrence in endemic areas. However there is a definite increase in its incidence in patients who have undergone a sphincterotomy and available literature has widely documented the presence of biliary ascariasis in patients with a CBD stent in situ for a prolonged duration. The worm most commonly migrates into the common bile duct across the papilla leading to complications ranging from cholangitis, cholecystitis and pancreatitis, to liver abscesses and biliary strictures (Gupta *et al.*, 1998). In most such patients the worm dies but occasionally may survive as proved by live extractions of such worms on ERCP. Analysis of stone fragments extracted from the common bile duct have occasionally shown fragments of ascaris inside them suggesting that the nidus for stone formation has been a worm or pieces of it (Gupta, 1998). One of our patients with a retained stent was asymptomatic except for upper abdominal pain of a few days duration. A history of jaundice a year ago along with that of an 'endoscopic procedure' (? a possible biliary stenting) was obtained. Plain X ray revealed the faint outline of a biliary stent (Fig. 1).



**Fig.1 Case 1. Patient presented with vague pain in abdomen with past h/o endoscopy. X ray abdomen showing retained CBD stent**

It was only during ERCP that a live roundworm (and calculi) was also seen in the CBD apart from the previous stent (Fig 2).

Name : ██████████ Age 65 Number : 7126  
 Doctor : ██████████ HOSPITAL Sex F Date : 18/04/2013



**Fig. 2. Case 1. ERCP images showing round worm being extracted from the Common Bile Duct**

The previously placed stent had to be removed piecemeal, duct clearance achieved by removal of the worm as well the calculi in the bile duct, and a fresh 10Fr stent was inserted in the CBD. This was followed by laparoscopic cholecystectomy four days later and stent removal after six weeks. Clogging of a biliary stent is a well known phenomenon, more so with the plastic stents which although affordable, clog after 3-4 months (Kenneth, 2005). The process is believed to be initiated by adherence of a biofilm of bacteria along the inner surface of the stent followed by a gel like glycocalyx formation which protects it from antibiotics, as also from the shearing effects of bile flow and the patient's immune system. Adding to this is the mechanism believed to be mediated by the release of the enzyme beta glucuronidase from *E.coli* which deconjugates bilirubin glucuronide with resultant precipitation of calcium bilirubinate, which then combines with glycoprotein to form calculi (Virinder Kumar Bansal *et al.*, 2009). An increase in the biofilm with trapping of insoluble crystals, along with refluxed duodenal contents and other cellular debris would then lead to stent occlusion. A relevant study in this context is the one by Emilio Guaglianone *et al.* where biliary stents in 28 patients were removed and subjected to culture, gradient gel electrophoresis and electron microscopy in an attempt to establish the role of bacterial (aerobic as well as anaerobic) and fungal colonization of these stents with biofilm formation on its luminal aspect resulting in subsequent stent blockage. It was seen that except for one stent, all others showed a mixed microbial growth, both aerobic as well as anaerobic, including fungi, with Gram positive enterococcus fecalis being the commonest aerobic organism isolated.

It was also suggested that the production of 'slime' by most of the cultured enterococci played an important role in bacterial colonization which leads to an occluded stent and enterococci which carry an aggregation substance gene could be more selectively associated with colonization of biliary stents. (Emilio Guaglianone, 2010). Another similar study by Albert K Groen reported the analysis of the contents of occluded biliary stents in 21 patients. Though bacterial growth was

detected in the clogged stent it was not seen in abundance; protein, insoluble residue (plant fibres) and bile acids/lecithin constituted 25%, 20% and 15% respectively of the sludge in the blocked stent. When the protein fraction of the sludge in the blocked stent. When the protein fraction of the sludge was subjected to SDS-polyacrylamide gel electrophoresis it always showed two major bands of 16 and 13k Dalton proteins, ones which bind most avidly with the stent wall. The study concluded that the initial phase of stent blockage is always protein adsorption followed by adhesion of other materials including bacteria, unconjugated bilirubin and food fibres to the stent wall (Albert K Groen *et al.*, 1987).

While this could happen with any stent, it has been conventionally believed that effect was more marked with the latex stents as compared to those made of silicone which were less reactive. This fact has however not been conclusively proved in animal studies carried out on pigs by Koivusalo *et al.* and published in 1996, where biocompatibility of latex and silicone T tubes was studied after their insertion into the porcine common bile duct. In this study with 30 animals divided into 2 groups of 16 and 14, a latex or silicone T tube was inserted into the common bile duct either after a choledochotomy or a  $\frac{3}{4}$  transaction of the CBD followed by suturing over the T tube respectively. Reoperation and harvesting of the ducts from the two groups after 2 and 6 weeks respectively followed by electron and light microscopy, as well as cell culture toxicity with a DNA synthesis inhibition test showed that while the latex T tubes were toxic, those made of silicone were non toxic. However final conclusions drawn at the end of the 6 week study period indicated that the tissue reactions in the bile duct wall were similar and neither material appeared to be completely harmless for the porcine CBD wall (Koivusalo *et al.*, 1996). In fact, several randomized trials comparing Teflon stents (without side holes, the Tannenbaum stent) against standard polyethylene stents (with side holes) also have not demonstrated any improvement in the patency rates (Catalano, 2002).

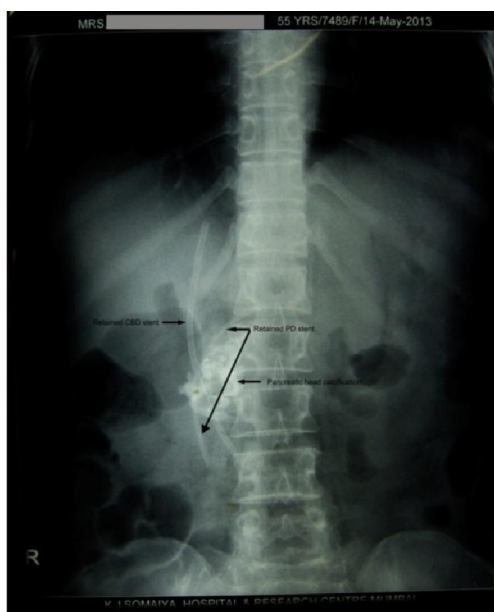
Various strategies have been adopted in an attempt to prevent, or at the least retard, clogging of the stent such as use of prophylactic antibiotics, an antibiotic impregnated stent, the administration of bile altering agents such as ursodeoxycholic acid, alterations in stent design or even placement of a stent in the common bile duct with an intact sphincter of Oddi. However the only step which has seemed to have some impact is the use of larger diameter stents (Kenneth, 2005). A "stentolith" is a term coined in this context which refers to a large concretion of such crystals around a stent appearing like a stone, and most often blocking it, an occurrence more likely with long duration stenting or indeed a stent forgotten in the biliary tree (Gupta, 2013 and Virinder Kumar Bansal, 2009). Both, an open choledochotomy approach as well as laparoscopic removal of a stent with a 'stentolith' has been reported (Gupta, 2013 and Virinder Kumar Bansal, 2009). In our patient while the common bile duct did need to clear of calculi at the time of removal of the retained stent, a classical stentolith was not seen.

The other problem relates to stent migration and has been described in 5-7% of patients following biliary stenting (Kenneth, 2005). Duodenal wall perforation following



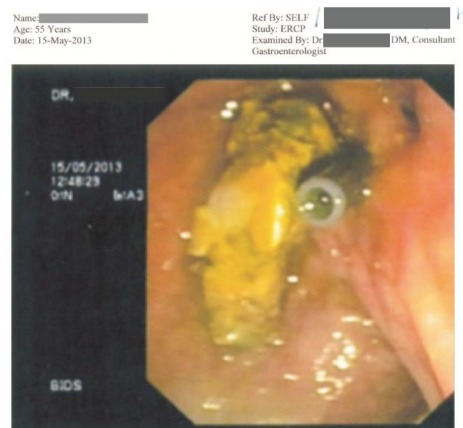
ulceration and pressure necrosis may occur following insertion of a straight stent with a long intraduodenal part (Kenneth, 2005). Percutaneous removal of such a stent following duodenal perforation has been reported, while other similar reports by various authors relate to duodenal and small bowel perforation secondary to a migrated biliary stent (including one in a patient with an incisional hernia and even in a liver transplant patient) thereby requiring a surgical intervention (Bui, 1995; Saranga Bharathi, 2006; Storkson *et al.*, 2000; Diller, 2003; Akimboye *et al.*, 2006; Esterl, 1997). Incidents of other more dangerous complications due to a migrated stent have included sigmoid colon perforations reported by Anderson *et al.* and Elliott *et al.* a rare colo cutaneous fistula and even fatal necrotizing fasciitis following a migrated biliary stent reported by Marsman *et al.* (Anderson *et al.*, 2007; Elliot and Boland, 2003; Figueiras *et al.*, 2003 and Marsman, 1996). Needless to say, the longer a stent is left in situ, more is the chance of stent migration.

Though the majority of biliary stenting and its complications are described for the CBD, there is a smaller subgroup of patients who undergo stenting of the pancreatic duct. Prolonged pancreatic duct stenting is also associated with complications related to recurrent cholangitis and even stent migration, though this is rare. Pancreatic duct stents can become stuck in the small bowel, especially in patients who have multiple bowel adhesions. Shapiro AM *et al.* have reported on calcific intra pancreatic embedding of a pancreatic duct stent present in situ for a prolonged duration and warned against this as a danger of long duration endoscopic retrograde pancreatic duct stenting (Shapiro, 1999). In another of our patients a background of intermittent upper abdominal pain for 2-3 years and an acute exacerbation prompting this hospital visit with elevated amylase and lipase levels was suggestive of chronic(?) relapsing) pancreatitis. Plain X ray showed shadow of a retained bileduct stent, a possible pancreatic duct stent, as well as pancreatic head calcification (Fig. 3).



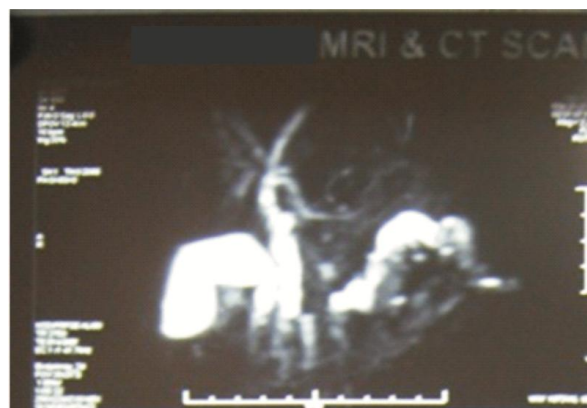**Fig.3 Case 2. Patient presented with chronic abdominal pain with past h/o endoscopy. X ray abdomen showing retained stent in CBD and pancreatic duct and pancreatic head calcification**

A CT scan confirmed these findings including the presence of a second stent in the pancreatic duct. EUS and ERCP was performed and reported as chronic pancreatitis with evidence of a blocked CBD stent, a pancreatic duct stent and pancreatic duct calculi (Fig.4).



**Fig. 4. Case 2. ERCP images showing calculus being extracted from pancreatic duct**

Cholangiogram revealed smooth narrowing of the lower CBD with upstream dilatation. No stones were seen in the CBD but multiple dense calcifications were seen in the pancreatic head region on EUS. Though the reason for the previous stenting could not be ascertained, removal of this stent, (which in all probability was non functional), was long overdue. It was indeed fortunate that the complication reported above had not occurred. Following endoscopic stent removal, MRCP confirmed chronic pancreatitis (pancreatic head calcification had already been seen on the X ray) in the form of atrophy of the proximal main pancreatic duct with a dilated mid portion of the duct (Fig. 5).



**Fig. 5. Case 2. MRCP image showing dilated mid pancreatic duct**

In view of these findings our patient underwent a lateral pancreaticojejunostomy, along with cholecystectomy. Though a stent related complication could occur at any time following its insertion, it would not be out of place to suggest that the chances of such an occurrence are directly proportional to the duration of stenting. In this context, a forgotten stent is a luxury that the patient certainly cannot afford! A possible solution to this conundrum lies in the most recent advance in the use of biodegradable biliary stents which disintegrate after a certain period following their placement in the biliary tree.

Apart from problems related to a biofilm accumulation over the stent and proliferative changes being greatly reduced, an additional benefit to the patient would be of not having to come back for a stent removal. Such a stent also offers a solution to problems of long term complications and permanency associated with the other significant advance in stent technology, i.e. the expandable metal biliary stent (Kenneth *et al.*, 2005). Though historically biodegradable materials for surgical use have been around for several years, manufacture of stents made of these has not developed at the same pace. Hurdles which have come in the way include factors such as inadequate radial strength of the stent, an inflammatory response to the material, as well as fracture of the stent in some instances. Biodegradable coronary stents have been in vogue for some time now with the earliest reports being from Japan by Tamai *et al.* published as far back as in 2000 on stents made of Poly-L-Lactic Acid (PLLA) for use in coronary arteries successfully (Tamai *et al.*, 2000). Though the retained or forgotten stent situation was never the question in coronary artery stenting, their usefulness has been aptly described by Colombo and Karvouni as something “fulfilling the mission and stepping away” (Colombo, 2000).

Solutions for a ‘forgotten stent’ situation led to almost simultaneous research on the possible use of biodegradable stents in the urinary as well as in the biliary tract and animal studies led the way in this regard. An important study in this context is the one by Ben H Chew *et al.* in 2013 which based its findings on an animal study involving two groups of pigs unilaterally implanted with either a biodegradable or a biostable stent in the ureter. A necropsy and histological examination 4 weeks later revealed that 90% of the biodegradable stents had totally degraded while one stent had fragmented to three pieces less than 1.5cm in size. While hematological and renal parameters were similar in the two groups, there was significantly less hydronephrosis with fewer abnormal histological findings in the group with biodegradable stents leading to the conclusion that the third generation biodegradable ureteric stent is a safe and effective alternative to the conventional polymer stent with equivalent drainage (Ben, 2013).

Studies on trying to find the ideal material for such a stent also centered on the use of Poly l-lactide-co-Glycolide (PLGA) and Poly L-Lactic Acid (PLLA), the material which had been earlier developed for biodegradable coronary stents. Several animal studies preceded attempts to use biodegradable biliary stents in human subjects. Initial studies on choosing the most appropriate material for the stent included in vitro and in vivo studies using PLGA for CBD stents. In one such study PLGA, molar ratio LA/GA = 80/20, was used to prepare circular tube and dumb bell shaped stents and then tested to determine their in vitro degradation behavior in bile. Parameters used to determine suitability included morphology, weight loss, and molecular weight changes along with evaluations of the mechanical properties of the specimen. Subsequently, circular radio opaque tube-shaped stents made of PLGA were used in dogs that had undergone common bile duct exploration with primary suturing of the CBD. Results were analyzed after imaging of stents in vivo including levels of serum liver enzymes and a histological study of the CBD, which showed

that the PLGA stents exhibited the required biomedical properties.

Spontaneous disappearance from CBDs was noted in 4–5 weeks time, the degradation period and function matching the requirements in repair and reconstruction of CBD, thereby reducing T-tube-related complications (Esterl *et al.*, 1997). However comparisons between the various materials have gone in favor of PLLA as the preferred material for manufacture of biodegradable biliary stents (Fig. 6).

Polymer	Crystallinity	Degradation Rate (depends on molecular weight of polymer)
PGA	High Crystallinity	2 - 3 months
PLLA	Semi-crystalline	> 2 years
PDLA	Amorphous	12 - 16 months
PLGA	Amorphous	1 - 6 months (depends on ratio of LA to GA)

Source: [http://patentimages.storage.googleapis.com/WO2009029744A1/imgf000016\\_0001.png](http://patentimages.storage.googleapis.com/WO2009029744A1/imgf000016_0001.png)

**Fig. 6. Comparison between various materials used in manufacture of biodegradable biliary stents**

Other animal studies include those by Yigang Chen *et al.* where techniques for safe placement of biodegradable stents in the common bile duct in rabbits had been described and Shi J *et al.* from China who used a new paclitaxel coated PLLA biodegradable stent in mongrel dogs (Yigang Chen *et al.*, 2013; Shi *et al.*, 2013). Itoi *et al.* from Japan placed a braided, self-expandable, biodegradable stent endoscopically into the pancreatic and bile duct in pigs which were then studied further after a necropsy to draw conclusions (Itoi, 2011). Moving ahead from animal studies to use in human subjects, the use of biodegradable stent materials in humans for non coronary use started with the trial by Fry and Fleisher in 1997 almost two decades ago, where a coil spring expandable stent made of a single wire of polyglycolide was implanted in a patient with an oesophageal stricture. However the result was not good since the stent fractured proximally due to premature loss of its expansile strength and in the process led to occlusion of the oesophageal lumen requiring an endoscopic removal (Fry, 1997). Since then there has been significant advance and biodegradable stents have been used in the biliary tree in situations such as in stenting following post cholecystectomy leaks and in biliary strictures with good results. (Johanna Laukkarinen, 2007 and Mauri, 2013) A biliary stent of PLLA made of polymer strands in a tubular mesh form, with radio opacity being ensured by the incorporation of Tantalum strands in it, was initially favored for use in humans (Fig. 7).



Source: [http://www.carefusion.co.uk/Images/Interventional\\_Specialties/IS\\_Distributors/nitinella\\_plus\\_biliary\\_stent\\_carousel\\_img2.jpg](http://www.carefusion.co.uk/Images/Interventional_Specialties/IS_Distributors/nitinella_plus_biliary_stent_carousel_img2.jpg)

**Fig.7. Basic structure of the biodegradable stent**

Results in 50 patients in a multi center trial was reported in the Digestive Diseases Week (DDW) 2001 which revealed that while the compression force of the stent was good, inadequate

radial force exerted by these stents required balloon dilatation for expansion. Additional problems were related to bile duct lumen obstruction due to fragmentation and residue (Kenneth F Binmoeller and Biliary stenting, 2005). Modifications of these stents have been based on studies in the porcine bile duct with good results as reported in the DDW 2002, which included the use of the PLLA stent with elastometric axial runners which increases the radial force (thus avoiding a subsequent balloon expansion) as well as having significantly less complications or problems of bile duct integration (Kenneth F Binmoeller and Biliary stenting, 2005). One such device for use in humans is the “Archimedes” biodegradable stent, which was used for the first time in Asia at the UKM Medical Centre in Kuala Lumpur, Malaysia, in March 2014 on a 56 year old man suffering from acute cholangitis (<http://www.onenewspage.com/rss/latest/press+releases.rss> 03/23/14-16.13) (Fig.8).



Source: [http://stronmedical.com/images/biodegradable\\_product1.jpg](http://stronmedical.com/images/biodegradable_product1.jpg)

**Fig. 8 The first biodegradable biliary stent used- “Archimedes Device”**

It is reported to come with three degradation times to accommodate the various disease states that require different indwelling times for treatment; a fast absorbing (weeks), medium absorbing (months), and a long lasting one which can stay even up to six months, remaining in the biliary tree before it is slowly hydrolyzed by the body. Other modifications of such a stent are bound to come with rapid ongoing research in this area. With patent related issues and FDA and other approvals still pending, commercial use of these devices is obviously not yet widespread but this device is definitely the solution to the “forgotten stent” situation. The use of such stents is increasing and if these hurdles are overcome, this certainly is the future of biliary stenting in the days to come.

## Conclusion

A “forgotten stent” is a reality in the context of biliary stenting. An entirely avoidable situation, it can be associated with severe complications often requiring another surgical or endoscopic intervention. Apart from the additional cost and hospital stay that this entails, it is also important to remember that removing such a stent may not be easy especially in a migrated stent or one with a large concretion around it. The key therefore lies in prevention of the “forgotten stent” situation. Meticulous instructions to the patient and thorough documentation regarding the presence of an indwelling stent following an endoscopic procedure can go a long way in preventing this situation. Suggestions have been made regarding the setting up of a computerized ‘Stent Registry System’ to

track patients with a stent which would need removal and this appears to be an excellent idea (Virinder Kumar Bansal *et al.*, 2009). As previously discussed, a solution to the problem has been suggested in the form of an electronic stent extraction reminder facility as also a computer based tracking system using a short message service based reminder to both patient and doctor (Hoscan, 2013). The use of a bar coded wrist band on the patient, details of which are scanned into a registry is also feasible (Withington *et al.*, 2014). However, the future lies undoubtedly in the use of the biodegradable biliary stent and its wider use would obviate the need for a stent removal. At this point in time PLLA along with the modifications described appears to be the material of choice for the manufacture of the biodegradable biliary stent. Research to develop the ideal, as well as commercially viable, biodegradable stent with appropriate approval by the authorities is on, and hopefully the situation of a ‘forgotten stent’ should soon be a matter of the past.

## REFERENCES

- Ahmet Ali Sancaktutar, Senol Adanur, Berkan Resorlu, Abdulkadir Tepeler, Tevfik Ziyapak, Haluk Soylemez, Murat Atar, Yasar Bozkurt, Necmettin Penbegul, Adnan Tufek, Sevgi Yavuz. 2013. The Forgotten Ureteral Stent in Children: From Diagnosis to Treatment. *The Journal of Urology*, Volume 189, Issue 3, Pages 1054-1060
- Akimboye, F., Lloyd, T., Hobson, S, Garcea, G. 2006. Migration of endoscopic biliary stent and small bowel perforation within an incisional hernia; *Surg Laparosc Endosc Percutan Tech* 2006, 16 (1): 39-40
- Albert K Groen, T Out, K Huibregtse, B. Delzenne, F J Hoek, G.N.J. Tytgat. Characterization of the content of occluded biliary endoprosthesis. *Endoscopy*, 04/1987;19(2):57-9
- Anderson, E.M., Phillips Hughes, J., Chapman, R. 2007. Sigmoid colonic perforation and pelvic abscess complicating biliary stent migration. *Abdom Imaging*, 32(3);317-319
- Aron, M., Ansari, M.S., Singh, I., Gautam, G., Kolla, S.B., Seth, A, *et al* . 2006. Forgotten Ureteral stents causing renal failure: multimodal endourologic treatment. *J Endourol*. 20:423-8
- Bajbouj, M., Treiber, M., Ludwig, L., Frimberger, E., Schmid, R.M. Neu, B. 2008. Forgotten biliary endoprosthesis. “Follow up” after 10 years. *Endoscopy*, 40:E221
- Ben, H. Chew, Ryan F. Paterson, Kenneth, W. Clinkscales, Barry, S Levine, Shalaby, W. Shalaby, Dirk 2013. In vivo Evaluation of the Third Generation Biodegradable Stent: a novel approach to Avoiding the Forgotten Stent Syndrome. *The Journal of Urology*, February, Volume 189, Issue 2, Pages 719-725
- Bui, B.T., Oliva, V.L., Ghattas, G., Daloz, P., Bourdon, F., Carignan, L. 1995. Percutaneous removal of a biliary stent after acute spontaneous duodenal perforation. *Cardiovasc Intervent Radiol*, 18(3):200-202
- Catalano, M.F., Geenen, J.E., Lehman, G.A., *et al* . 2002. “Tannenbaum” Teflon stents versus traditional polyethylene stents for the treatment of malignant biliary stricture. *Gastrointest Endosc* 2002.55(3):354-8
- Cipolletta, L., Bianco, M.A., Rotondano, G., Prisco, A., Catalano, M., Gatto, A *et al*. 1997. Endoscopic retrieval of



- a surgical gauze from the common bile duct. *Italian Journal of Gastroenterology Hepatology.*, 29:58-61
- Colombo, A., Karvouni, E. 2000. Biodegradable stents “fulfilling the mission and stepping away” *Circulation*; 102(4); 371-3
- Diller, R., Senninger, N., Kautz, G., Tubergen, D. 2003. Stent migration necessitating surgical intervention. *Surg Endosc.* 17(11):1803-1807
- Elliot, M., Boland, S. 2003. Sigmoid colon perforation following a migrated biliary stent. *ANZ. J. Surg.*, 2003, 73(8):669-670
- Emilio Guaglianone, Rita Cardines, Claudia Vuotto, Roberta di Rosa, valentine Babini, Paola Mastrantonio 2010. Gianfranco Donelli. Microbial biofilm associated with biliary stent clogging. *FEMS Immunol Med Microbiol* 59, 410-420
- Esterl, R.M., Jr, St. Laurent, M., Bay, M.K., Speeg, K.V., Halff, G.A. 1997. Endoscopic biliary stent migration in a liver transplant recipient. *J. ClinGastroenterol.*, 24 (2):106-110
- Figueiras, R.G., Echart, M.O., Figueiras, A.G., Gonzalez, G.P. 2001. Colocutaneous fistula relating to the migration of a biliary stent. *Eur J GastroenterolHepatol* 2001.13(10): 1251-1253
- Fry, S.W., Fleischer, D.E. 1997. Management of a refractory benign esophageal stricture with a new biodegradable stent. *GastrointestEndosc*; 45(2): 179-82.
- Gupta, R., Agarwall, D.K., Choudhuri, D.D., Saraswat, V.A., Baijal, S.S. 1998. Biliary ascariasis complicating endoscopic sphincterotomy for choledocholithiasis in India, *J GastroenterolHepatol*, 13; 1072-3
- Gupta, V., Chandra, A. Noushif, M. Singh, S.K. 2013. Giant Stentolith: Complication of a forgotten biliary stent, *Endoscopy*;45(S 02):E126
- Hoscan, M.B., Trunckiran, A. 2013. Management of Forgotten Ureteral Stents. *Nephrol-Urol Mon.* 5(2): 775-6
- Itoi, T.I., Kasuya, K., Abe, Y., Isayama, H. 2011. Endoscopic placement of a new short-term biodegradable pancreatic and biliary stent in an animal model: a preliminary feasibility study (with videos). *J Hepatobiliary Pancreat Sci.* May;18(3):463-7.
- Johanna Laukkanen, Isto Nordback, JoonasMikkonen, PäiviKärkkäinen, Juhani Sand. 2007. A novel biodegradable biliary stent in the endoscopic treatment of cystic-duct leakage after cholecystectomy. *Gastrointestinal Endoscopy.* June, Volume 65; Issue 7: Pages 1063–1068
- Kaji, H., Asano, N., Tamura, h., Yuh, I. 2004. Common bile duct stone caused by a fish bone: report of a case *Surg Today.*, 34:268-71
- Kenneth, F., Binmoeller, Biliary Stenting, 2005. Old problems and new Challenges. *Gastrohep.com.* 01 October 2005.
- Kitamura, K., Yamaguchi, T., Nakatani, H., Ichikawa, D., Shimotsuma, M., Yamane, T., *et al* . 1995. Why do cystic duct clips migrate into the common bile duct? *Lancet.* 346:965-6
- Koivusalo, A., Makisalo, H., Talja, M., Cormio, L., Ruutu, M., Wolff, H., Hockerstedt, K. 1996. Biocompatibility of Latex and silicone T tubes in the porcine common bile duct: an experimental study. *Res Exp Med (Berl)* 196 (1); 53-66
- Marsman, J.W., Hoedemaker, H.P. 1996. Necrotizing fasciitis: fatal complication of migrated biliary stent. *Australas Radiol.*, 40(1): 80-83
- Mauri, G.I., Michelozzi, C., Melchiorre, F., Poretti, D., Tramarin, M., Pedicini, V., Solbiati, L., Cornalba, G., Sconfienza, L.M. 2013. Biodegradable biliary stent implantation in the treatment of benign bilioplastic-refractory biliary strictures: preliminary experience. *Eur Radiol.* Dec; 23(12):3 3304-10.
- Mehmet Odabasi, Cem Arslan, Sami Akbulut, Haci Hasan Abuoglu, Erkan Ozkan, Mehmet Kamil Yildiz, Cengiz Eris, Emre Gunay, Kemal Tekesin, and Tolga Muftuoglu. 2014. Long – term effects of forgotten biliary stents: a case series and literature review. *Int. J. Clin. Exp. Med.*, 7(8):2045-2052
- Mitchell, R., Kerr, R., Barton, J., Schmidt, A. 1991. Biliary obstruction secondary to shrapnel. *American Journal of Gastroenterology*; 86:1531-4
- Mueller, P.R., Ferrucci, J.T. Jr, Teplick, S.K., Van Sonnenberg, E., Haskin, P.H., Butch, R.J., 1985. Papanicolaou N. Biliary stent endoprosthesis: analysis of complications in 113 patients. *Radiology* 1985,156 (3): 637-639
- Patel, T.J., Rajput, S., Patel, K.S., Haribhakti, S.P. 2014. A forgotten biliary stent for 17 years:presented with perforated gall bladder and stentolith. *J. Dig. Endosc.*, 5:22-3
- Q3 Medical Devices Ltd: UKMMC became the first centre to deploy Archimedes Biodegradable stents in Asia. Page 300. <http://www.onenewspage.com/rss/latest/press+releases.rss> 03/23/14-16.13
- Saranga Bharathi, R., Rao, P., Ghosh, K. 2006. Iatrogenic duodenal perforation caused by endoscopic biliary stenting and stent migration: an update; *Endoscopy*, 38(12); 1271-1274
- Shapiro, A.M., Scudamore, C.H., July, L.V., *et al* . 1999. Calcific intra-pancreatic embedding of a pancreatic stent necessitating surgical removal—a danger of chronic endoscopic retrograde pancreatic stent placement. *Gastrointest Endosc.*, 50:860.
- Shi, J., Lv, Y., Yu, L., Zhang, B., Zhang, X., Fan, C., Geng, Z. 2013. Interest of a new biodegradable stent coated with paclitaxel on anastomotic wound healing after biliary reconstruction. *Eur J Gastroenterol Hepatol.*, 25 (12) : 1415-23
- Soehendra, N., Reynders- Frederix, V. 1979. Palliative biliary tract drainage. A new method for endoscopic introduction of a new drain. *Dtsch Med Wochenschr*,104(6)206-7
- Storkson, R.H., Edwin, B., Reiertsen, O., Faerden, A.E., Sortland, O., Rosseland, A.R. 2000. Gut perforation caused by biliaryendoprosthesis: *Endoscopy.*, 32 (1): 87-89
- Tamai, H., Igaki, K., Kyo, E, *et al* . 2000. Initial and 6 month results biodegradable and poly-L-lactic acid coronary stents in humans. *Circulation*:102(4);399-404
- Virinder Kumar Bansal, Mahesh C Mishra, Prashant Bhowate, Subodh Kumar. 2009. Laparoscopic management of common bile duct “Stentolith”. *Tropical Gastroenterology*, April 2009; 30(2):95-96

- Withington, J., Wong, K., Bultitude, M and O' Brien, T. 2014. The forgotten ureteric stent: what next? *BJU International*, 113:850-851
- Xiaoyi Xu, Tongjun Liu, Shaohui Liu, Kai Zhang, Zhen Shen, Yuxin Li, Xiabin Jing. 2009. Feasibility of biodegradable PLGA common bile duct stents: An in vitro and in vivo study. *Journal of Materials Science: Materials in Medicine*. May, Volume 20, Issue 5, pp 1167-1173
- Yigang Chen, Jun Yan, Zhigang Wang, Song Yu, Ziming Yuan, Xiaohu Wang, Xiaonong Zhang, Qi Zheng. 2013. Technique for the safe placement of a biodegradable stent into the common bile duct of rabbits, *Experimental and Therapeutic Medicine*, Vol.6 ; Issue 5: 1101-1104

\*\*\*\*\*