



ISSN: 0975-833X

RESEARCH ARTICLE

EFFECT OF CO-ADMINISTRATION OF ZINC AND SELENIUM IN CCl₄ INDUCED HEPATOTOXICITY

*¹Amol Gurav, ¹Mondal, D. B., ¹Kumar, M. ²Monalisa Sahoo, ¹Vijayakumar, H. and ³Pange, A. D.

¹Division of Medicine, Indian Veterinary Research Institute, Izatnagar, Bareilly, U.P, India

²Division of Pathology, Indian Veterinary Research Institute, Izatnagar, Bareilly, U.P, India

²Central Avian Research Institute, Izatnagar, Bareilly, U.P, India

ARTICLE INFO

Article History:

Received 31st July, 2013

Received in revised form

12th August, 2013

Accepted 04th September, 2013

Published online 23rd October, 2013

Key words:

Hepatotoxicity,

CCl₄,

Zinc and Selenium.

ABSTRACT

Effect of zinc and selenium alone and in combination was evaluated against carbon tetrachloride induced hepatotoxicity. Rats were divided into 6 groups with group I and II as healthy and diseased control. Group III, IV, V and VI received silymarin, zinc, selenium and zinc + selenium as therapeutic agents respectively. Hepatotoxicity was induced in rats by giving @ 2 ml CCl₄ + 2 ml olive oil/kg (1:1; v/v) body weight orally twice a week for 4 weeks. At the end of trial, serum biochemical alterations revealed that levels of ALT, AST and ALP increased significantly in group II as compared to healthy control whereas these levels were significantly reduced in all treatment groups which does not vary statistically from healthy group. Group II showed significant increase in LPO as well as significant decrease in SOD, GSH and Catalase in liver tissue. LPO value of group VI reduced significantly as compared to group IV and V which reveals better antiperoxidation action of zinc and selenium in combination as compared to their actions alone. Therapeutic regimen of group VI reflected best SOD and Catalase activity as compared to group IV and V. Hepatocytes of group IV and V showed mild to moderate degree of fatty changes with mild infiltration of inflammatory cells and revealed score 1-2 by histopathological scoring (HPS). Group VI showed mild degree fatty changes with mild fibrous tissue proliferation between lobules as compared to group IV and V with score of 1. Co-administration of zinc and selenium revealed synergistic hepatoprotective action in rat model.

Copyright © Amol Gurav, et al., This is an open access article distributed under the Creative Commons Attribution License, which permits unrestricted use, distribution, and reproduction in any medium, provided the original work is properly cited.

INTRODUCTION

Hepatobiliary dysfunctions occur in number of acute and chronic clinical conditions, including drug induced hepatotoxicity, infectious diseases, congenital or neoplastic diseases, metabolic disorders, degenerative process, vascular injury, autoimmune diseases and even blunt trauma. Liver is major organ for detoxification process (Tamburro, 1979) of xenobiotic compounds such as CCl₄, cadmium, arsenic etc.

These compounds are predominantly oxidized by microsomal mixed function oxidase (MFO) system along with nicotinamide adenine dinucleotide phosphate-cytochrome phosphate (NADPH-CYP) reductase enzyme system in liver (Zimmerman, 1999). Liver injury involves co-lateral oxidative/peroxidative damage of cell. A deficiency of hepatic L-glutathione (GSH) and its antioxidant partners and or free radicals species may contribute to the progression of liver disease. Oxidative stress is known to up regulate production of inflammatory cytokines. Mitochondrial oxidative damage plays an important role in the etiology of numerous oxidative stress-mediated clinical conditions; one possible protective strategy would be to enrich tissue mitochondria with antioxidants thereby limiting mitochondrial oxidative damage,

cellular injury and the initiation and progression of disease (Fariss *et al.*, 2005). Considering increasing evidences (Ohta *et al.*, 2006) that reactive oxygen species (ROS) are important mediators in liver injury, effective therapy of hepatobiliary diseases requires disease directed interventions with the aim at elimination of causative factors, reducing hepatic inflammation, minimizing fibrosis, controlling complications and initiating hepatic regeneration. Using antioxidants as supplements to protect cellular structures against oxidative stress and lipid peroxidation in liver damage is of paramount importance. The present study aims to investigate the protective effect of zinc and selenium either alone or in combination on rat liver damage induced by CCl₄.

MATERIALS AND METHODS

Animals

Wistar male Albino rats of around 150 to 200 gm body weight were procured from Laboratory Animal Resource Section (LARS) of Indian Veterinary Research Institute (IVRI), Bareilly (UP) and were housed in laboratory animal shed of medicine division. Rats were maintained under standard managemental condition and acclimatized for 1 week before the start of the actual experiment. They were fed balanced ration obtained from feed technology unit, IVRI and fresh,

*Corresponding author: Amol Gurav, Division of Medicine, Indian Veterinary Research Institute, Izatnagar, Bareilly, U.P, India

clean drinking water was offered *ad libitum*. Animals were provided 12 hours light and dark cycle. The temperature and relative humidity were maintained at $18 \pm 3^\circ\text{C}$ and $55 \pm 5\%$ respectively.

Experimental procedure

Rats were divided into six groups with 6 rats (n=6) in each group. Group I was healthy control, group II was diseased control receiving CCl₄. Hepatotoxicity was induced in rats by giving CCl₄ along with olive oil (1:1; v/v) @ 2 ml CCl₄ + 2 ml olive oil/kg body weight orally twice a week for four weeks (Doi *et al.*, 1991). All groups has received hepatotoxic dose except healthy control group. Group III received silymarin (5 mg/kg b. wt p.o), group IV received zinc (500 ppm of zinc chloride *ad lib* through drinking water), group V treated with selenium (0.1 ppm of selenium *ad lib* through drinking water) and group VI received zinc and selenium as per same dosage as described earlier. All the antioxidants were given for 28 days period. Rats were sacrificed at the end of experiment (day 28) under light chloroform anaesthesia then blood and liver samples were collected for various biochemical, oxidative stress indices and histopathological examination.

Serum biochemical profile

Biochemical parameters viz. alanine aminotransferase (ALT) and aspartate aminotransferase (AST) (Reitman and Frankle, 1957), alkaline phosphatase (ALP) (pNPP method), serum total protein and albumin (Verley, 1980), serum bilirubin (Zilva and Pannal, 1979) and serum glucose (Kaplan, 1984) were estimated using standard test kits (Span Diagnostic Ltd. India).

Liver oxidative profile

Lipid peroxidation (LPO) (Ohkawa *et al.*, 1979), catalase (CAT) (Cohen *et al.*, 1970), superoxide dismutase (SOD) (Marklund *et al.*, 1974) and glutathione (GSH) (Sedlak and Lindsay, 1968) were estimated in 10% liver homogenate. Protein content in liver homogenates was determined by the Lowry method.

Histopathological examination

Liver from all groups were processed for histopathological examination as per standard procedures (Culling, 1963). The pathological changes of fatty liver and degeneration of hepatocytes were graded (score) as normal (0), mild degree (1), moderate degree (2), severe degree (3).

Statistical analysis

Data was subjected to statistical analysis using ANOVA (Snedecor and Cochran, 1994) and Tukey multiple comparison post hoc test at $P < 0.05$ level of significance.

RESULTS AND DISCUSSION

Serum biochemical alterations revealed that levels of ALT, AST and ALP increased significantly in Gr II at the tune of 156.5 ± 20.1 , 338.5 ± 10.7 and 288.0 ± 10.9 respectively as compared to healthy and other treatment groups (Table 1). The increased activities of liver enzymes such as ALT, AST and

ALP in the serum of CCl₄ induced rats indicate damage to hepatic cells (Wolf, 1999). Damage to the cell integrity of the liver by CCl₄ is reflected by an increase in the activity of AST, which is released into circulation after cellular damage. In CCl₄ mediated toxicity increased permeability of the hepatocyte membrane and cellular leakage causes high levels of ALP in serum which is an ectoenzyme of the hepatocyte plasma membrane (Paduraru *et al.*, 1996). Muriel and Escobar (2003) reported that due to repeated doses of CCl₄ there is leakage of enzymes like AST and ALT across hepatocellular membrane and in blood indicating liver dysfunction and cellular injury. The findings of our study concur with the above reports. The levels of ALT, AST and ALP in all treatment groups were significantly reduced as compared to Gr II which does not vary statistically significant from healthy group. It shows the hepatoprotective effect of all the treatment regimens to prevent the possible hepatocellular injury. The value of serum ALT and ALP of Gr VI does not vary significantly as compared to Gr IV and Gr V but it shows insignificant variation from same groups.

The ALT level in group IV (Zinc) was reduced to 58.9 ± 1.9 level which may be attributed to the anti-peroxidative effect of the zinc in CCl₄ induced liver injury (Dhawan and Goel, 1995). The reduction in level of liver enzymes in Gr V showed the efficacy of selenium in preventing hepatocellular injury due to CCl₄. Selenium acts as a free radical scavenger due to presence of selenoprotein-P in plasma membrane (Burk and Hill, 1993). Group VI showed reduction in ALT value (54.7 ± 3.2) which was non-significantly lower as compared to either Gr IV (60.3 ± 2) or Gr V (58.9 ± 1.9) alone. The above effect may be due to synergistic action of zinc and selenium in reducing the hepatotoxicity (Jihen *et al.*, 2009). In contrast the levels of ALP in groups III, V and VI were considerably higher than the healthy control group which may be due to concurrent increase in ALP values by CCl₄ induced nephrotoxicity. Significant reduction in total protein (4.4 ± 0.9) and albumin (2.9 ± 0.1) in Gr II as compared to all the groups except Gr III (silymarin) was found, which may be due to decreased synthesis of protein in liver of rats due to long term treatment with CCl₄ (Patel *et al.*, 2010). Manjunatha *et al.* (2008) reported the decreased total protein levels in rats treated with CCl₄ @ 0.1 ml/kg i.p for 14 days, which supports our study.

The level of total bilirubin (0.38 ± 0.03) in Gr II was increased significantly ($P < 0.05$) as compared to healthy and other treatment groups. Total bilirubin is marker of hepatobiliary injury, especially cholestasis and biliary obstruction. Rao and Mishra (1997) reported increased level of total and direct bilirubin in acute hepatic injury due to CCl₄ toxicity which supports present findings. In this study, a decrease in hepatic tissue GSH levels were observed in the CCl₄ induced groups (Table 2). The level of lipid peroxide is a measure of membrane damage and alterations in structure and function of cellular membranes. In our study, elevation of lipid peroxidation in the liver of rats treated with CCl₄ was observed. Increase in malondialdehyde levels in liver suggests enhanced lipid peroxidation leading to tissue damage and

Table 1. Biochemical profile of rats serum receiving various treatments against CCl₄ induced hepatotoxicity (Mean ± SE)

Groups	I (Healthy control)	II (CCl ₄)	III (CCl ₄ +silymarin)	IV (CCl ₄ +Zn)	V (CCl ₄ +Se)	VI (CCl ₄ +Zn+Se)
ALT (IU/L)	41.9 ± 5.3 ^a	156.5 ± 20.1 ^b	68.49 ± 11.3 ^a	58.9 ± 1.9 ^a	60.34 ± 2.01 ^a	54.07 ± 3.2 ^a
AST (IU/L)	161.2 ± 16.2 ^a	338.5 ± 10.7 ^c	230.7 ± 35.6 ^b	194.7 ± 10.7 ^{ab}	185.1 ± 12.9 ^{ab}	179.1 ± 19.5 ^{ab}
ALP (IU/L)	165.4 ± 16.8 ^a	288.0 ± 10.9 ^b	203.8 ± 10.8 ^{ab}	183.9 ± 2.8 ^a	235.9 ± 18.8 ^{ab}	196.1 ± 5.8 ^{ab}
Total Protein (g/dl)	6.9 ± 1.1 ^d	4.4 ± 0.96 ^a	5.07 ± 0.9 ^{ab}	5.5 ± 0.12 ^{bc}	5.8 ± 0.17 ^{bc}	6.01 ± 0.5 ^{bc}
Albumin (g/dl)	4.5 ± 0.1 ^c	2.9 ± 0.14 ^a	3.2 ± 0.12 ^{ab}	3.5 ± 0.13 ^{bc}	3.9 ± 0.2 ^{cd}	3.8 ± 0.23 ^{cd}
Glucose (mg/dl)	63.8 ± 3.8 ^{abc}	120.6 ± 2.5 ^c	70.0 ± 7.4 ^{abcd}	44.3 ± 3.4 ^a	70.8 ± 9.4 ^{abcd}	52.2 ± 5 ^{ab}
Total Billirubin (mg/dl)	0.38 ± 0.03 ^a	0.55 ± 0.06 ^b	0.33 ± 0.07 ^a	0.31 ± 0.01 ^a	0.38 ± 0.04 ^{ab}	0.37 ± 0.02 ^a

Values bearing different superscripts in the same column differ significantly (p≤0.05)

Table 2. Oxidative stress indices in rat liver tissue receiving various treatment against CCl₄ induced hepatotoxicity (Mean ± SE)

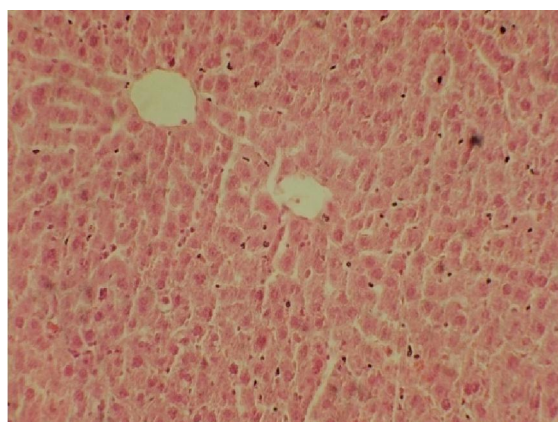
Groups	LPO (nmoles MDA/mg Protein)	SOD (U/mg Protein)	Catalase (U/mg Protein)	GSH (μmoles/ mg Protein)
I (Healthy control)	3.2 ± 0.15 ^a	3.2 ± 0.14 ^b	9.2 ± 0.3 ^{ef}	3.01 ± 0.2 ^c
II (CCl ₄)	8.9 ± 0.4 ^d	1.6 ± 0.2 ^a	4.7 ± 0.4 ^a	1.7 ± 0.12 ^a
III (CCl ₄ +silymarin)	5.1 ± 0.2 ^c	2.7 ± 0.1 ^b	6.7 ± 0.2 ^{bc}	2.5 ± 0.2 ^b
IV (CCl ₄ +Zn)	5 ± 0.12 ^c	2.8 ± 0.2 ^b	6.2 ± 0.12 ^b	2.7 ± 0.3 ^{bc}
V (CCl ₄ +Se)	4.8 ± 0.3 ^c	2.7 ± 0.14 ^b	7.1 ± 0.3 ^{bc}	2.8 ± 0.3 ^{bc}
VI (CCl ₄ +Zn+Se)	3.96 ± 0.2 ^b	2.96 ± 0.3 ^b	7.8 ± 0.2 ^{cd}	2.9 ± 0.14 ^c

Values bearing different superscripts in the same row differ significantly (P≤0.05)

failure of antioxidant defence mechanisms to prevent the formation of excessive free radicals (Shenoy *et al.*, 2001). These findings were in agreement with findings of Doi and co-workers (1991) where they found that rats given 2 ml CCl₄ with 2 ml olive oil per kg body weight orally produced hepatotoxicity and revealed increased LPO levels in liver of exposed rats. However, there was significant decrease in the values of LPO in all treatment groups as compared to Gr II which reveals hepatoprotective actions of all treatment regimens. LPO value of Gr VI (3.96±0.18) reduced significantly as compared to Gr IV and V which reveals better antiperoxidation action of Zinc and Selenium in combination as compared to their actions alone. Dhawan and Goel (1995) also revealed the synergistic action of zinc and selenium. Modi *et al.* (2006) found that zinc (5mg/kg, p.o) and N- acetylcysteine (10mg/kg i.p) prevented lead acetate induced lipid peroxidation. Similarly Tupe *et al.* (2010) found that zinc @ 30mg/kg in diet significantly protected against butyl hydroperoxide induced increased lipid peroxidation.

The level of SOD in Gr II decreased significantly as compared to all groups but there was no significant difference in all treated groups with the healthy control group revealing efficacy of antioxidants as an hepatoprotectant. Therapeutic regimen in Gr VI reflected increased SOD activity as compared to Gr IV and V revealing zinc and selenium in combination restored better SOD activity as compared to selenium and zinc alone. These findings on SOD were in agreement with findings of Jihen *et al.* (2009) who reported that zinc and selenium significantly improved SOD level in cadmium induced toxicity. Combined effect of zinc and selenium found to be much better than their individual effect on SOD because selenium and zinc are well known essential elements and cofactors of antioxidant enzyme such as copper, zinc – superoxide dismutase (CuZn SOD) which dismutates O₂ into H₂O₂ and selenoenzyme Glutathione peroxidase, which catalyzes H₂O₂ into H₂O. Zinc significantly improved SOD level, metallothionein and GSH level in oxidative stress of liver (Cabre *et al.*, 2001). The level of GSH decreased

significantly in Gr II as compared to all other groups. The level of GSH increased significantly in all treatment groups as compared to Gr II which reveals its antioxidant potential. GSH level of Gr VI (2.9±0.14) restored well as compared to Gr IV (2.7±0.3) and GR V (2.8±0.3). Zinc and selenium are believed to interact with GSH affecting its antioxidant activity. The levels of GSH were also found to be correlated well with dietary zinc status (Oztuk *et al.*, 2003). The level of catalase decreased significantly in Gr II in comparison to all other groups. The catalase value was best restored in Gr VI as compared to Gr IV and V which again reveals better antioxidant potential of zinc and selenium in combination. These findings were similar with the findings of Jihen *et al.*, (2009) who reported that selenium and zinc when given in drinking water for 35 days significantly improved catalase activity in liver. Histopathological appearance of liver of rats in Gr I were normal with no specific pathological changes and had a grade 0 by histopathological scoring system (HPS) (Fig.1).

**Fig. 1. Histopathological appearance of liver of rats**

The cords of hepatocytes were well preserved, cytoplasm was vacuolated, and sinusoids well demarcated. Chandan *et al.* (2008) and Rai *et al.* (2001) reported the same observations in

mice and rat liver respectively. Hepatocytes of Gr II revealed severe fatty changes and necrosis associated with fibrosis. It was characterized by cytoplasmic vacuolations of variable sizes putting the nucleus to adjacent areas. Liver tissues revealed grade 3 by HPS (Fig.2).

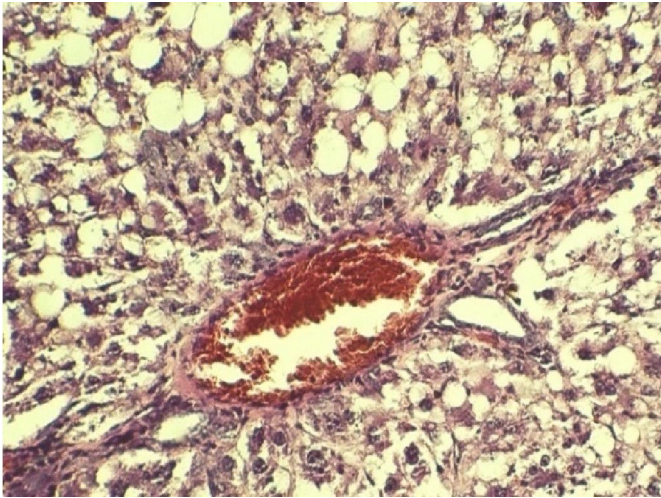


Fig. 2. Liver tissues revealed grade 3 by HPS

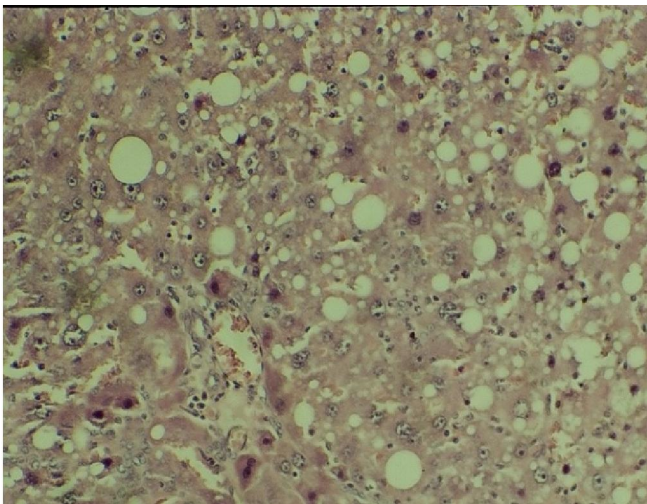


Fig. 3. moderate fatty changes and mild infiltration of inflammatory cells with HPS score of 2

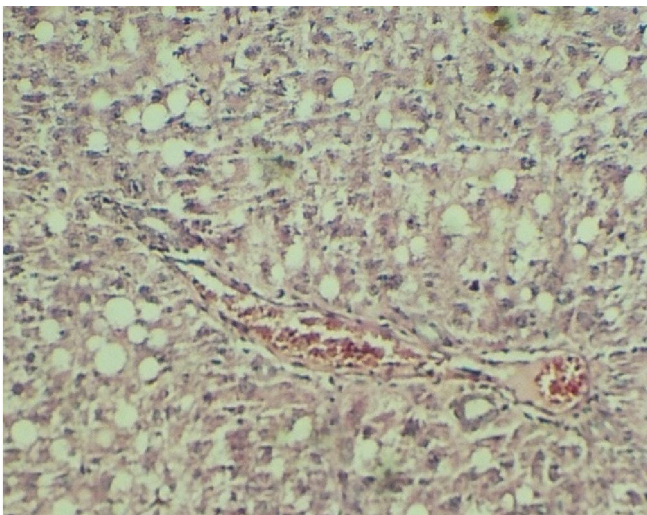


Fig. 4. mild to moderate degree fatty changes with mild infiltration of inflammatory cells

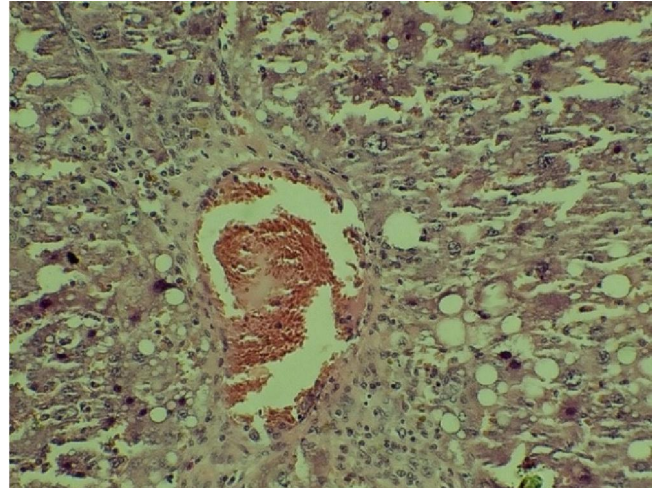


Fig. 5. mild to moderate degree fatty changes with mild infiltration of inflammatory cells

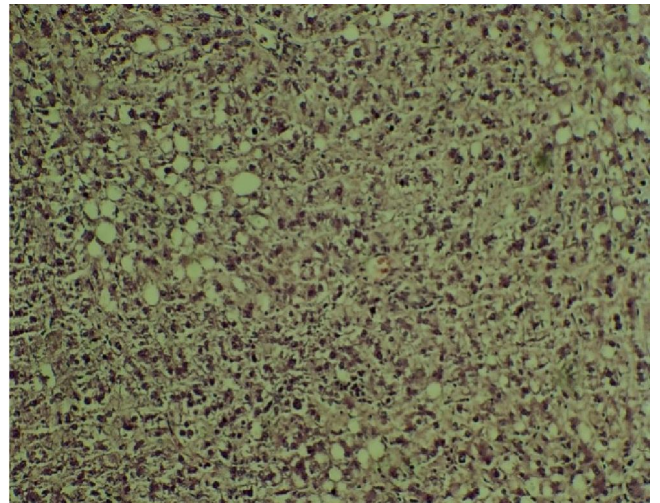


Fig. 6. mild degree fatty changes with mild fibrous tissue proliferation between lobules

Figures. Histopathology (Light micrographs) of livers of Group I,II,III,IV,V and VI. (HE x 400)

The Doi *et al.* (1991) has postulated post necrotic fibrosis in rats on the 4th week itself treated by CCl₄ along with olive oil (1:1; v/v) @ 4ml/kg.b.wt orally twice a week for 12 weeks which were in concurrent with present findings. The treatment groups depicted mild to moderate fatty changes as compared to Gr II with formation of fibrous septa and infiltration of inflammatory cells in-between hepatic cords suggesting capabilities of the treatment groups to regenerate damaged liver. Silymarin treated group (Gr III) showed moderate fatty changes and mild infiltration of inflammatory cells with HPS score of 2 (Fig.3). In Gr IV (Fig. 4) and V (Fig.5) hepatocyte showed mild to moderate degree fatty changes with mild infiltration of inflammatory cells. There was moderate proliferation of connective tissue around portal triad and extending to periphery to form pseudolobuli. Liver tissues revealed grade 1-2 by HPS. Histopathology of Gr VI (Fig.6) showed mild degree fatty changes with mild fibrous tissue

proliferation between lobules. Liver tissues revealed grade 1 by HPS. The above findings also showed better hepatoprotective potential of zinc and selenium in combination as compared to their actions alone. In conclusion, co-administration of Zinc and Selenium as antioxidant had better synergistic hepatoprotective action in CCl₄ induced hepatotoxicity in rats.

REFERENCES

- Burk, R. F. and Hill, K. E. 1993. Regulation of selenoproteins. *Ann. Rev. Nutr.*, 13:65-81.
- Chandan, B.K., Saxena, A.K., Shukla, S., Sharma, N., Gupta, D.K., Singh, K., Suri, J., Bhadauria, M. and Qazi, G.N. 2008. Hepatoprotective activity of *Woodfordia fruticosa* flowers against carbon tetrachloride induced hepatotoxicity. *J. Ethnopharmacol.*, 119(2): 218-224.
- Cabre, M., Camps, J., Ferre, N., Paternain, J. L. and Joven, J. 2001. The antioxidant and hepatoprotective effect of zinc are related to hepatic cytochrome P450 depression and metallothionein induction in rats with experimental cirrhosis. *Int. J. Vita. Nutr. Res.*, 71:229-236.
- Cohen, G., Dembiec, D. and Marcus, J. 1970. Measurement of catalase activity in tissues extracts. *Anal. Biochem.*, 34, 30-38.
- Culling, C. F. A. 1963. Handbook of histopathological techniques (including museum techniques). 2nd edition. Butterworth. London. pp 230-248.
- Dhawan, D. and Goel, A. 1995. Further evidence for zinc as a hepatoprotective agent in rat liver toxicity. *Exp. and Mol. Pathol.*, 63: 110-117.
- Doi, K., Kurabe, S., Shimazu, N. and Inagaki M. 1991. Systemic histopathology of rats with CCl₄ induced hepatic cirrhosis. *Lab. Ani.*, 25: 21-25.
- Fariss, M. W., Chan, C. B., Patel, M., Van Houten, B. and Orrenius, S. 2005. Role of mitochondria in toxic oxidative stress. *Mol. Interv.*, 5:94-111.
- Jihen, E. H., Imed, M., Fatima, H. and Abdel-hamid, K. 2009. Preventive effect of selenium (Se) and zinc (Zn) on cadmium (Cd) toxicity in the liver of the rat: Effects on oxidative stress. *Eco. Environ. Safety*, 72:1559-1564.
- Kaplan, L. A. 1984. Carbohydrate and metabolites in clinical chemistry: Theory, analysis and correlation. Kaplan, L. A. and Pesce, A. J., Eds. C. B. Mosby Toronto pp 1032-1040.
- Manjunatha, B. K. and Vidya, S. M. (2008). Hepatoprotective activity of *Vitex trifolia* against carbon tetrachloride induced hepatic damage. *Ind. J. Pharm. Sci.*, 70(2):241-5.
- Marklund, S. and Marklund, G. 1974. Involvement of superoxide anion radical in the auto-oxidation of pyrogallol and a convenient assay for superoxide dismutase. *Biochem. J.*, 47:469-474.
- Modi, M., Kaul, R. K., Kanran, G. M. and Flora, S. J. S. 2006. Co-administration of zinc and n-acetyl cysteine prevents arsenic induced tissue oxidative stress in male rats. *J. Trace Ele. Med. Bio.* 20:197-204.
- Muriel, P. and Escobar, Y. 2003. Kupffer cells are responsible for liver cirrhosis induced by carbon tetrachloride. *J. App. Toxicol.*, 23(2):103-108.
- Ohkawa, H., Ohishi, N. and Yagi, K. 1979. Assays of peroxides in animal tissues by thiobarbituric acid reaction. *Analytical Biochem.*, 95:351-358.
- Ohta, Y., Imai, Y., Matsura, T., Kitagawa, A. and Yamada, K. 2006. Preventive effect of neutropenia on carbontetrachloride induced hepatotoxicity in rats. *J. of Appl. Tech.*, 26: 178-186.
- Ozturk, A., Baltaci, A. K., Mogulkoc, R., Oztekin, E., Sivrikaya, A., Kurtoglu, E., Kul, A., 2003. Effects of zinc deficiency and supplementation on malondialdehyde and glutathione levels in blood and tissues of rats performing swimming exercise. *Biol. Trace Elem. Res.*, 94: 157-166.
- Paduraru, I., Saramet, A., Danila, G. H., Nichifor, M., Jerca, L. and Iacobovici. A. 1996. Antioxidant action of a new flavonic derivative in acute carbon tetrachloride intoxication. *Eur. J. Drug Metab. Pharmacokinet.*, 21 : 1-6.
- Patel, N., Joseph, C., Corcoran, G. B. and Ray, S. D. 2010. Silymarin modulates doxorubicin induced oxidative stress, Bcl-xL and p53 expression while preventing apoptotic and necrotic cell death in the liver. *Toxicol. Appl. Pharma.*, 245:143-152.
- Rai, M., Pai Mirabel, R. S. M., Sabitha, P. and Pai, P. 2001. Hepatoprotective influence of selenium in experimental liver cirrhosis. *Kuwait Med. J.*, 33(4):333-336.
- Rao, K. S. and Mishra, S. H. 1997. Anti-inflammatory and hepatoprotective activities of *Sida rhombifolia* Linn. *Ind. J. Pharma.*, 29:110-116.
- Reitman, S. and Frankel, S. 1957. Calorimetric determination of serum glutamic oxalacetic transaminase and serum glutamic pyruvic transaminase. *Am. J. Clin. Pathol.*, 28: 56-63.
- Sedlak, J. and Lindsay, R. H. 1968. Estimation of total, protein bound and non-protein sulfhydryl groups in tissues with Ellman's reagent. *Anal. Biochem.*, 25(1):192-205.
- Shenoy, K.A., Somayaji, S. N. and Bairy, K. L. 2001. Hepatoprotective effects of Ginkgo biloba against carbon tetrachloride induced hepatic injury in rats. *Ind. J. Pharmacol.*, 33:260-266.
- Snedecor, G.W. and Cochran, W.G. 1994. Statistical methods, 8th edn. Iowa state university press, USA.
- Tamburro, C. H. 1979. Chemical hepatitis: pathogenesis, detection and management. *Med. Clin. North Am.*, 63: 545-566.
- Tupe, R. S., Tupe, S. G., Tarwadi, K. V. and Agte, V. V. 2010. Effect of different dietary zinc levels on hepatic antioxidant and micronutrients indices under oxidative stress conditions. *Metbol.*, 59 (11):1603-1611.
- Verley, H., 1980. Practical clinical biochemistry, 5th edition, William Heinemann publisher, London, pp 550-555.
- Wolf, P. L. 1999. Biochemical diagnosis of liver diseases. *Ind. J. Clin. Biochem.*, 14:59-65.
- Zilva, J.F. and Pannall, P.R. 1979. Clinical chemistry in diagnosis and treatment. 4th Edn., Lloyd-Luke, London, UK. pp: 348-352.
- Zimmerman, H. J. 1999. Drug-induced liver disease, in: Schiff, E. R., Sorrell, M. F., Maddrey, W. C. (Eds.). Schiff's Diseases of the Liver, eighth ed. Lippincott-Raven, Philadelphia, pp. 973-1064.
