



ISSN: 0975-833X

CASE STUDY

AN ATYPICAL PRESENTATION OF PROLIFERATING TRICHILEMMAL TUMOUR OF THE SCALP

*Sharma Vinaysagar, Ananth G, Jagannath P. M., Varadaraju D. N., Shashwath Kumar and Kishan Anantha

Department of Neurosurgery, Vydehi Institute of Medical Sciences and Research Centre, Bangalore, India

ARTICLE INFO

Article History:

Received 05th March, 2015
Received in revised form
07th April, 2015
Accepted 19th May, 2015
Published online 27th June, 2015

Key words:

Proliferating trichilemmal tumour,
Hair follicle, Calvarium,
Superior sagittal sinus.

ABSTRACT

The proliferating trichilemmal tumor is an uncommon neoplasm presenting as a solitary lesion over the scalp. It is usually a benign neoplasm. We describe a case of proliferating trichilemmal tumor which presented as an ulcerated solid swelling of the scalp over the vertex, with bony erosion reaching the superior sagittal sinus.

Copyright © Sharma Vinaysagar et al. This is an open access article distributed under the Creative Commons Attribution License, which permits unrestricted use, distribution, and reproduction in any medium, provided the original work is properly cited.

Citation: Sharma Vinaysagar, Ananth G, Jagannath P. M., Varadaraju D. N., Shashwath Kumar and Kishan Anantha. "An atypical presentation of proliferating Trichilemmal tumour of the scalp", *International Journal of Current Research*, 7, (6), 16894-16897.

INTRODUCTION

The proliferating trichilemmal tumor (trichilemmal cyst /pillar cyst) is an uncommon neoplasm derived from the outer sheath of the hair follicle. It is usually a solitary lesion, mostly benign and seen particularly in elderly women. It is located in areas of dense hair follicular concentrations such as the scalp. It presents as a subcutaneous cystic nodule for many years, often increasing with a history of trauma or chronic inflammation. (Makiese *et al.*, 2010) It may present as a locally aggressive lesion but intracranial extension is a very rare presentation. (Folpe *et al.*, 2003) We present an interesting case that had history of spontaneous rupture followed by discharge mimicking an infected sebaceous cyst and erosion of underlying calvarium.

Case History

A sixty five years old male patient presented with a progressively increasing scalp swelling over the vertex since eighteen years. The swelling was about 7x5x3 centimeters in size. Two weeks prior to presentation it had a spontaneous rupture followed by ulceration and purulent discharge.

The two ulcers each about 3x3 centimeters in size had sloping edges with a floor covered with slough and purulent discharge. The swelling was solid in consistency, non fluctuant and adherent to underlying skull bone. The surrounding skin appeared to be normal (Figure 1).

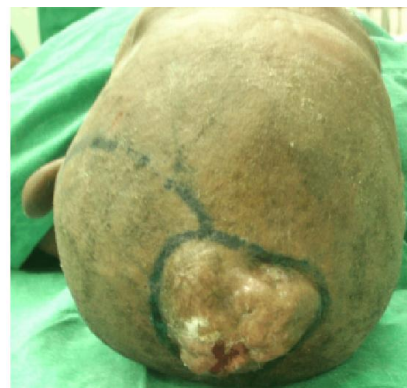

Fig. 1. Clinical photograph of the lesion with marking of the flap

Edge biopsies were taken to rule out malignancy and revealed only hypertrophic epithelialisation.

A contrast enhancing computerized tomography scan of head with bone windows revealed erosion of bone underlying the

*Corresponding author: Sharma Vinaysagar,
Department of Neurosurgery, Vydehi Institute of Medical Sciences and
Research Centre, Bangalore, India.

swelling reaching the superior sagittal sinus. Magnetic resonance imaging (MRI) of the brain showed lesion sitting on the superior sagittal sinus (Figure 2), however, MR venogram of the brain excluded involvement of superior sagittal sinus. (Figure 3)

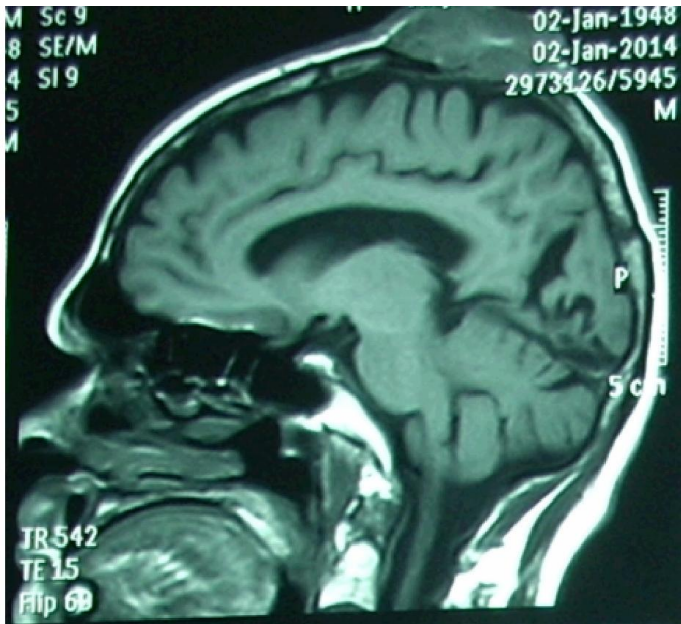


Fig. 1. Clinical photograph of the lesion with marking of the flap

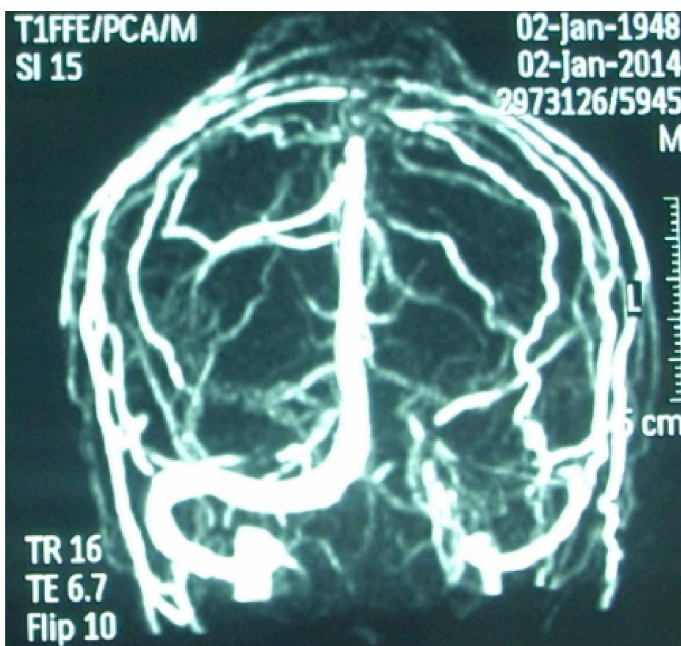


Fig. 3. MR venography showing compressed superior sagittal sinus

A diagnosis of a chronic inflammatory lesion or an indolent neoplasm was considered. Surgery was planned and excision of the swelling was performed. Intra-operatively, the swelling was seen sitting on duramater forming the roof of superior sagittal sinus with a clear plane separating the both (Figure 4). The defect was covered with a rotation flap marked preoperatively.

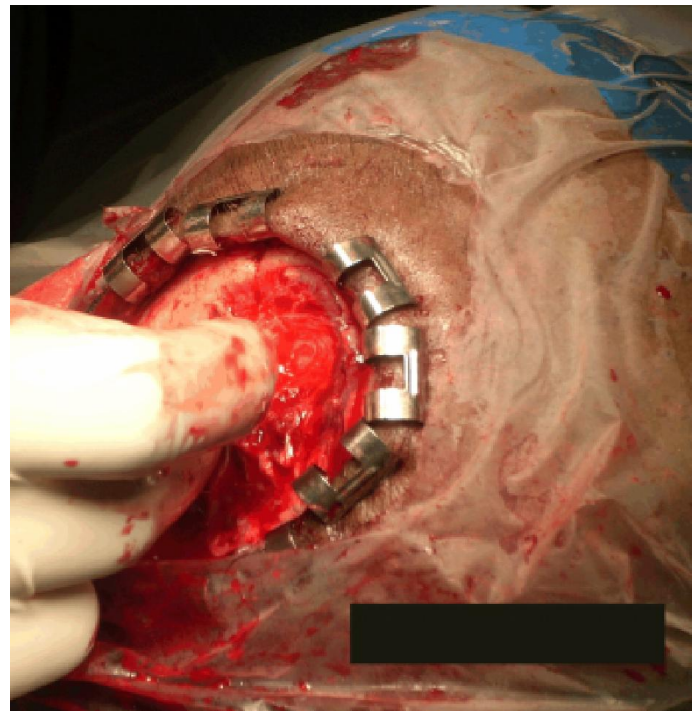


Fig. 4. Intraoperative photograph showing intact dura after excision of the lesion

Histopathological evaluation revealed nests of squamous cells in the dermis separated by fibrous tissue and hyperkeratosis with no features of anaplasia and it was inferred as a proliferating trichilemmal tumour (Figure 5 and 6). Postoperatively scalp flap had taken well. Patient was discharged and followed up after 3 & 6 months with a healthy scalp. (Figure 7)

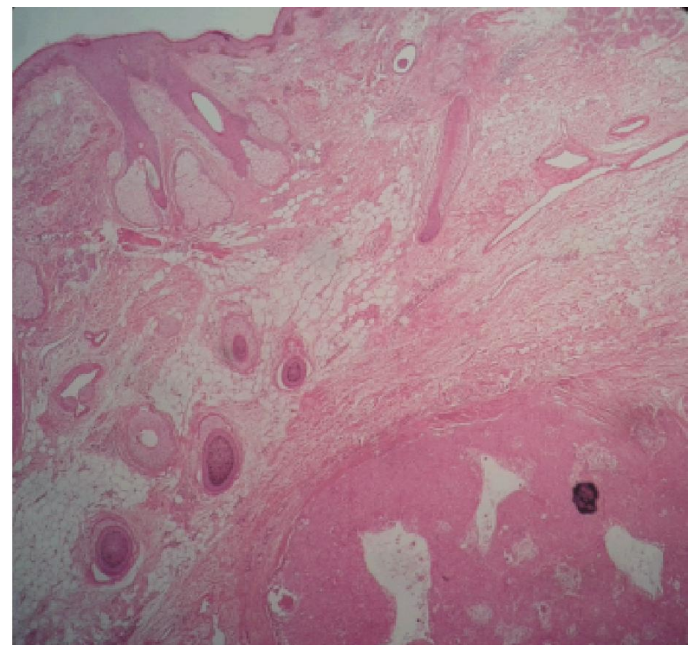


Fig. 4. Intraoperative photograph showing intact dura after excision of the lesion

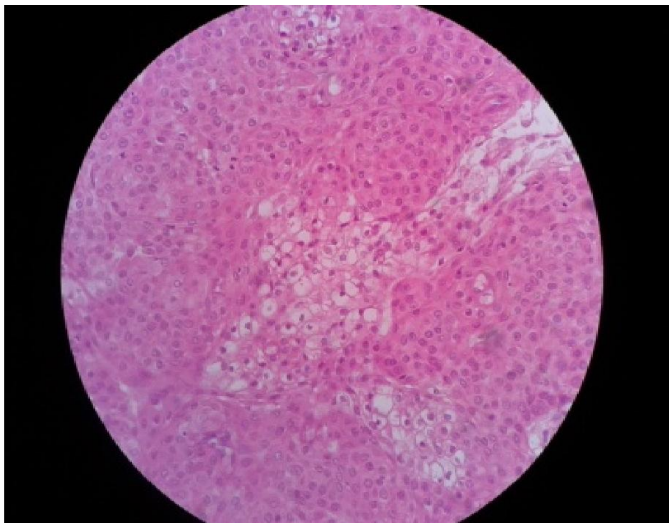


Fig. 6. Microscopic picture under 40x magnification with hematoxylin and eosin staining showing interlacing bundles of squamous epithelium and trichilemmal type of keratinization

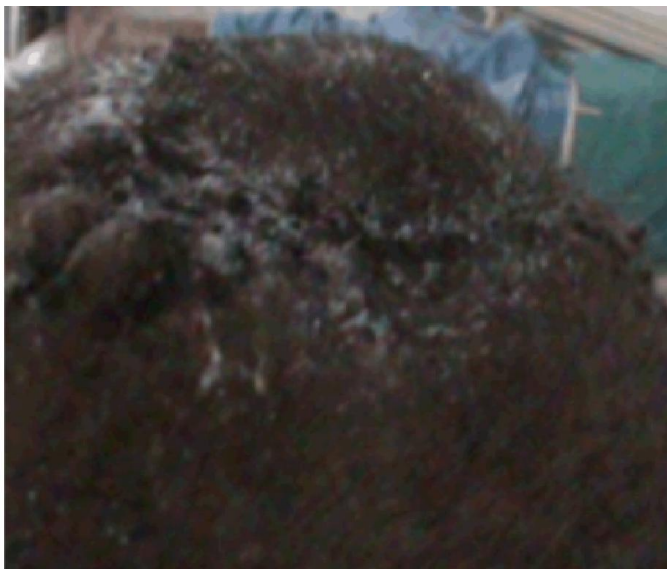

Fig. 7. Healed flap at a follow-up visit

DISCUSSION

The proliferating trichilemmal tumour, which is also termed as proliferative trichilemmal cyst or pilar cyst, is an uncommon, mostly a benign neoplasm derived from the outer sheath of the hair follicle. (Makiese *et al.*, 2010; Jones, 1966) The presentation is mostly as an solitary lesion but it can also present as multiple lesions. An autosomal dominant pattern has been observed in cases of multiple lesions. (Erdem *et al.*, 2011) It has been observed that the location of these tumors in 90 percent of the affected individuals, are the areas of dense hair follicular concentrations such as the scalp. (Makiese *et al.*, 2010) This tumor clinically resembles a keratinous or sebaceous cyst, and usually occurs on or close to the scalp of elderly women. (Jones, 1966; Satyaprakash *et al.*, 2007; Saida *et al.*, 1983; Lee *et al.*, 1989) Most of the cases have an history of slowly enlarging nodular mass over a span of years which is often an exacerbation after a event of trauma or chronic

inflammation. (Makiese *et al.*, 2010) It was Wilson-Jones in 1966 who gave a first description of an proliferating epidermoid cyst which potentiated histologically to simulate squamous cell carcinoma. (Jones, 1966; Ogul *et al.*, 2014; Kumar *et al.*, 2000)

Proliferating trichilemmal tumour (PTT) has characteristics of an typical pilar cyst, and additionally features extensive epithelial proliferation, variable cytological atypia and mitotic activity. (Saida *et al.*, 1983) Although PTT is considered as biologically benign neoplasm, local aggressiveness (Jones, 1966) and its potentiality for malignant transformation cannot be overlooked. (Lee *et al.*, 1989) There are three main varieties described under PTT: benign, locally aggressive, and malignant.⁸ Malignant transformation has been witnessed with regional or distant metastases. However, there have been a very few numbers of malignant PTTs being reported. (Makiese *et al.*, 2010; Jones, 1966) The combination of the non-scalp location, recent rapid growth, size greater than 5 cm, infiltrative growth, and significant cytological atypia with mitotic activity forms a diagnostic hallmark for malignant PTT. (Saida *et al.*, 1983) PTT may exhibit aggressive local invasion across tissue planes and may even extend intracranially and may cause considerable morbidity and even mortality. (Makiese *et al.*, 2010; Ogul *et al.*, 2014)

Only few cases of proliferating trichilemmal tumours with cerebral involvement have been described in the literature. (Folpe *et al.*, 2003; Karamese *et al.*, 2012)

A multidisciplinary team which should include a neuro-radiologist, neurosurgeon, plastic surgeon, pathologist and neuro-oncologist gives overall a better outcome, as the surgical management is a demanding task in these patients (Makiese *et al.*, 2010). These tumors are known to recur with a conservative local excision. Thus, complete surgical excision is recommended in these cases. Lesions which have an increased invasive potential, should be planned for adjuvant radiotherapy and/or chemotherapy. (Lee *et al.*, 1989) Ultimately, surgical excision has to be done adequately. In view of very few cases being reported, alternate therapies cannot be judged safely. (Jones, 1966) Recurrences or metastases in cases of malignant PTTs can be detected by a close clinical follow-up. (Makiese *et al.*, 2010; Jones, 1966; Lee *et al.*, 1989)

Conclusion

Proliferating Trichilemmal tumors could appear clinically as malignant lesions and careful clinical and histopathological discretion is essential when considering malignancies over the scalp. They may present with features of idiopathic spontaneous rupture and subsequent discharge and aggressive neoplasm leading to bony erosion as in our case. With better histopathological interpretation more number of cases can be diagnosed. In view of an unknown clinical behavior, it is wise to not neglect this entity as malignant change has been reported in quite a few cases. Active treatment at the earliest will yield a better result.

What is new: Proliferating trichilemmal tumors may mimic malignancy. Sometimes the tumor may erode the calvarium as

in our case. This complicates management requiring a multidisciplinary approach.

REFERENCES

- Erdem H, Yildirim U, Uzunlar AK, Sahiner C, Ozcelik D, Toplu G. Posttraumatic giant proliferating trichilemmal cysta on the parietal region of the scalp. *Indian J Dermatol Venereol Leprol.*, 2011;77:707-709
- Folpe AL, Amy KR, Mentzel T, Rütten A and Solomon AR. Proliferating trichilemmal tumors: Clinicopathologic evaluation is a guide to biologic behaviour. *J Cutan Pathol.*, 2003;30:492–498.
- Jones E. Proliferating epidermoid cysts. *Arch Dermatol.*, 1966; 94:11–19.
- Karamese M., A. Akatekin, M. Abaci, Z. Tosun and M. Keskin, "Unusual Invasion of Trichilemmal Tumors: Two Case Reports," *Modern Plastic Surgery*, Vol. 2 No. 3, 2012, pp. 54-57. doi: 10.4236/mps.2012.23014.
- Kumar P, Chatura K R, Haravi RM, Chandra. Proliferating Trichilemmal Cyst mimicking squamous cell carcinoma. *Indian J Dermatol Venereol Leprol* 2000; 66: 149-150
- Lee JY, Tang CK and Leung YS. Clear cell carcinoma of the skin: a trichilemmal carcinoma? *J Cutan Pathol.*, 1989; 16:31–39.
- Makiese O, Chibbaro S, Hamdi S, Mirone G and George B. Huge proliferating trichilemmal tumours of the scalp: Report of six cases. *Plast Reconstr Surg.*, 2010;126:18-19.
- Ogul H, Keles S, Yildirim K, Bassorgun CI, Eren S and Kantarci M. Orbital malignant trichilemmal tumor with cerebral involvement. *J Craniofac Surg.*, 2014; 25:21-23.
- Saida T, Oohara K, Hori Y and Tshuya S. Development of a malignant proliferating trichilemmal cysts. *Dermatologica*, 1983; 166:203-208.
- Satyaprakash AK, Sheehan DJ and Sanguenza OP. Proliferating trichilemmal tumors: a review of literature. *Dermatol Surg.*, 2007; 33:1102–1108.
