



ISSN: 0975-833X

Available online at <http://www.journalcra.com>

INTERNATIONAL JOURNAL
OF CURRENT RESEARCH

International Journal of Current Research
Vol. 14, Issue, 02, pp.20626-20630, February, 2022

DOI: <https://doi.org/10.24941/ijcr.43064.02.2022>

RESEARCH ARTICLE

FIRST MANIC EPISODE AFTER COVID-19 INFECTION: CASE SERIES

Thiago N. ROCHA^{1, 2 *}, Jéssyca R. e SILVA², Marcelo H. de S. e S. MARTINS², Thiago BLANCO-VIEIRA³ and Sérgio C. FILHO²

¹Emergency, Department of Emergency, Hospital São Vicente de Paulo, Brasilia, Brazil

²Psychiatry, Department of Psychiatry, Hospital de Base, Brasilia, Brazil

³Psychiatry, Department of Psychiatry, Escola Superior de Ciências da Saúde, Brasilia, Brazil

ARTICLE INFO

Article History:

Received 24th November, 2021

Received in revised form

19th December, 2021

Accepted 20th January, 2022

Published online 25th February, 2022

Keywords:

Bipolar Disorder,
COVID-19, Mania.

*Corresponding author:

Thiago N. ROCHA

ABSTRACT

Background: In January 2020, the World Health Organization declared the Severe Acute Respiratory Syndrome Coronavirus 2 to be a pandemic. Since then, studies have demonstrated the potential of this virus to cause changes in the central nervous system and psychiatric symptoms. Some reports associating the Severe Acute Respiratory Syndrome Coronavirus 2 infection and manic symptoms have been published. **Objective:** Present the characteristics of manic syndrome after the Severe Acute Respiratory Syndrome Coronavirus 2 infection and provide ways to better prevent risks and identify this syndrome. **Methods:** Data from multiple sources of information, including reviews of medical records, direct examinations of the subjects and interviews with patients and their families, were collected and analyzed. **Results:** Six cases of Covid-19 infection with a first manic episode and no previous psychiatric history were reported. **Conclusion:** The findings of this study suggest that for mild symptomatic cases, the use of corticosteroids should be disregarded due to the risk of inducing a manic episode. The use of anticoagulation in severe conditions is reinforced by the finding of microlesions of probable microvascular etiology in one of the patients. All patients in the study had psychotic symptoms with symptom onset within the first 30 days of infection.

Copyright © 2022. Thiago N. ROCHA et al. This is an open access article distributed under the Creative Commons Attribution License, which permits unrestricted use, distribution, and reproduction in any medium, provided the original work is properly cited.

Citation: Thiago N. ROCHA, Jéssyca R. e SILVA, Marcelo H. de S. e S. MARTINS, Thiago BLANCO-VIEIRA, Sérgio C. FILHO. "First manic episode after covid-19 infection: case series", 2022. *International Journal of Current Research*, 14, (02), 20626-20630.

INTRODUCTION

In January 2020, the World Health Organization declared the Severe Acute Respiratory Syndrome Coronavirus 2 (SARS-CoV-2) to be a pandemic, stating to the world that the virus was a serious public health problem and an international emergency (World Health Organization, 2005). Since then, new publications on the virus have revealed the effects of this virus on the central nervous system (Iadecola, 2002; Song, 2021). There is the potential for microstructural changes identified by nuclear magnetic resonance, such as an increased olfactory cortex, hippocampus, insulas, Heschl's gyrus, rolandic operculum and cingulate gyrus; and a general decline in mean, axial and radial diffusivity accompanied by a fractional increase in white matter anisotropy (Lu et al., 2020). In a cohort of 236,379 patients diagnosed with Covid-19, a 33.63% incidence of neurological and psychiatric diagnoses within six months of infection was estimated, and 12.84% of these cases were the first time the patients received such a diagnosis. Among the most incident psychiatric diagnoses, anxiety disorder was found in 17.39% of patients,

and psychotic disorder was found in 1.40% of patients (Taquet et al., 2021). The first publication describing manic episode symptoms was by S. Lu et al. (2020). In this case report, the authors stated that there was a brief therapeutic response, but there was still a lack of information about the prognosis. A manic episode is a mood state with the potential for very significant harm to patients (Velosa et al., 2020). Inflated self-esteem associated with a reduction in the need for sleep, psychomotor agitation and excessive involvement in activities with a high potential for serious consequences implies a critical condition for the patient and society, given that the fulfillment of usual control strategies such as social distancing and isolation were frankly committed (American Psychiatric Association, 2013). Psychiatric complications and sequelae have been reported; however, more data are needed to better understand the effects of Covid-19 on mental health. This series of cases presents characteristics of manic syndrome after SARS-CoV-2 infection, a complication that is still poorly described; and provides ways to better prevent risks and identify this syndrome. This study also assesses the potential mechanisms of the development of psychiatric disorders by

correlating the available data on this complication with the findings on Covid-19 described in the literature.

MATERIALS AND METHODS

Ethical Considerations: This study was approved by the Ethics Committee of the Federal District Institute for Strategic Health Management, according to protocol n° 43227721.1.0000.8153. Patient data was collected and analyzed with the consent and authorization of the patient or their legal guardian by signing an informed consent form.

Data collect: The study subjects were evaluated at specialized mental health care services and at two public hospitals in the Federal District. Multiple sources of information were used to describe the cases, including reviews of medical records, direct examinations of the subjects during hospitalization and interviews with patients and their families.

RESULTS

Case 1: A 50-year-old female patient with a diagnosis of Covid-19 confirmed by a test of SARS-CoV-2 Ribonucleic acid (RNA) in material from the nasopharynx sought care at a psychiatric emergency unit 17 days after the onset of respiratory symptoms. At the time, the patient had accelerated thinking, high speech, irritable mood, religious delusions, psychomotor agitation and insomnia. She claimed that she was living the supernatural, that she heard the voice of God, and that she had defeated the Devil with his help. The patient did not use continuous medications and had no history of drug use or previous psychiatric illness. Furthermore, the patient had no psychiatric history in first- or second-degree relatives. She underwent cranial computed tomography and had no abnormal findings. Treatment with risperidone with an increase in the dose up to three milligrams (mg) per day after three days and sodium valproate with an increase in the dose up to 2,500 mg per day after 14 days was maintained during her hospital stay. Serum sodium valproate dosage was not performed. She was diagnosed with diabetes mellitus during her hospital stay. She was hospitalized for 19 days and was discharged after controlling her manic symptoms and requesting she maintain outpatient follow-up. A cerebrospinal fluid (CSF) lumbar puncture was not performed.

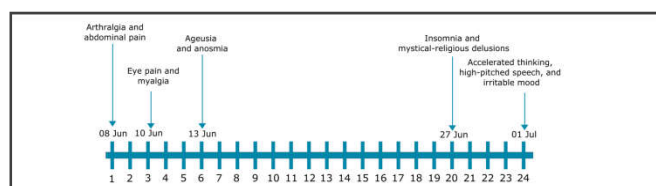


Figure 1. Evolution of symptoms in case 1.

Case 2

Case 2 was a 22-year-old female patient with coronavirus infection confirmed by testing for SARS-CoV-2 RNA in the nasopharynx. Due to respiratory symptoms, she was medicated with azithromycin, dexamethasone, ivermectin and dipyrrone. The corticosteroid dose used was equivalent to approximately 40 mg of prednisone per day for 5 to 7 days.

Seven days after the onset of respiratory symptoms, she sought care at the psychiatric emergency service with manifestations of insomnia, agitation, an uninhibited attitude and mystical-religious delusions. Family members reported that on the fifth day of infection, the patient began to change her behavior, saying that she understood everything, crying and hugging people. This evolved into insomnia and restlessness at night. The patient claimed that she was no longer “flesh” and only spirit. She said that Satan was in her clothes and that she had a mission to help everyone. The patient does not have a history of psychoactive drug use or a previous psychiatric history. She reported that her maternal grandmother and paternal grandfather were treated for depression. She used 0.15 milligrams of desogestrel and 0.03 milligrams of ethinylestradiol continuously as a contraceptive method. She was prescribed 750 mg of valproic acid daily and 25 mg of quetiapine in the evening. There was no need for hospitalization or maintenance of outpatient follow-up. Imaging exams and a CSF lumbar puncture were not performed.

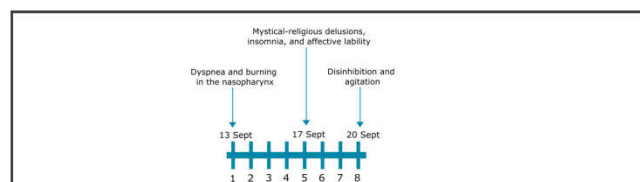


Figure 2. Evolution of symptoms in case 2

Case 3

A 36-year-old female patient was clinically diagnosed with Covid-19 due to characteristic respiratory symptoms. She was medicated with dipyrrone, azithromycin, dexamethasone and ivermectin. The dose of corticosteroid used was equivalent to approximately 40 mg of prednisone per day for five days.

Within 24 days of infection, she had insomnia. Over the next five days, agitation, tachylalia, cleansing and mystic-religious delusions arose. She sought care at a general hospital and was referred to a psychiatric unit. While there, she presented circumstantial, arboriform speech; hypervigilance; hypotenacity; accelerated thinking and mystic-religious delusions. She said that one of the patients at the hospital was her father who died when she was five years old. She believed that she was pregnant and that the reason for being in the hospital was to give birth. She did not have a history of psychoactive drug use or previous psychiatric disorder. She reported that her mother already experienced an episode of behavior change requiring the use of risperidone, and one brother and three sisters had a diagnosis of depression. A pregnancy test was performed with a positive result. A transvaginal ultrasound was performed; and a myoma was observed, ruling out pregnancy. The use of oral contraceptives was indicated.

She remained in the hospital for three days using 300 mg of chlorpromazine per day and 500 mg of valproic acid per day. Her symptoms improved and evolved with excessive sleepiness. During outpatient follow-up, it was decided to change the medication to 600 mg of lithium carbonate per day and two mg of risperidone per day, which maintained good control of her symptoms. A peripheral blood serological test for Covid-19 was performed with a positive result for

immunoglobulin G. No imaging tests or a CSF lumbar puncture were performed.

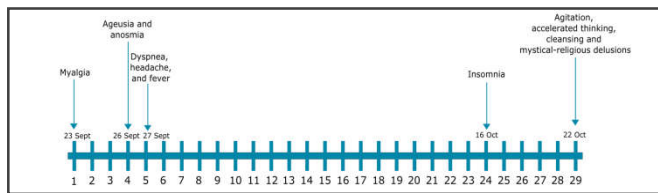


Figure 3. Evolution of symptoms in case 3

Case 4

The patient in case 4 was 55-year-old female with a diagnosis of Covid-19 confirmed by testing for SARS-CoV-2 RNA in nasopharyngeal material. Due to respiratory symptoms, she was medicated with azithromycin, vitamin C and dexchlorpheniramine.

Eleven days after the onset of her respiratory symptoms, she presented a reduced need for sleep and an increase in energy directed toward housework. She reported that for approximately two weeks, she went to sleep at 2 am and woke up at 5 am, cleaned her house several times and finished cooking lunch at 8 am. After 24 days of infection, she presented affective lability with episodes of crying and screaming, accelerated thinking and persistent monosyllabic speech. In the two days that followed, she experienced worsened insomnia and reporting having not slept for 48 hours.

After 26 days of infection, she sought psychiatric emergency care due to the persistence of symptoms. During treatment, 5 mg of haloperidol and 50 mg of promethazine were administered intramuscularly due to agitation. She was diagnosed with manic syndrome and prescribed 5 mg of haloperidol and 25 mg of promethazine per day orally. The patient experienced improved symptoms during the following week. The patient did not use continuous medications and had no history of psychoactive substance use or previous psychiatric illness. There was no history of psychiatric illness in first- or second-degree relatives. Imaging exams and a CSF lumbar puncture were not performed.

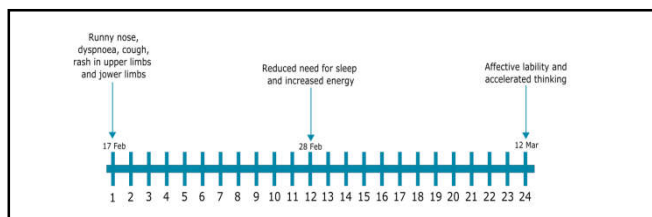


Figure 4. Evolution of symptoms in case 4

Case 5

Case 5 was a 57-year-old female patient with coronavirus infection confirmed by testing for SARS-CoV-2 RNA in the nasopharynx. Due to her infectious symptoms, she was medicated with azithromycin and ivermectin. She was hospitalized for treatment of pneumonia caused by Covid-19 and was treated with oxygen in a nonbreathing mask, ceftriaxone, piperacillin, tazobactam, enoxaparin and dexamethasone. She received a dose of corticosteroids equivalent to approximately 40 mg of prednisone a day for 10

days. She was diagnosed with diabetes mellitus during hospitalization. After 15 days of hospitalization, she was discharged from the hospital.

Family members reported that when the patient arrived home, she had affective lability. After five days, paranoid delusions, insomnia, increased energy and irritable moods began. She started to eat only the food she made, said that the food was contaminated and took pictures of various objects around the house claiming to be writing a book. After three days, she experienced mystical-religious delusions, aggressiveness and fast-paced and disjointed thinking. She placed various religious objects on her bed and wrote the names of spirits on the sheets. She threw clothes in the trash and ripped dresses. The next day, they sought care in a psychiatric emergency center.

The patient had to be taken to the psychiatric emergency room on a stretcher due to agitation. She spoke in a high tone, was taquialic, made delirious speeches of a mystical-religious content, and was aggressive. She was medicated with 5 mg of haloperidol, 50 mg of promethazine and 15 mg of midazolam intramuscularly. Family members reported that the patient had no previous psychiatric history or a history of psychoactive substance use. There was no history of psychiatric illness in first- or second-degree relatives. They reported that the patient had hypothyroidism and used 75 micrograms of levothyroxine per day. She was medicated with risperidone up to a dose of two mg per day and 500 mg of sodium valproate per day. She underwent nuclear magnetic resonance with the finding of small and rare focal punctate signal changes in the white matter of both cerebral hemispheres of probable microvascular etiology. The patient experienced progressive improvement of her symptoms and maintained outpatient follow-up. A CSF lumbar puncture was not performed.

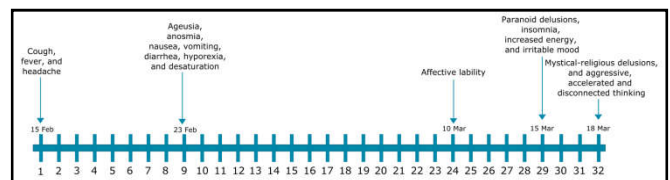


Figure 5. Evolution of symptoms in case 5

Case 6

Case 6 was a 51-year-old male patient was diagnosed with Covid-19 confirmed by testing for SARS-CoV-2 RNA in the nasopharynx. Due to respiratory symptoms, he was medicated with azithromycin, ivermectin and dexamethasone. The dose of dexamethasone was equivalent to approximately 40 mg of prednisone per day for five days. Within 13 days of the onset of symptoms, he presented restlessness, agitation and insomnia. He said he felt he was going to die and sought hospital care. He was medicated with tenoxicam, ibuprofen, and zolpidem and kept using oxygen at home.

After three days, he began to express delusions of persecution and religious mystics. He said there was a spirit in the oxygen mask and he needed to get away from it. He would put a Bible in his hand and say he was talking to God.

After two days, he sought care in a psychiatric emergency center. Five mg of haloperidol and 50 mg of promethazine were administered intramuscularly due to agitation, and 20 mg of levomepromazine was prescribed orally at night. The

patient's symptoms progressively improved during the following week. The patient did not use continuous medications and had no history of psychoactive substance use or previous psychiatric illness. There was no history of psychiatric illness in first- or second-degree relatives. Imaging exams and a CSF lumbar puncture were not performed.

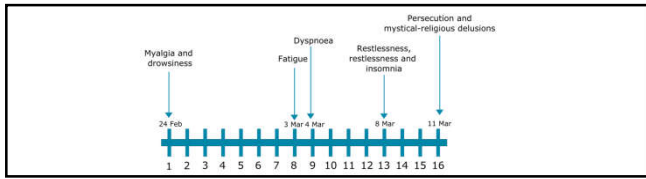


Figure 6. Evolution of symptoms in case 6

DISCUSSION

Covid-19 infection has been linked to mental health complications. An increase in the incidence of manifestations such as anxiety and psychosis has been described; however, knowledge about such complications is still limited^{5,9}. Thus, descriptive observational studies are important in formulating hypotheses about the pathophysiology, presentation, prognosis and management of Covid-19 complication. Five published cases in which the first manic episode was associated with Covid-19 infection were found (Lu, 2020; Jaworowski, 2020; Mawhinney, 2020). Extending previous reports, this study describes six cases of Covid-19 infection with a first manic episode in the Brazilian population and correlates the available data on these complications to the findings on Covid-19 described in the literature. The pathophysiological mechanism involved in neuropsychiatric manifestations of Covid-19 is still unclear (Taquet, 2021; Parra, 2020). A possible explanation would be the direct effect on the central nervous system through angiotensin-converting enzyme-2 causing infection and neuronal death (Song, 2021). Microstructural brain alterations associated with SARS-CoV-2 have already been described. Among the findings is a significant increase in white matter volume in the right cingulate gyrus⁴. The cingulate is an important framework for the study of bipolar disorder as it provides white matter connections within the corticolimbic system. Changes in the cingulate, including those associated with the severity of manic symptoms, have been described (Roybal, 2015; Wang, 2008). Among the cases reported, the patient in case 5 underwent brain magnetic resonance imaging and focal punctiform changes in the white matter of both cerebral hemispheres of probable microvascular etiology were found. A second hypothesis for the etiology of brain alterations would be the thrombogenic potential of the virus. Several reports have associated Covid-19 with vascular manifestations due to thromboembolism and microvascular dysfunction, especially in patients who had more severe infections (Magro, 2020; Available from: <https://onlinelibrary.wiley.com/doi/10.1111/ene.14380>). Another possibility for the association between SARS-CoV-2 and manic symptoms would be the inflammatory response. Patients with Covid-19 have been shown to produce a major inflammatory response with likely activation of T-helper-1 lymphocytes (Huang, 2020). This finding supports the hypothesis of the pathogenesis of manic symptoms due to inflammation, formulated after the finding that autoimmune diseases and infections are risk factors for mood disorders (Benros, 2013). Two patients had diabetes mellitus decompensation, which is associated with an increased inflammatory response and related to bipolar

disorder (Chien, 2010; Donath, 2011). A relationship between diabetes and first manic episodes, mainly late onset, has been demonstrated, which is in agreement with the cases reported in this study²³. Four patients used dexamethasone at doses equivalent to 40 mg per day of prednisone for five to seven days. Adverse effects associated with corticosteroid use include euphoria and hypomania, which are associated with up to a fivefold increased risk of developing mania^{24,25}. Symptoms may appear even in short periods of use, and their occurrence appears to be dose-dependent. As an example, Brown et al. (2002) described the observation of mania with no previous history based on the use of 40 mg of prednisone daily for one to two weeks of duration in patients with asthma²⁶.

CONCLUSION

Although few cases have been reported to date, a relationship was found between manic episodes and Covid-19 infection in patients. The findings of this study suggest that for mild symptomatological cases, the use of corticosteroids should be disregarded because the risk of inducing a manic episode outweighs the benefit from inhibiting the evolution of respiratory disease due to the infection. The use of anticoagulation in severe conditions is reinforced by the finding of microlesions in the white matter of probable microvascular etiology. Psychiatric manifestations started between 5 and 24 days after the infection, showing the importance of observation in the first 30 days of illness to identify the manic episode. All patients had psychotic symptoms, which draws attention to the seriousness of the complications. Of the six cases described, four cases, as well as the first case described by Lu S. et al. (2020), were older than 50 years, which suggests a higher prevalence in older patients (Lu, 2020).

CONFLICTS OF INTEREST STATEMENT: The authors certify that there is no conflict of interest with any financial organization regarding the material discussed in the manuscript.

FUNDING STATEMENT: The authors report no involvement in the research by the sponsor that could have influenced the outcome of this work.

GLOSSARY OF ABBREVIATIONS

CSF: Cerebrospinal fluid.

RNA: Ribonucleic acid.

SARS-CoV-2: Severe Acute Respiratory Syndrome Coronavirus 2.

REFERENCES

- American Psychiatric Association. Diagnostic and statistical manual of mental disorders. 5th ed. Arlington, VA; 2013.
- Benros ME, Waltoft BL, Nordentoft M, Østergaard SD, Eaton WW, Krogh J, et al. Autoimmune Diseases and Severe Infections as Risk Factors for Mood Disorders: A Nationwide Study. *JAMA Psychiatry*. 2013. Aug 1;70(8):812.

- Brown ES, Suppes T, Khan DA, Carmody TJ. Mood Changes During Prednisone Bursts in Outpatients With Asthma: *J Clin Psychopharmacol*. 2002 Feb;22(1):55–61.
- Chien I-C, Chang K-C, Lin C-H, Chou Y-J, Chou P. Prevalence of diabetes in patients with bipolar disorder in Taiwan: a population-based national health insurance study. *Gen Hosp Psychiatry*. 2010 Nov;32(6):577–82.
- Donath MY, Shoelson SE. Type 2 diabetes as an inflammatory disease. *Nat Rev Immunol*. 2011 Feb;11(2):98–107.
- Drozdowicz LB, Bostwick JM. Psychiatric Adverse Effects of Pediatric Corticosteroid Use. *Mayo Clin Proc*. 2014 Jun;89(6):817–34.
- Fardet L, Petersen I, Nazareth I. Suicidal Behavior and Severe Neuropsychiatric Disorders Following Glucocorticoid Therapy in Primary Care. *Am J Psychiatry*. 2012 May;169(5):491–7.
- Gencer A, Kesebir S, Yilmaz E. Diabetes in first manic episode. *J Mood Disord*. 2013;3(1):17.
- Huang C, Wang Y, Li X, Ren L, Zhao J, Hu Y, et al. Clinical features of patients infected with 2019 novel coronavirus in Wuhan, China. *The Lancet*. 2020 Feb;395(10223):497–506.
- Iadecola C, Anrather J, Kamel H. Effects of COVID-19 on the Nervous System. *Cell*. 2020 Oct;183(1):16-27.e1.
- Jaworowski S, Weiser M, Gropp C, Malka M. Three Cases of COVID-19-related First Onset Brief Reactive Psychosis. *Isr Med Assoc J*. 2020;22:612.
- Lu S, Wei N, Jiang J, Wu L, Sheng J, Zhou J, et al. First report of manic-like symptoms in a COVID-19 patient with no previous history of a psychiatric disorder. *J Affect Disord*. 2020 Dec;277:337–40.
- Lu Y, Li X, Geng D, Mei N, Wu P-Y, Huang C-C, et al. Cerebral Micro-Structural Changes in COVID-19 Patients – An MRI-based 3-month Follow-up Study. *EClinicalMedicine*. 2020 Aug;25:100484.
- Magro C, Mulvey JJ, Berlin D, Nuovo G, Salvatore S, Harp J, et al. Complement associated microvascular injury and thrombosis in the pathogenesis of severe COVID-19 infection: A report of five cases. *Transl Res*. 2020 Jun;220:1–13.
- Malentacchi M, Gned D, Angelino V, Demichelis S, Perboni A, Veltri A, et al. Concomitant brain arterial and venous thrombosis in a COVID-19 patient. *Eur J Neurol* [Internet]. 2020 Sep [cited 2021 Jul 18];27(9). Available from: <https://onlinelibrary.wiley.com/doi/10.1111/ene.14380>
- Mawhinney JA, Wilcock C, Haboubi H, Roshanzamir S. Neurotropism of SARS-CoV-2: COVID-19 presenting with an acute manic episode. *BMJ Case Rep*. 2020 Jun;13(6):e236123.
- Parra A, Juanes A, Losada CP, Álvarez-Sesmero S, Santana VD, Martí I, et al. Psychotic symptoms in COVID-19 patients. A retrospective descriptive study. *Psychiatry Res*. 2020 Sep;291:113254.
- Roberts KA, Colley L, Agbaedeng TA, Ellison-Hughes GM, Ross MD. Vascular Manifestations of COVID-19 – Thromboembolism and Microvascular Dysfunction. *Front Cardiovasc Med*. 2020 Oct 26;7:598400.
- Roybal DJ, Barnea-Goraly N, Kelley R, Bararpour L, Howe ME, Reiss AL, et al. Widespread white matter tract aberrations in youth with familial risk for bipolar disorder. *Psychiatry Res Neuroimaging*. 2015 May;232(2):184–92.
- Song E, Zhang C, Israelow B, Lu-Culligan A, Prado AV, Skriabine S, et al. Neuroinvasion of SARS-CoV-2 in human and mouse brain. *J Exp Med*. 2021 Mar 1;218(3):e20202135.
- Taquet M, Geddes JR, Husain M, Luciano S, Harrison PJ. 6-month neurological and psychiatric outcomes in 236 379 survivors of COVID-19: a retrospective cohort study using electronic health records. *Lancet Psychiatry*. 2021 May;8(5):416–27.
- Taquet M, Luciano S, Geddes JR, Harrison PJ. Bidirectional associations between COVID-19 and psychiatric disorder: retrospective cohort studies of 62 354 COVID-19 cases in the USA. *Lancet Psychiatry*. 2021 Feb;8(2):130–40.
- Tu TM, Goh C, Tan YK, Leow AS, Pang YZ, Chien J, et al. Cerebral Venous Thrombosis in Patients with COVID-19 Infection: a Case Series and Systematic Review. *J Stroke Cerebrovasc Dis*. 2020 Dec;29(12):105379.
- Velosa J, Delgado A, Finger E, Berk M, Kapczinski F, Azevedo Cardoso T. Risk of dementia in bipolar disorder and the interplay of lithium: a systematic review and meta-analyses. *Acta Psychiatr Scand*. 2020 Jun;141(6):510–21.
- Wang F, Jackowski M, Kalmar JH, Chepenik LG, Tie K, Qiu M, et al. Abnormal anterior cingulum integrity in bipolar disorder determined through diffusion tensor imaging. *Br J Psychiatry*. 2008 Aug;193(2):126–9.
- World Health Organization. Statement on the second meeting of the International Health Regulations (2005) Emergency Committee regarding the outbreak of novel coronavirus (2019-nCoV) [Internet]. 2020 [cited 2021 Jun 27]. Available from: [https://www.who.int/news/item/30-01-2020-statement-on-the-second-meeting-of-the-international-health-regulations-\(2005\)-emergency-committee-regarding-the-outbreak-of-novel-coronavirus-\(2019-ncov\)](https://www.who.int/news/item/30-01-2020-statement-on-the-second-meeting-of-the-international-health-regulations-(2005)-emergency-committee-regarding-the-outbreak-of-novel-coronavirus-(2019-ncov))
