



ISSN: 0975-833X

Available online at <http://www.journalcra.com>

International Journal of Current Research  
Vol. 12, Issue, 06, pp.11931-11932, June, 2020

DOI: <https://doi.org/10.24941/ijcr.38960.06.2020>

INTERNATIONAL JOURNAL  
OF CURRENT RESEARCH

## REVIEW ARTICLE

# BILATERAL PRESENCE OF TRIFURCATION OF POPLITEAL ARTERY: VARIATION NOTED IN RELEVANCE WITH INCREASED USE OF INFRAGENICULAR ARTERIAL INTERVENTIONS FOR LIMB SALVAGE IN CASES WITH CRITICAL LIMB ISCHEMIA

\*Dr. Preeti Awari

Assistant Professor, Department of Anatomy, Dr.D.Y. Patil Medical College, Hospital and Research centre, Dr. D.Y. Patil Vidyapeeth (Deemed to be University) Pimpri, Pune

### ARTICLE INFO

#### Article History:

Received 20<sup>th</sup> March, 2020  
Received in revised form  
09<sup>th</sup> April, 2020  
Accepted 17<sup>th</sup> May, 2020  
Published online 29<sup>th</sup> June, 2020

#### Key Words:

Infragenicular Arterial Interventions,  
Trifurcation of Popliteal Artery, Critical  
Limb Ischaemia, Endovascular  
Interventions.

Copyright © 2020, Dr. Preeti Awari. This is an open access article distributed under the Creative Commons Attribution License, which permits unrestricted use, distribution, and reproduction in any medium, provided the original work is properly cited.

Citation: Dr. Preeti Awari. 2020. "Bilateral presence of trifurcation of popliteal artery: variation noted in relevance with increased use of infragenicular arterial interventions for limb salvage in cases with critical limb ischemia", *International Journal of Current Research*, 12, (06), 11931-11932.

### ABSTRACT

Knowing about anatomical variations in the terminal branching pattern of popliteal artery is of great clinical importance for the endovascular surgeons while planning for the endovascular interventions and also to minimize the post operative complications as hemorrhage. For the same reason author has notified a case of bilateral presence of trifurcation of popliteal artery in a adult male cadaver and explained embryological basis of the same.

## INTRODUCTION

Infragenicular arterial interventions have become routine for limb salvage in cases of critical limb ischaemia. With use of advanced technology and devices noninvasive procedures as endovascular interventions have become more popular for limb salvage (Francisco Acín, 2014) This has attracted many researchers to revise the normal anatomy and to note the variations in the terminal branching pattern of popliteal artery. Osami Kawarada *et al* states that in about 10% of the population variations in branching pattern popliteal artery can be seen. It is difficult to rule out variation and diagnose occlusion in cases of severe infrapopliteal artery disease. When variation is seen in one extremity, there is a 28–50% chance that the same type of variation will be present in another extremity (Osami Kawarada *et al.*, 2014). With this insight the author have noted a case of bilateral presence of trifurcation of popliteal artery in a dissected cadaver.

**Observation:** Many authors have defined trifurcation of popliteal artery into anterior tibial artery, posterior tibial artery and peroneal artery where length of tibioperoneal trunk less than 5mm (Siriporn Thitilertdech, 2013; Kim, 1989).

#### \*Corresponding author: Dr. Preeti Awari,

Assistant Professor, Department of Anatomy, Dr.D.Y. Patil Medical College, Hospital and Research centre, Dr. D.Y. Patil Vidyapeeth (Deemed to be University) Pimpri, Pune.

Same variation has been noted by the author as trifurcation of popliteal artery in a middle aged male cadaver in both lower extremities. On left side tibioperoneal trunk is 2mm long. On the right side tibioperoneal trunk is absent where just below the popliteus muscle popliteal artery is dividing into its main terminal branches.

## DISCUSSION

**Embryological basis for variations seen in popliteal artery division:** The axis artery for the lower extremity travels in front of popliteus. At the lower border of popliteus it traverses between tibialis posterior and the interosseus membrane. The two longitudinal blood vessels arise from the axis artery at the upper border of the popliteus muscle as primitive posterior tibial and primitive peroneal arteries which run superficial to popliteus. The proximal parts of these two vessels unite to form distal part of popliteal artery. Most of the primitive peroneal artery disappears and the axis artery gets incorporated to form definitive peroneal artery. At the lower border of popliteus muscle the axis artery gives off a perforating branch which passes in the anterior compartment of the leg forming the anterior tibial artery (Grays Anatomy, Susan Standing, 2008) From above discussion we can conclude that if the proximal portion of the primitive posterior tibial and primitive peroneal artery falls short of union then that gives rise to small tibioperoneal trunk.

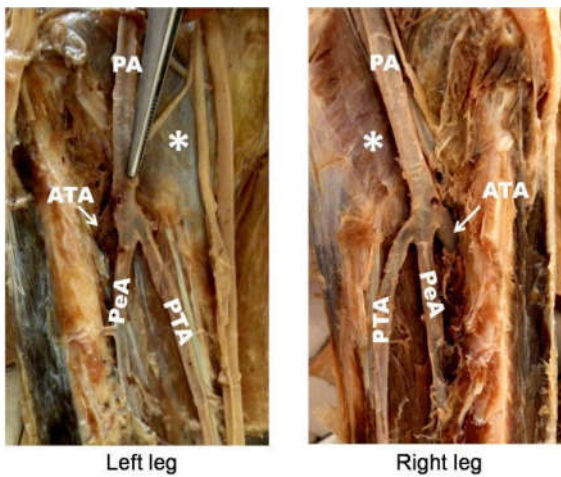


Figure 1: Bilateral presence of trifurcation of popliteal artery into anterior tibial artery (ATA), posterior tibial artery (PTA) and peroneal artery (PeA), \* denotes underlying popliteus muscle

In 1989, D kim *et al* found the trifurcation of popliteal artery in 2% of lower extremities out of 605 (Kim, 1989) In 2011, Ertugrul Mavili *et al* found trifurcation of popliteal artery in 5.4% of lower extremities out of 535 (Ertugrul Mavili, 2011) Krzysztof A. Tomaszewski *et al* reviewed 33 researches related to variations in popliteal artery branching pattern. They mentioned a prevalence of 2% all together of trifurcation of popliteal artery (Krzysztof *et al.*, 2017) Pelin Seher Oztekin found trifurcation in 3.8% of lower extremities out of 495 lower extremities (Pelin Seher Oztekin, 2015) H. Demirtas *et al* found same pattern in 2.5% of cases out of 1261 lower extremities (Demirtas, 2016) Lukasz Olewnik *et al* found trifurcation in 12% of lower extremities out of 100 in 2019 (Lukasz Olewnik *et al.*, 2019). This seems to be rare variation as mentioned in above studies but there are studies done by Wanderley *et al* and Dr. Ayogu Stephen Uchenna *et al* where they found trifurcation in 14.28% (out of 21 lower extremities) and 25% (out of 24 lower extremities) lower extremities respectively. Such a big difference in the percentage of variation noted made the author to notify the variation.

## Conclusion

The knowledge of branching pattern of the popliteal artery is important for surgical and vascular interventions in the popliteal region in order to minimize the chances of hemorrhage and surgical complications due to anatomical variations (Krzysztof, 2017; Pelin Seher Oztekin, 2015; Lukasz Olewnik, 2019; Ankit Khandelwal, 2014). This variation noted by author is a contribution to the information available.

**Conflicts of interests:** There are no conflicts of interests

## REFERENCES

Francisco Acín, César Varela, Ignacio López deMaturana, Joaquín de Haro, Silvia Bleda, and Javier Rodriguez-Padilla, 2014. *Clinical Study* Results of Infrapopliteal Endovascular Procedures Performed in Diabetic Patients with Critical Limb Ischemia and Tissue Loss from the

Perspective of an Angiosome-Oriented Revascularization Strategy, Hindawi Publishing Corporation International Journal of Vascular Medicine Volume, Article ID 270539, 13 pages, <http://dx.doi.org/10.1155/2014/270539>

Osami Kawarada, Satoshi Yasuda, Janice Huang, Yasuhiro Honda, Peter J. Fitzgerald, Masaharu Ishihara, Hisao Ogawa, 2014. Contemporary Infrapopliteal Intervention for Limb Salvage and Wound Healing, Harmonization of Revascularization and Wound Management, *Circulation Journal Official Journal of the Japanese Circulation Society*, Vol.78, July <http://www.j-circ.or.jp>, pages: 1540-1549

Siriporn Thitilertdech, Sithee Praneatpolgrang, Thanaporn Rungruang. 2013. New Patterns of the Popliteal Artery and its Branches in Thais. *Siriraj Med J.*, 65,47-50.

Kim D, Orron D, Skillman JJ. 1989. Surgical Significance of Popliteal Arterial Variants - a unified angiographic classification, *Ann. Surg.* December, pg 780

Neville R F, Franco C D, Anderson R J. 1990. Popliteal artery agenesis: A new anatomic variant. *J Vasc Surg.*; 12: 573-576.

Susan standing, Grays anatomy, section IX. Pelvic Girdle and Lower Limb chapter 85. Development of pelvic girdle and lower limb, *The Anatomical Basis of Clinical Practice* 40<sup>th</sup> edition, published by Elsevier, printed in China, page 1463

Ertugrul Mavili, Halil Donmez, Guven Kahrirman, Aysel Ozaslamaci, Nevzat Ozcan, Kutay Tasdemir, Popliteal artery branching patterns detected by digital subtraction Angiography, *Diagn Interv Radiol Turkish Society of Radiology* 2011; 17:80-83

Krzysztof A. Tomaszewski, Patrick Popieluszko, Matthew J. Graves, Przemysław A. Pękala, Brandon Michael Henry, Joyeeta Roy, Wan Chin Hsieh and Jerzy A. Walocha, The evidence-based surgical anatomy of the popliteal artery and the variations in its branching patterns, *JOURNAL OF VASCULAR SURGERY*. 2017, 65:521-9

Pelin Seher Oztekin\*, Elif Ergun, Esra Cıvgın, Hasan Yigit, Pınar Nercis Kosar, Variants of the popliteal artery terminal branches as detected by multidetector ct, *De Gruyter Open Med.* 2015; 10: 483-491

Demirtas, H., B. Degirmenci, A.O. Celik, A. Umul, M. Kara, A.R. Aktas, T. Parpar, Anatomic variations of popliteal artery: Evaluation with 128-section CT-angiography in 1261 lower limbs, *Diagnostic and Interventional Imaging* (2016) 97, 635-642

Lukasz Olewnik Piotr Labętowicz Michal Podgorski, Michal Polgaj, Kacper Ruzik, Mirolaw Topol, Variations in terminal branches of the popliteal artery: cadaveric study, *Surgical and Radiologic Anatomy* (2019) 41:1473-1482 <https://doi.org/10.1007/s00276-019-02262-3>

Ankit Khandelwal, Pooja Rani, Mahindra Nagar, Variations in the branching pattern of popliteal artery and it's clinical implications: a cadaveric study, *International journal of current research and review*, volume 6, issue 9, August 2014