



ISSN: 0975-833X

Available online at <http://www.journalcra.com>

INTERNATIONAL JOURNAL  
OF CURRENT RESEARCH

International Journal of Current Research  
Vol. 12, Issue, 01, pp.9872-9882, January, 2020

DOI: <https://doi.org/10.24941/ijcr.37663.01.2020>

## RESEARCH ARTICLE

### THE VALUE OF ULTRA SOUND IN EVALUATION OF THE FOCAL HEPATIC LESIONS

\*Dr. Heba Zaid Mohammed Wafeq, Dr. Khairi Awaad Hamad and Dr. Israa Basheer Abd Allah

Department of Radiology, AL-Batool Teaching Hospital, University of Mosul, Iraq

#### ARTICLE INFO

##### Article History:

Received 04<sup>th</sup> October, 2019

Received in revised form

10<sup>th</sup> November, 2019

Accepted 29<sup>th</sup> December, 2019

Published online 30<sup>th</sup> January, 2020

##### Key Words:

Liver sonography,  
US diagnosis, Focal Hepatic Lesion,  
Liver Neoplasm, Hepatic Hydatid Cyst,  
Liver Abscess, Hepatic Hemangioma,  
Liver imaging.

#### ABSTRACT

**Objective:** Assessing the value of conventional ultrasound (US) for detection and characterization of focal hepatic lesion. **Setting:** The examination conducted in Radiological department in Al-Zahrawi Teaching Hospital, IBN-Sina Teaching Hospital and Oncology and Nuclear Medicine Hospital. **Participants:** Selective 80 patients referred for US department with focal hepatic lesion and their diagnosis confirmed by CT and histopathological examination. **Result:** Of 80 patients with focal hepatic lesion, 41 cases (51.2%) found in male and mean age group is between 51-60 years. The hepatic focal lesion found to be multiple in 46 cases (57.5%) and the right lobe of the liver is predominately involved in 45 cases (56.3%). Benign hepatic lesions were more common than malignants which was 43 cases (54%) of total sample. **Solid** hepatic lesion forms large constituting in about 53 cases (66.25%) that show low echogenicity in 21 cases (37.5%). Finally the lesions have been diagnosed by CT in 43 cases and histopathological examination in 37 cases show correct diagnosis by US in 24 cases and 26 cases respectively. **Conclusion:** US imaging is considered a reliable and cheap modality which is commonly used in evaluating most of the focal hepatic lesions as a first diagnostic method especially cystic lesions. Hydatid disease and secondary hepatic metastasis are more common focal hepatic lesions in our patients.

Copyright © 2020, Heba Zaid Mohammed Wafeq et al. This is an open access article distributed under the Creative Commons Attribution License, which permits unrestricted use, distribution, and reproduction in any medium, provided the original work is properly cited.

Citation: Dr. Heba Zaid Mohammed Wafeq, Dr. Khairi Awaad Hamad and Dr. Israa Basheer Abd Allah. 2020. "The value of ultrasound in evaluation of the focal hepatic lesions", *International Journal of Current Research*, 12, (01), 9872-9882.

## INTRODUCTION

The detection and characterization of focal liver masses are essential components of daily imaging practice. However, ultrasound (US) remains the initial study of choice in most clinical situations because of safety, minimal necessary pre-examination preparation and relatively low cost<sup>(3)</sup> and its ability to guide biopsy, and to characterize common benign lesions<sup>(2)</sup>. Recent clinical experience has shown that the addition of US contrast agent can enhance sonographic diagnostic capability including improving assessment of hepatic blood flow and the detection and characterization of hepatic neoplasm<sup>(25,26)</sup>. Anatomically, the liver is the largest abdominal organ, with normal weight 1400-1600 gm. It is divided into lobes by anatomic landmarks in which the major fissure of the liver divides the left and right lobes. The right lobe is usually 15-17cm in length and 20-22.5cm in transverse diameter. It is further subdivided into anterior and posterior segments by right hepatic vein (RHV). The left lobe of the liver is normally smaller than the right one and varies considerably in size. The left lobe is divided by the falciform ligament and ligamentum teres into the lateral and medial segments.

The caudate lobe is located posterior to porta hepatis between fissure for the ligamentum venosum and the IVC. The MPV lies anterior to IVC. It is divided into smaller LPV and larger RPV. The MHV is located in the main lobar fissure. The RHV is located in right intersegmental fissure. The LHV is located in left intersegmental fissure. The common bile duct lies anteriolateral to the portal vein and the hepatic artery anteriomedial. The parenchyma of the liver should be homogenous throughout. It is isoechoic with the spleen, more echogenic than the renal parenchyma, and less echogenic than pancreas<sup>(1)</sup> as shown in figures (1 and 2).

**Pathology:** The first task is to determine whether a mass is cystic or solid. Ultrasound should be the first diagnostic method to be used and it is helpful for defining the number and location of cysts and the internal structure of the cyst. The specificity is of 90%<sup>(8)</sup>. Cysts can be divided into simple (an anechoic lumen, a well defined wall, and increase posterior transmission) and complex (have an internal echoes, irregular thick walls, thick septation more than 3mm or mural modularity).

#### Simple hepatic cyst

- **True cyst:** it is an incidental finding and solitary round or oval shape, they are 4 times more frequent in women than in men<sup>(3,31)</sup> and the size varies from less than 1cm to

\*Corresponding author: Dr. Heba Zaid Mohammed Wafeq,

Department of Radiology, AL-Batool Teaching Hospital, University of Mosul, Iraq.

greater than 20cm<sup>(3)</sup>. It appears well-defined, echo-free lesion with good distal sonic enhancement. Thin septation is frequent<sup>(2)</sup>. It is considered to be of congenital origin, although it is discovered in the fifth to seventh decades of life<sup>(10, 28)</sup>. It is usually asymptomatic and required no treatment<sup>(8,12)</sup>.

- **Poly cystic liver disease** :- it is an inherited disorder which is characterized by the presence of multiple, scattered, fluid filled cysts of biliary origin<sup>(6)</sup>, most often associated with autosomal dominant polycystic kidney disease, but can occur in the absence of kidney cysts<sup>(6,31)</sup>.

### Complex cystic lesion

- **Infectious complex cysts** :- the most common liver disease with complex cystic features are :-

#### a-Liver abscesses

- **Pyogenic abscess**:- it is relatively rare. The right lobe is affected more often than the left by 2:1, bilateral involvement seen 5%(11). It is less common than amebic abscess. It has variable appearance, typically either poor defined, irregular marginated primarily hypoechoic lesion with bright punctuate echoes represented gas within abscess (2) or initially hyperechoic solid lesion to complex cystic mass may be noted (3). Micro abscesses may be seen as well(10).
- **Amebic liver abscess**:- it is the most common non-enteric complication of amebiasis. It tends to have oval or rounded shape of hypoechoic homogenous lesion and have low-level internal echoes throughout (2, 10).
- **Echinococcal cyst ( Hydatid disease)**: US can serve as the primary diagnostic tool<sup>(3)</sup>. It usually affects the liver and lungs, right lobe is the most frequently up to 75% involved<sup>(21)</sup>. It appears as a well-defined anechoic masses with or without hydatid sand and septa, multiple small internal echogenic foci referred as (snow storm signs ) are seen<sup>(9)</sup>. Classically, cyst is present as complex, heterogenous mass, with well-defined walls, containing double echogenic lines separated by hypoechoic layer<sup>(3)</sup>. Multiple septa between daughter cysts within mother cysts is a characteristic but rare. Localized splits in the cyst wall, with floating, undulating membrane are also a characteristic<sup>(24)</sup>. Calcification is seen in 20-30% of hydatid cysts, usually peripheral curvilinear or ring like pattern<sup>(9,21,24)</sup>. It is of an echographic sign with low sensitivity<sup>(7)</sup>.
- **Hematoma**:- they are usually caused by trauma or surgery. Haemorrhage within solid neoplasm, especially hepatocellular carcinoma and adenoma, is the most common cause<sup>(13)</sup>. Haemorrhage into preexisting simple cyst is rare<sup>(12)</sup>. The US appearance depend on the severity of the bleeding and the timing of the scan related to the onset of bleeding. Both acute and sub acute stages are appear more homogenous complex cystic mass, whereas in chronic cases may fill with internal echoes. The uniform low-level internal echoes or fluid- fluid level, thick irregular septation are also seen<sup>(3)</sup>.
- **Neoplastic cysts**:- Rare biliary cyst adenoma occurs primarily among middle age women<sup>(3,10)</sup>. It is usually seen as large unilocular or multilocular cystic mass<sup>(10,31)</sup>. Typically, it is an ovoid, multiloculated anechoic mass

with highly echogenic septation with mural nodularity and well-defined thick wall<sup>(16)</sup>.

- Cystic metastasis are uncommon and appear as complex cysts which occur most frequently with metastasis from squamous cell carcinoma and gastro intestinal stromal tumors<sup>(2,10)</sup>. Cystic metastasis from ovarian and colonic carcinoma, sarcoma, melanoma, neuro-endocrine tumors may occur<sup>(31)</sup>.

**Solid hepatic masses** : The first parameter evaluation for differential diagnosis of solid liver masses is the echogenicity of lesion. Solid lesions are placed into: non-hyperechoic and hyperechoic lesions which are sub classified on the basis of presence or absence of a peripheral hypoechoic halo that suspicious for malignancy<sup>(3)</sup>.

- **Cavernous hemangioma** :- it is the most common benign tumors affecting liver, more often in women than men of 5:1 ratio<sup>(13)</sup>, frequently in middle age. The vast majority are asymptomatic and usually solitary<sup>(14,19)</sup>. Typically, it is less than 5cm<sup>(14)</sup> and uniform echogenic mass of sharp well-defined margin and no peripheral halo, posterior acoustic enhancement may be seen<sup>(2,3)</sup>.
- **Focal fatty disease**: Solitary or multiple areas of hypoechogenicity within diffusely bright fatty echoes of the liver (focal fatty spare) represented the most common pattern, less commonly an areas of hyperechogenicity within relatively non-echogenic liver (focal fatty infiltration)<sup>(17)</sup>. It has characteristic location as medial segment of left lobe, anterior to the portal vein bifurcation, adjacent to the gall bladder<sup>(3,20)</sup> with geographic (abruptly angled) margin<sup>(3)</sup>.
- **Focal nodular hyperplasia** :- it is the second most common benign tumor<sup>(13)</sup>. It commonly appears as hypoechoic or isoechoic mass with tendency to be more homogenous well circumscribed mass; it may exhibit central scar<sup>(2,3)</sup>, usually less than 5 cm with sharp margin<sup>(19,34)</sup>.
- **Hepatic adenoma** :- it is a rare benign tumor of liver<sup>(13,15)</sup>, incidentally discovered<sup>(13,19)</sup> usually in females with history of oral contraceptive use<sup>(4,15)</sup>. Solitary lesion in 70% to 80% although multiplicity seen in 20%<sup>(3,4,19)</sup>. It has variable appearance, an echogenic mass with halo is one of its presentation but may be hypoechoic or isoechoic<sup>(3)</sup>, calcification may be present<sup>(15)</sup>.
- **Hepatocellular carcinoma (HCC)** :- it is the most common primary liver malignancy affecting middle aged and elderly individuals. The majority of cases occur in a back ground of hepatitis B and C viral infection and/or liver cirrhosis<sup>(27)</sup>. It has mosaic pattern, furthermore about 75% of small HCCs (<5cm) are hypoechoic, as enlarge tend to developed hypoechoic peripheral rim and larger masses usually heterogenous<sup>(2,29)</sup>. Calcification is common 20-25%<sup>(2)</sup>. Heterogenous hyperechoic lesion and target lesion are also seen<sup>(33)</sup>, hyperechoic lesion with peripheral hypoechoic halo is common presentation<sup>(3,5)</sup>. It may be solitary or multifocal<sup>(3)</sup> and represent the most common cause of non traumatic hepatic haemorrhage<sup>(13)</sup>.
- **Cholangiocarcinoma** :- it arises from bile duct and about 30% of all primary malignancy, secondly after hepatocellular carcinoma<sup>(3)</sup>, mainly tumor of elderly >65 years<sup>(19,35)</sup>, which is either peripheral or hilar, sonographically of peripheral type are variable but solitary hypoechoic lesion are more frequent<sup>(2,35)</sup>, hilar type presents earlier with ductal obstruction and dilatation of

hepatic bile duct, usually not associated with large mass<sup>(2)</sup>. Focal duct wall thickening or hypoechoic solid mass surrounding bile duct may be seen<sup>(33)</sup>.

- Hepatic metastasis :-** liver is the most common sites for metastasis<sup>(5,18)</sup>. The sensitivity of conventional unenhancement US was 71%. Which improved to 87% by the use of contrast enhanced US<sup>(26)</sup>. They are 18-20 times more common than HCC, and multifocal in 90% of patients<sup>(2)</sup>. Common primary tumor metastasis are lung, breast, melanoma and it varies in size from few millimeters to several centimeters<sup>(18)</sup>. Suggestive findings are multiple solid lesions with hypoechoic halo surrounding liver mass<sup>(3,5)</sup>, but most of hepatic metastasis are hyperechoic, hypoechoic and cystic with mixed echogenicity may be seen<sup>(10,5)</sup>; target or bull's eye appearance is common<sup>(2,18)</sup>. Cystic type is uncommon which arises from mucine producing primaries or necrosis within tumor<sup>(10)</sup>. Most common hyperechoic lesion with halo; colorectal and renal cell carcinoma, neuroendocrine tumor, choriocarcinoma and vascular tumors<sup>(3,5)</sup>, while hypoechoic lesion from breast, lung, esophagus, stomach, pancreas, non Hodgkin lymphoma<sup>(3)</sup>. Hemorrhagic metastasis is uncommon frequently from lung, renal carcinoma and melanoma<sup>(13)</sup>.
- Lymphoma :-** it involves the liver in 20%-50% of patients, with Hodgkin disease and slightly high in non Hodgkin lymphoma, it may cause diffuse homogenous involvement producing only hepatomegaly<sup>(18)</sup>, but homogenous hypoechoic well-defined mass can be seen and may cause target lesion, uncommon to have cystic components or calcify and may exhibit posterior acoustic enhancement<sup>(3)</sup>.

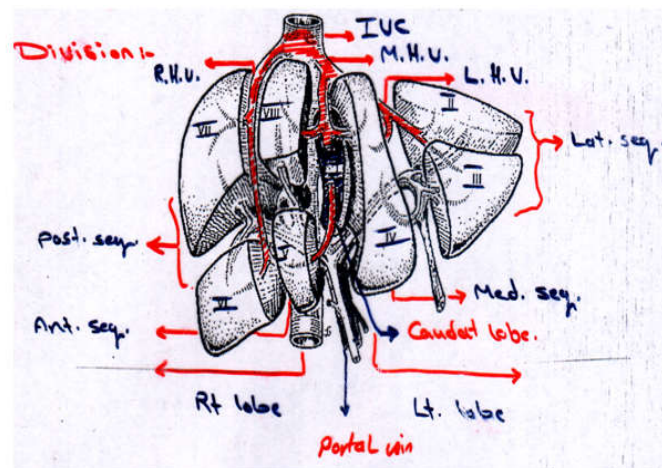


Figure 2. The segmental anatomy of the liver

Table 1. Distribution of hepatic lesion according to gender

Age of patient	Total no.	%
1-10	2	2.5%
11-20	5	6.25%
21-30	12	15%
31-40	11	13.75%
41-50	19	23.75%
51-60	20	25%
61-70	9	11.25%
> 71	2	2.5%
Total no.	80	100%

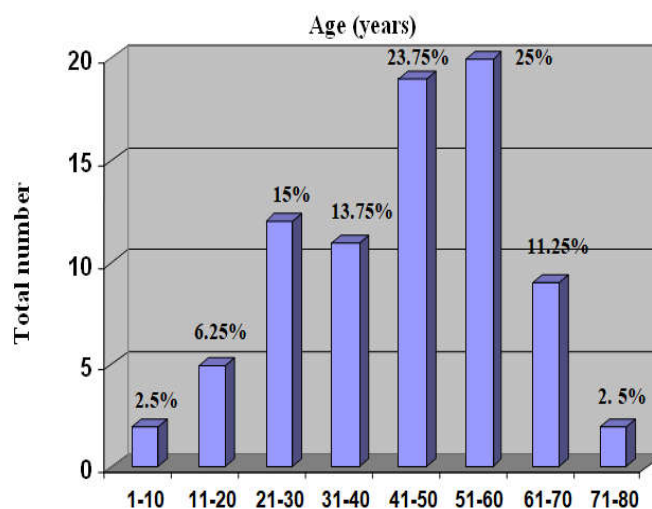


Figure 3. Histogram showing age distribution of the patients

Table 2. Distribution of different hepatic lesion according to gender

Type of lesion	Male	Female
Malignant primary	6	1
Secondary metastasis	13	17
Hydatid disease	9	17
Cystic disease	2	1
Abscess	4	-
Focal fatty disease	1	1
Hemangioma	4	2
Tuberculosis	2	-
Total number	41 (51.2%)	39 (48.8%)

**Aim of the study :-**To assessing the role of conventional ultrasonographic imaging modality as first diagnostic tool in detecting, characterizing and differential diagnosis of different focal hepatic lesions with screening the liver for the lesion number and location.

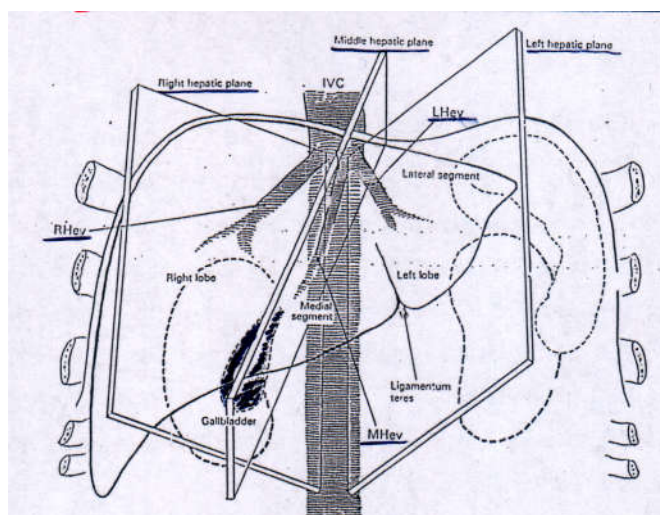


Figure 1. Normal anatomy of the liver

Segment I represents the caudate lobe. The lateral segment of left lobe is divided into segments II and III. The medial segment of the left lobe is divided into segments IVa and IVb . The anterior segment of the right lobe is divided into segments V and VIII. The posterior segment of the right lobe is divided into segments VI and VII.

**Patients and methods.** This study constitute 80 patients who were presented to radiological department at IBN-Sina Teaching Hospital and Al-Zahrawi Maternity Hospital and Oncology and Nuclear Medicine Hospital in Mosul City with hepatic focal lesions during a period of 10 months between December 2005 and September 2006 .The patients group consists of 41 men and 39 women with age ranging between 1 year to over age of 70 years. Before starting the sonographic examination, the purpose and aim of the study was explained to each patient and oral informed consent was obtained according to the ethical guide lines. All patients were prospectively examined with conventional trans-abdominal US and final diagnosis was confirmed by CT images and biopsy at pathological department and surgical exploration with the intention of creative hepatic surgery.

**Baseline** trans-abdominal US were performed by using Schimatzu and Philips with main stay of 3.5-5 MHz curved array transducers. There is no specific preparation that is necessary for examination. The scan is generally performed in supine position with deep inspiration and there may be a need for scanning the patients with left lateral decubitus position or even sitting up, and almost always liver should be evaluated in both longitudinal and transverse planes.

The spiral CT scanner used was Siemens Somatom plus 4 made in Germany. Sophisticated X-ray machine was linked to a computer to produce detailed images of the abdomen, the patient lie on a movable table that is quided into X-ray generating device looks like an enormous doughnut shape that rotates around the body, when taking the images, these images can be viewed on a monitor or reproduced as photographs with 5 mm thickness of slices and the procedure length was 20-24 seconds, rapid spiral CT scanner minimizes the risk of movement artifact and gives marked improved special resolution.

## RESULTS

**The analysis of the data collected in this study during 10 months has shown that:** Out of 80 patients presented to radiological department of the hospitals, 52 cases (65%) suffer from right upper quadrant, pain, fever, jaundice, loss of weight with malaise and anorexia. Clinical examination has revealed an enlarged liver which is palpable below costal margin in 35 cases (43.75%). In spite that 28 patients (35%) pass asymptomatic and discover focal hepatic lesion incidentally in 45 patients (56%) during general examination of the abdomen.

- **Sex and age distribution :** Out of 80 patients with hepatic focal lesion, their age ranged from 1 year-more than 70 years. Table 1 and histogram summarized the distribution of focal lesion in relation to the gender of the patients. This table and its histogram show high incidence of the focal hepatic lesion at 4<sup>th</sup> decade of life and 5<sup>th</sup> decade and less frequent at 2<sup>nd</sup> and 3<sup>rd</sup> decade of life, while it is equal under the age of ten and above the age of seventy. The patient groups consist of 39 females (48.8%) and 41 males (51.2%) in which malignant lesion (secondary metastasis) is more common in male while cystic hydatid disease of the liver and malignancy (secondary metastasis) is more in female as shown in Table 2.

### •Imaging analysis of the liver :-

Echopattern of the liver was found to be normal in 56 cases (70%) independent to the type of the lesion, while there was a coarse echopattern in 20 cases (25%) which was found associated with secondary metastasis ( 12 cases), primary malignant tumor (3 cases), furthermore two cases are with hydatid disease and polycystic disease while 1 case is with tuberculosis. There was a high echopattern in 4 cases (5%) of which included secondary metastasis, primary malignant tumor, focal fatty disease and hydatid disease. Biliary passage included common bile duct which is found to be dilated in 5 cases (6.25%) that associated with primary malignant tumor (1 case) and secondary metastasis (4cases). Table 3 summarizes this finding in details.

An associated features that was found in 8 cases is lymphadenopathy which is (1 case) for primary malignant tumor and (7cases) with secondary metastasis as well as ascites that was seen in 8 cases, (6) of them are with secondary metastasis and (1) case for each of primary malignant tumor and tuberculosis.

- **Of the focal lesion :** In selective 80 patients with focal hepatic lesion have been found :-

**The lesion** is single in 34 cases (42.5%), while it was multiple in 46 cases (57.5%); among the single lesion, hydatid disease and malignancy are common finding, as well as in multiple lesions. Distribution of the different focal lesion according to the multiplicity is shown in Table 4. The location of the lesion is higher in right lobe about 45/80 (56.3%), while it is less in both lobes to 27/80 (33.7%) and very little in the left lobe up to 8/80 (10%); among the right and left lobes lesion hydatid disease is common, while malignancy is the common finding involved both lobes. The distribution of the different lesions according to lobe of liver is shown in Table 5. The size of the hepatic lesion was measured by US wide variable ranged from few millimeter to maximally 15cm and it was of various shapes: round, oval, irregular, unrecognized.

### •Focal lesion can be classified into 2 groups :-

- **Benign group** found in 43 cases (54%) including 26 cases of hydatid disease, 6 cases of hemanogioma, 4 cases of liver abscess, 2 cases for each of polycystic disease and tuberculosis and 1 case for each of focal fatty disease , simple cyst.
- **Malignant group** found in 37 cases (46%) which included 30 cases secondary metastasis and 7 cases primary malignant tumor that is shown in Table 6.

Over all these 2 groups it has been found that the focal lesion was purely cystic in 24 cases (30%), that was with benign group. While it was been purely solid in 53 cases (66.25% ) in which 19 cases show benign nature and 34 cases show malignant features. The remaining 3 cases (3.75%) show mixed pattern cystic and solid (low and heterogeneous), that was found in malignant group (1 case for primary malignant tumor and 2 cases secondary metastasis); that finding is shown in Table 7. Different echogenecity of the solid lesion was ranged from low level in 21 cases (4 with benign and 17 with malignant), high level in 19 cases (9 with benign and 10 with malignant) and heterogeneous appearance in 16 cases (6 with benign and 10 with malignant).

**Table 3. Relation between echopattern of liver and its biliary passage to type of focal lesion**

Type Echopattern	Malignant primary	Secondary metastasis	Hydatid disease	Abscess	Cystic disease		Tuberculosis	Hemangioma.	Focal fatty disease		Total no.
					Poly.	Simple			Focal fatty spare	Focal Fatty infiltration	
Normal	3	17	23	4	-	1	1	6	-	1	56
Coarse	3	12	2	-	2	-	1	-	-	-	20
High	1	1	1	-	-	-	-	-	1	-	4
Biliary passage + CBD											
Normal	1	4	-	-	-	-	-	-	-	-	5
Dilated	6	26	26	4	2	1	2	6	1	1	75

**Table 4. Incidence of the different hepatic lesions according to the multiplicity of lesions**

Type of the lesion	Multiplicity	
	Single	Multiple
Malignant primary	6	1
Secondary metastasis	7	23
Hydatid disease	11	15
Cystic disease	1	2
Abscess	4	-
Focal fatty disease	2	-
Hemangioma	2	4
Tuberculosis	1	1
Total number	34 (42.5%)	46 (57.5%)

**Table 5. Distribution of different focal lesion according to lobe**

Type Location	Malignant primary	Secondary metastasis	Hydatid disease	Abscess	Cystic disease		Tuberculosis	Hemangioma.	Focal fatty disease		Total no.
					Poly.	Simple			Focal fatty spare	Focal fatty infiltration	
Right lobe	5	10	17	4	-	1	1	5	1	1	45(56.3%)
Left lobe	1	1	4	-	-	-	1	1	-	-	8 (10%)
Both lobes	1	19	5	-	2	-	-	-	-	-	27 (33.7%)
Total numbers	7	30	26	4	2	1	2	6	1	1	80

**Table 6. Relation between different types of hepatic lesion and its nature**

Type Nature	Malignant primary	Secondary metastasis	Hydatid disease	Abscess	Cystic disease		Tuberculosis	Hemangioma.	Focal fatty disease		Total no.
					Poly.	Simple			Focal fatty spare	Focal fatty infiltration	
Benign	-	-	26	4	2	1	2	6	1	1	43(54%)
Malignant	7	30	-	-	-	-	-	-	-	-	37(46%)

**Table 7. Incidence of the different hepatic lesion according to ultrasonic appearance of the lesion**

Type US Appearance	Malignant primary	Secondary metastasis	Hydatid disease	Abscess	Cystic disease		Tuberculosis	Hemangioma.	Focal fatty disease		Total no.
					Poly.	Simple			Focal fatty spare	Focal fatty infiltration	
Cystic	-	-	20	1	2	1	-	-	-	-	24(30%)
Solid	6	28	6	3	-	-	2	6	1	1	53(66.25%)
Mixed	1	2	-	-	-	-	-	-	-	-	3(3.75%)

\*24cases of the cystic lesion are benign, 53 cases of the solid lesion (19 cases are benign and 34 cases are malignant), 3 cases of mixed lesions are malignant.

**Table 8. Distribution of different solid lesions according to its echogenicity**

Type Echogenicity	Malignant primary	Secondary metastasis	Hydatid disease	Abscess	Tuberculosis	Hemangioma.	Focal fatty disease		Total no.
							Focal fatty spare	Focal fatty infiltration	
Low	2	15	-	2	1	-	1	-	21
High	2	8	2	-	-	6	-	1	19
Heterogeneous	3	7	4	1	1	-	-	-	16

\* 21 cases of the low level lesion (4 cases are benign and 17 cases are malignant), 19 cases of the high level lesion (9 cases are benign and 10 cases are malignant), 16 cases of heterogeneous pattern lesions (6 cases are benign and 10 cases are malignant).

**Table 9. Final diagnosis by CT and US modality**

Type Modality	Malignant primary	Secondary metastasis	Hydatid disease	Abscess	Cystic disease		Tuberculosis	Hemangioma.	Focal fatty disease		Total no.
					Poly.	Simple			Focal fatty spare	Focal fatty infiltration	
US	3	1	17	-*	1	-*	-	2	-*	-*	24
CT	4	7	19	2	2	1	-	6	1	1	43
Undetected + Miss diagnosed	1	6	2	2	1	1	-	4	1	1	19

\* 5 cases undetected by US included 2 cases for each of abscess and focal fatty disease, 1 case for simple cyst.

**Table 10. Final diagnosis by US and biopsy**

Type of lesion Modality	Malignant primary	Secondary metastasis	Hydatid disease	Hepatic Abscess	Tuberculosis	Total no.
US	2	16	6	2	-*	26
Biopsy	3	23	7	2	2	37
Undetected Miss diagnosed	1	7	1	-	2	11

\* 2 cases undetected by US

**Table 11. Percentage of benign and malignant lesions according to the different author**

Author	Year	Total no.	Benign lesion	%	Malignant lesion	%
CF Dietrich <sup>(53)</sup>	2004	174	95	54.6	79	45.4
Tranguart F. <sup>(39)</sup>	2004	90	23	25.5	47	52.2
Alexandra von Herbay <sup>(36)</sup>	2004	126	62	49.2	64	50.8
Ihab R. Kamel <sup>(38)</sup>	2003	237	73	30.8	164	69.2
M. Beissert <sup>(40)</sup>	2002	60	20	33.3	40	66.7
Richard Tello <sup>(36)</sup>	2001	85	53	62.4	32	37.6
The study	2006	80	43	54	37	46

That is shown in Table 8. Out of 80 cases, 48 cases (60%) of the focal lesion show well-defined regular margin while 32/80 (40%) shown an ill-defined margin including 19/32 cases with secondary metastasis, 4/32 cases with primary malignant tumor, 3/32 cases with hydatid disease, 2/32 cases for each of abscess, tuberculosis and 1/32 case for each of focal fatty disease. In 20 cases, there has been thin wall of the lesion including 12/20 cases hydatid disease, 2/20 cases with each of polycystic disease, secondary metastasis, 1/20 case for each of simple cyst, tuberculosis, abscess, hemangioma, while there has been thick wall lesion in 15 cases that included 14/15 cases with hydatid disease and 1/15 case for each of abscess and tuberculosis; with the remaining 45 cases, the wall was undetected.

In 19 cases of focal lesion, there was an internal echoes 13/19 with hydatid disease, 2/19 for each of abscess and primary malignant tumor, 1/19 for each of tuberculosis and secondary metastasis. With 26 cases diagnosed as hydatid cyst, there has been an septation in 15 cases (57.7%) and a daughter cyst in 13 cases (50%) which is an important sign of diagnosis of hydatid cyst; there has also been a calcification within wall of cyst or as whole in 5 cases (19%). From 37 cases that diagnosed as malignant, there has been a halo or target sign in 11 cases (29.7%), 2/11 primary malignant tumor, 9/11 secondary metastasis which is an important sign for malignancy. There has been a posterior acoustic enhancement in 17 cases 12/17 hydatid cyst, 1/17 for each of cystic disease of liver, abscess,

hemangioma, secondary metastasis from adenocarcinoma of bowel.

**Final diagnosis of hepatic lesion:** Among 80 patients examined by US, 43 cases under-went CT scan examination for giving final diagnosis. 24/43 cases were suspected correctly by US which included multiple different lesions. The remaining 19 cases either undetected by US or miss diagnosed as other type of lesion while detected briefly by CT. 5 of 19 cases was undetected by US which included 2 cases for each of abscess, focal fatty disease and 1 case for simple cyst; the remaining 14 of 19 cases that miss diagnosed as other hepatic lesion and diagnosed by CT including secondary metastasis (n= 6), hydatid disease (n= 2), hemangioma (n =4), primary malignant tumor (n=1), polycystic disease (n= 1) this can be shown in Table 9. The remaining 37 cases under-went histopathological examination for final diagnosis (13 of them post surgical operation) . 26 cases from 37 has shown same diagnosis that were suspected by US while the remaining 11 cases have given final diagnosis different from that suspected by US which include secondary metastasis (7) cases, primary malignant tumor (1) case, hydatid disease (1) case; 2 cases undetected by US and detected by biopsy which is tuberculosis as shown in Table 10.

## DISCUSSION

For imaging of the right upper quadrant, US is more widely used than other modalities and for focal hepatic lesion, US is usually the first method used and further evaluation by CT, MRI is required to differentiate between benign and malignant. So in this study an attempt was made to evaluate patients with focal hepatic lesion sonographically whether patient presented clinically or discovered incidentally.

### Regarding the distribution of focal lesion in relation to the sex, different types of the focal lesion was detected

In **cystic disease** Larssen, et al. <sup>(28)</sup> present female involved in 109/174 of patients (63%) while 65/174 of patients (37%) are male. The results of this study are reversed in relation to the sex distribution in which involvement of male by cystic disease in 2/3 of cases (66.7%) while 1/3 of patients (33.3%) in female. In liver abscess Mohsen, et al. <sup>(48)</sup> and Salzono, et al. <sup>(50)</sup> found that male to female ratio is 1.3:1 and 11/16 of cases (68.8%) in male respectively. These finding are similar more or less to the finding of this study in which 4 cases of abscess are in male. In hydatid disease Izadpanah and Saidi <sup>(42)</sup> found that females affected in 27 patients out of 43 (63%) and males is 37%. This study shows that involvement by hydatid disease is more or less similar in about 17/26 of patients (65%) are female while the remaining 35% are male. In hemangioma David, et al. <sup>(23)</sup> on 213 patients found that 127 patients (60%) are female and 86/213 are male (40%), while in this study 4 patients out of 6 (67%) of hemangioma in male and 2 patients out of 6 (33%) in female. This great difference in sex distribution of hemangioma gives some difficulty in the diagnosis. In focal fatty disease Leopoldo Rubaltelli, et al. <sup>(20)</sup>; showed high incidence in male 6/7 of cases (86%) and Shinji Hirohashi, et al. <sup>(32)</sup> found high incidence up to 75% in female. This differs from the finding in this study in which equal distribution of the lesion between both sex 1 case (50%) for each item, this indicates no relation of lesion with sex distribution. In tuberculosis Huang, et al. <sup>(52)</sup> show high prevalence 3/5 of patients (60%) in male

In this study 2 cases of tuberculosis involved in male which is similar to the findings of that study. In malignant tumor Steven, et al. <sup>(32)</sup> showed high difference between female involved 43/76 of patients (57%) in comparison with male involved 33/76 of cases (43%). On the other hand, incidence of malignant involvement in this study will be reverse where involvement of male in 19/37 cases (51%) included secondary metastasis 13/19 and primary tumor 6/19; the remaining 18/37 of patients (49%) are female; that may give an idea in which male is considered one of the risk factor in this study. In this study, the lesion detected in 41 out of 80 patients (51.2%) in male which commonly by malignancy 19/41 while the remaining 39/80 of all patients (48.8%) in female commonly by hydatid disease 17/39 and malignancy 18/39. All these findings are shown in Table 2.

### Regarding the incidence of lesion multiplicity

Basil, et al. <sup>(47)</sup> found simple cyst among 22/60 cases of cystic disease of the liver; about 12/22 of cases (54.5%) are solitary and the remaining 10 are multiple, while the remaining 17/60 cases of cystic disease which are poly cystic disease are multiple. These findings are similar more or less to the results of this study in which, among 3 cases of cystic disease, 2 cases of poly cystic disease are multiple and 1 case of simple cyst is single, which is an important feature as a key to facilitate US diagnosis. In 2 studies done by Mohsen, et al. <sup>(48)</sup> and Zibari, et al. <sup>(49)</sup> abscess is shown as a single lesion in 41/69 (59%), 14/20 (70%) respectively, which is similar more or less to the findings of this study; 4 cases of abscess presented as a single lesion. This specificity of solitary abscess gives a wide range of differential diagnosis of abscess sonographically. In a study done by Suwan <sup>(41)</sup>; he found multiplicity of hydatid disease 13/62 of all cases (21%), while in this study the incidence will be so higher in comparison with the Suwan study in which 15/26 cases (58%) with hydatid disease and the remaining 11/26 cases are single lesion. This high incidence of multiple lesions hydatid disease makes it an important sign for suspected lesion but without specificity in relation to lesion which puts it as differential diagnosis to the other lesion as malignancy.

Two studies done by Glinkova, et al. <sup>(30)</sup> and David , et al. <sup>(23)</sup> show that most of hemangioma 56/94 (60%) and 171/213 (80%) respectively presented as single lesion; that is completely different from the results of this study in which 4/6 (66.7%) cases of hemangioma found to be as multiple lesion while the remaining 2/6 (33.3%) of the cases are found to be single. This multiplicity gives some sort of difficulties in the diagnosis of lesion by US and gives a wide range of differential diagnosis. Leopoldo Rubaltelli, et al. <sup>(20)</sup> show single lesion of focal fatty disease in all 7 patients which is similar to the findings of this study, in which 2 cases of focal fatty disease of the liver found to be a single lesion that increases difficulty of US in lesion diagnosis. Hung, et al. <sup>(52)</sup> have found single lesion of tuberculosis in 4/5 (80%) and multiple in 1/5 (20%), while in this study, among 2 cases of tuberculosis, we have found single lesion in 1 case (50%) and multiple in the others. This different incidence makes tuberculosis undiagnosed by US unless confirmed by histopathology. Study done by Ihab, et al. <sup>(38)</sup> found that among multiple lesion in 77 patients, 68 cases (88.3%) with malignancy (61 cases with secondary and 7 cases with hepatocellular carcinoma). This study shows that the incidence of multiple malignant lesions is lower than Ihab study in which

24/37 cases (65%) with malignancy (23 cases with secondary and 1 case with primary malignant tumor), the remaining malignant lesions (13/37) cases are single. This study shows that multiplicity of the lesion in 46/80 of cases (57.5%) is of high prevalence than single lesion which is in 34/80 of cases (42.5%) commonly by hydatid disease and malignancy that findings showing in Table 4.

#### Regarding the involvement lobes of the liver

According to the cystic disease of liver Sanchez, et al.<sup>(46)</sup> found that polycystic liver disease is bilobar with 2 of 11 cases (18%) predominantly in right lobe while simple cyst is predominantly in the right lobe in about 10 of 12 cases (83%). This study shows similar findings; among 3 cases of cystic disease, 2 of them which are polycystic involved both lobes and 1 of them which is simple cyst involved right lobe. Among liver abscess Abdelouafi, et al.<sup>(51)</sup> show involvement of the right lobe in all 32 cases that is similar to the results of this study in which 4 cases of abscess involved in right lobe. A study done by Michael Safioleas, et al.<sup>(43)</sup> found that 68 from 132 patients (51.5%) of hydatid disease involved right lobe and 31 of 132 cases (23.5%) involved left lobe while the remaining 14 cases (10.6%) involved both lobes. This is similar more or less to the results of this study in involving of the right lobe by hydatid disease which is 17/26 cases (65.4%) while it shows a great difference in involving left lobe which is 4 of 26 cases (15.4%) and is higher in involving both lobes which is 5 of 26 cases (19.2%). There is no scientific explanation for this different distribution of hydatid disease within liver lobes.

In hemangioma Glinkova, et al.<sup>(30)</sup> found right lobe involvement in 128/181 cases (70.8%) while left lobe involvement is 11/181 of all cases (6%) and the remainder 42 cases (23.2%) involved both lobes. This study shows more or less similarity in which 5 of 6 cases of hemangioma (83%) involved right lobe and the remaining 1 case (17%) involved left lobe. Two studies by Leopoldo Rubaltelli, et al.<sup>(20)</sup> and Shinji Hirohashi, et al.<sup>(22)</sup> found focal fatty disease lesion in 7 cases and in 8 cases respectively in left lobe which is completely different from the results of this study in which 2 cases of focal fatty disease found in right lobe which is unusual site for it, that lead to easily miss diagnosis of the lesion by US. For tuberculosis Hung, et al.<sup>(52)</sup> found lesion in 4/5 of cases (80%) in left lobe while 1/5 cases (20%) in both lobes. This study shows great difference in which 1 of 2 cases (50%) of tuberculosis involved each lobe.

Ihab, et al.<sup>(38)</sup> found right lobe involvement by hepatic tumor about 160/237 of cases (67.5%) and 68/237 cases (28.7%) were found in left lobe and 9/237 cases (3.8%) in both lobes. This study shows great difference of involvement of the right lobe by malignancy. Among 37 cases of malignancy, 15 cases (40.5%) have involved right lobe (10 with secondary metastasis and 5 with primary malignant tumor) while 2 cases of 37 patients (5.4%) have involved left lobe (1 for each of secondary metastasis and primary malignant tumor) which is unusual site. The remaining 20/37 cases (54.1%) have involved both lobes (19 with secondary metastasis and 1 with primary). This high prevalence of both lobes involvement by malignancy may be due to delay diagnosis of malignancy and discovery after wide dissemination or may be due to rapid growth of malignancy by genetic mutation in our patients in the last 2 decades of time due to highly exposure to the radiation after wars. It has been found that most of the hepatic lesion located

in right lobe 45/80 of cases (56.3%) while left lobe is little involved about 8/80 of cases (10%) both commonly involved by hydatid disease while involving both lobes in about 27/80 of cases (33.7%) commonly by malignancy. This is shown in Table 5.

#### Regarding the nature of lesion

Richard Tello, et al.<sup>(37)</sup> found 32 cases of 85 (37.6%) are malignant which are metastasis (n= 30) and HCC (n= 2). The remaining 53 cases of 85 (62.4%) are benign which are hemangioma (n= 37), cysts (n= 15), focal nodular hyperplasia (n= 1). Alexandra, et al.<sup>(36)</sup> showed that 62/126 of cases (49.2%) are benign including hemangioma (29), focal steatosis (7), regenerative nodules (13), adenoma (4), focal nodular hyperplasia (9). While 64/126 of cases (50.8%) are malignant including metastasis (25) and HCC (36), cholangiocarcinoma (1), non Hodgkin Lymphoma (2). Dietrich, et al.<sup>(53)</sup> found that 79 of 174 cases (45.7%) are malignant which are secondary metastasis (37), HCC (33), cholangiocarcinoma (4), lymphoma (4) and hemangioendotheliosarcoma (1). The remaining 95 of 174 cases (54.6%) are benign which are focal nodular hyperplasia (36), hemangioma (31), adenoma (10), microhamartoma (4), abscess (5), focal fatty infiltration (4), 1 case for each of 5 different lesions. This study shows that 43 out of 80 patients (54%) are benign lesion including hemangioma (n=6), hydatid cyst (n=26), abscess (n=4), cystic disease (n=3), tuberculosis (n=2), focal fatty disease (n=2); the remaining 37 cases (46%) are malignant including secondary metastasis (n=30) and hepatoma (n= 7). These findings are more or less similar to Dietrich study but differ from other two studies that are shown in Table 6.

#### Regarding US appearance of the lesion

Among cystic disease of liver, Basil, et al.<sup>(47)</sup> found that 17 cases out of 60 patients with polycystic and 22 out of 60 cases with simple cyst had cystic appearance, while the findings of this study indicate that among 3 cases of cystic disease, 2 cases with polycystic disease and 1 case with simple cyst have a cystic appearance which are completely similar finding. Abdelouafi et al.<sup>(51)</sup> found cystic appearance of abscess in 1 out of 32 cases (3%) while the remaining 31 are solid which are similar to the finding of this study in which 1 case (4%) is cystic and the remaining 3 cases are solid. Two studies by Shambesh MA, et al.<sup>(45)</sup> and Cohen, et al.<sup>(44)</sup> found that cystic nature of hydatid disease is 170/233 (73%), 45/64 (71%) cases respectively while solid hydatid disease was found in 5.6% and 63% respectively which is similar more or less to the finding of this study, regarding cystic hydatid disease which found in 20/24 of all cases (83%) while it differ from that found by two studies in regarding to solid hydatid disease which found in 6 out of 53 cases (11%) that give some difficulty in diagnosis of solid hydatid disease. Steven, et al.<sup>(32)</sup> found solid appearance of hemangioma in 5 out of 56 patients (9%); in this study it has been found that solid appearance of hemangioma is found in 6/53 of all cases (11%). This shows similar more or less finding in regarding to the hemangioma. Shinji Hirohashi, et al.<sup>(22)</sup> found that among 202 patients, 8 cases (4%) of focal fatty disease are solid. In comparison to the findings of this study, 2 cases of 53 (4%) are found to be solid which is a similar finding. Hung, et al.<sup>(52)</sup> found tuberculosis solid lesion in 5/31 (16%). In comparison with this study, there is a great difference in which tuberculosis solid lesions found in 2 cases of 53 (4%).



Steven, et al.<sup>(32)</sup> found solid appearance of secondary metastasis in 18 out of 56 patients (32%) in comparison with this study that found solid nature of secondary metastasis in 28 of 53 cases (53%) while solid primary malignant tumor in 6/53 (11%). That shows a different incidence between 2 studies in relation to malignancy. Finally, a study by Marcello Caremani, et al.<sup>(7)</sup> described cystic lesion in 36/71 (51%) which are benign in 24 cases and malignant in 12 cases while solid lesion found in 35/71 (49%) which are benign in 20 cases and 15 cases are malignant. This study has depicted solid lesion sonographically in 53/80 (66.25%) which has malignant nature in 34/53 (43%) while the remaining 19 are benign, while cystic lesion has been found in 24/80 (30%) which show benign nature as whole. The remaining 3/80 cases (3.75%) are mixed pattern which are malignant cases. This will show high prevalence of malignancy in our hospitals mostly solid lesion that is shown in Table 7.

### Regarding the echogenicity of lesion

Abdelouafi, et al.<sup>(51)</sup> found hypoechoic abscess about 22/32 of cases (67%) while heterogeneous appearance in 9/32 cases (28%). It has been found in this study hypoechoic abscess in 2 of 3 cases (66.7%) and heterogeneous abscess in 1 of 3 cases (33%) which is more or less similar to the findings of that study. Suwan<sup>(41)</sup> found an echogenic solid hydatid disease in 6/62 of cases (10%). This study shows echogenic hydatid disease in 2/26 of cases (8%) and the remaining 4 cases are heterogeneous appearance which are more or less similar findings. Glinkova, et al.<sup>(30)</sup> found hyperechoic hemangioma in 161/181 (88.9%); the remaining 16 cases and 4 cases are heterogeneous and hypoechoic appearance respectively. This study shows that the 6 cases of hemangioma are hyperechoic. Shinji Hirohashi, et al.<sup>(22)</sup> found hypoechoic focal fat in 4 of 8 cases (50%) while hyperechoic lesion in other 4 cases. This study shows 1 of 2 cases (50%) of focal fat with each of hypo and hyperechoic lesion which is similar findings to that study. Hung, et al.<sup>(52)</sup> found hypoechoic tuberculosis in 4 of 5 cases (80%) and hyperechoic lesion in 1 of 5 cases (20%). It has been found in this study that there is hypoechoic tuberculosis in 1 of 2 cases (50%) and heterogeneous appearance in 50% which shows great difference according to the percentage and appearance of the tuberculosis giving wide range of differential diagnosis.

Steven, et al.<sup>(32)</sup> found that 18 out of 56 cases (32%) of intermediate lesion are secondary metastasis which shows a variety of echogenicity among hypochoic, hyperechoic and heterogeneous. This study shows that among 37 cases of malignancy, 17 cases are hypochoic (2 with primary malignant tumor and 15 with secondary metastasis), 10 cases are hyperechoic (2 with primary and 8 with secondary) and 10 cases are heterogeneous (3 with primary and 7 with secondary). In this study, low echogenic lesion detected in 21 of 56 cases of solid lesion (37.5%) which is 17 with malignancy and 4 with benign. While 19 cases of 56 (33.9%) are high echogenic which are 10 with malignancy and 9 with benign. The remaining 16 cases of 56 (28.6%) are heterogeneous lesion which is 10 with malignancy and 6 with benign. This shows malignant lesion presented with any form and may similar to benign lesion that is shown in Table 8.

### Regarding the associated features

The study by Suwan<sup>(41)</sup> found internal echoes within hydatid cyst in 14/62 (23%) which is lower than that finding in this study in which 13/26 (50%) cases of hydatid disease are internal echoes within cystic lesion. Shambesh MA., et al.<sup>(45)</sup> found Septation within cystic hydatid lesion in 79/233 cases (34%) which is lower than that found in this study which is 15/26 of cases (57.7%). Two studies by Marcello Caremani, et al.<sup>(7)</sup> and Izadpanah, et al.<sup>(42)</sup> found a daughter cyst in 31 cases (43.75%) of hydatid disease and 21/43 of cases (49%) respectively. This study shows 13/26 of hydatid disease (50%) with daughter cyst. Shambesh MA, et al.<sup>(45)</sup> and Suwan<sup>(41)</sup> found Calcification within hydatid cyst in (13.2%) of 233 cases and (16%) of 62 cases respectively. This study shows calcification within 5 of 26 cases (19%). All these features are important for diagnosis of hydatid disease. Marcello Caremani, et al.<sup>(7)</sup> detected thick wall lesion in 22/71 cases (31%), 18 with hydatid disease and 4 with non parasitic disease, while this study shows thick wall lesion in 15 of 80 cases (19%) which are 14 for hydatid disease and 1 case for non parasitic lesion. While thin wall lesion is found in 20 of 80 cases (25%), 12/20 among hydatid disease and 8/20 among non parasitic lesion, the remaining 45 lesion show undetected wall. A study by Marcello Caremani, et al.<sup>(7)</sup> found posterior enhancement in (54/71) cases (76%) which is in 26/31 cases of hydatid disease and in 28/40 cases with non parasitic lesion. This study shows posterior acoustic enhancement in 17 cases of 80 (21%) which included 12 cases with hydatid disease and 5 cases with non parasitic lesion.

### CONCLUSION

Despite the limited numbers of patients, this study has shown that the US imaging is generally considered a reliable, cheap and readily available modality which is commonly used to evaluate patients with wide variety of suspected hepatic abnormality. The results has indicated that most of the hepatic focal lesion can be detected and characterized on hepatic sonography as a first diagnostic method. Ultrasound is considered the imaging modality of choice in detecting and diagnosing cystic lesions adequately especially hydatid disease while it has a slight limitation in diagnosing solid lesions correctly as the only imaging which are commonly malignant nature. Regarding 43 cases of benign nature, the hydatid disease are more common lesions which diagnosed correctly by US in 65% while regarding 37 cases of malignant nature, the secondary metastasis are more common lesions which diagnosed correctly by US in 59%.

### REFERENCES

1. Carol A. Mittelstaedt. General Ultrasound, Chapter 5 Edward G. Grant. Liver: Normal Anatomy. Churchill Livingstone New York, Edinburgh, London, Melbourne, Tokyo; 1992. P.173-184.
2. Hisham Tehelepi and Phillip W. Ralls. Ultrasound of focal liver masses. Ultrasound Quarterly 2004; 20(4): 155-169.
3. Duan Li and Lucy E. Hann. A practical approach to analyzing focal lesions in the liver. Ultrasound Quarterly 2005; 21(3): 187-200.
4. A K P LIM, N PATEL, W M W GEDEROYC, M J K BLOMLEY, G HAMILTON and S D TAYLOR-ROBINSON. Hepatocellular adenoma: diagnostic difficulties and novel imaging techniques. The British journal of radiology 2002; 75: 695-699.

5. Junsung Choi. Imaging of hepatic metastasis: imaging focal liver lesions is critical in the diagnosis, treatment, and follow-up of patients with hepatic metastasis. *Cancer Control* 2006; 13(1): 6-12.
6. Paula Rhodes, Sharon Aranda. Polycystic Liver Disease. *Journal Of Diagnostic Medical Sonography* 2004; 20 (3): 182-185.
7. Marcello Caremani, Laura Lapini, Daniela Caremani, Ubaldo Occhini. Sonographic diagnosis of hydatidosis : the sign of the cyst wall. *European Journal of Ultrasound* 2003; 16: 217-223.
8. B. Gloor, Q. Ly, D. Candinas. Role of Laparoscopy in Hepatic Cyst Surgery. *Digestive Surgery* 2002; 19: 494-499.
9. M Azeemuddin, T UI-Haq, H Ahsan, W A Memon. Clinics in diagnostic imaging (102). *Singapore Med J* 2005;46(2): 93-99.
10. M Muttarak, W C G Peh, B Chaiwan. Clinics in Diagnostic Imaging (48). *Singapore med. J* 2000; 41(4): 193-197.
11. Michelle V Lisgaris and Robert A Salata. Liver abscess. *E.medicine* 2005; 24:1-33.
12. A Hagiwara, Y Inoue, T Shutoh, H Kinoshita, and K Wakasa. Haemorrhagic. Case report, Haemorrhagic hepatic cyst: A differential diagnosis of cystic tumour. *British Journal of Radiology* 2001; 74 :270-272.
13. V. Javier Casillas, Marco A. Amendola, Ana Gascue, Nat Pinnar, Joe U. Levi, and Juan Manuel Perez. Imaging of Nontraumatic Hemorrhagic Hepatic Lesions. *Radiographics*. 2000;20:367-378.
14. Srinivasa Prasad, Dushyant Sahani, Sanjay Saini. Cavernous Hemangioma, Liver. *E.medicine* 2003; 16: 1-14.
15. Luigi Grazioli, Michael P. Federle, Giuseppe Brancatelli, Tomoaki Ichikawa, Lucio Olivetti and Arye Blachar. Hepatic Adenomas: Imaging and Pathologic Findings *Radiographics*. 2001;21:877-892.
16. Korobkin M, Stephens DH, Lee JKT, et al. Biliary cystadenoma and cyst aenocarcinomas : CT and sonographic findings. *AJR Am J Roentgenol*. 1989; 153:507-511.
17. Christian Görg, Tillmann Bert. Pictorial Review: Sonographic Patterns of Diffuse and Focal Fatty Infiltration of the Liver: Differential Diagnosis to Metastatic Liver Disease. *Onkologie* 2005;28:659-664.
18. Marchelle J. Bean, Karen M. Horton, and Elliot K. Fishman. Concurrent Focal Hepatic and Splenic Lesions: A Pictorial Guide to Differential Diagnosis. *J Comput Assist Tomogr* 2004;28:1-11.
19. F. Pons and J.M. Llovet. Approaching focal liver lesions. *Rev Esp Enferm Dig* 2004; 96 (8): 567-577.
20. Leopoldo Rubaltelli, Sergio Savastano, Yeganeh Khadivi, Roberto Stramare, Alberto Tregnaghi and Pierpaolo Da Pian. Original Report, Targetlike Apperance of Psedotumors in Segment IV of the Liver on Sonography. *American Journal of Roentgenology* 2002; 178: 75-77.
21. Benedikt V. Czermak, Karin M. Unsinn, Thaddeus Gotwald, Peter Waldenberger, Martin C. Freund, Reto J. Bale, et al. Pictorial Essay, Echinococcus multilocularis Revisited. *American Journal of Roentgenology* 2001; 176: 1207-1212.
22. Shinji Hirohashi, Kouji Ueda, Hideo Uchida, Wataru Ono, Junko Takahama, Megumi Takewa, et al. Nondiffuse Fatty Change of the Liver: Discerning Pseudotumor on MR Images Enhanced with Ferumoxides-Initial Observations . *Radiology*. 2000;217:415-420.
23. David M. Leifer, Willam D. Middleton, Sharlene A. Teefey, Christine O. Menias and John R. Leahy. Follow-up of Patients at Low Risk for Hepatic Malignancy with a Characteristic Hemangioma at US. *Radiology* 2000; 214: 167-172.
24. Iván Pedrosa, Antonio Saíz, Juan Arrazola, Joaquín Ferreirós, and César S. Pedrosa. Hydatid Disease: Radiologic and Pathologic Features and Complications. *Radiographics*. 2000;20:795-817.
25. Daniel A. Merton. Contrast-Enhanced Hepatic Sonography. *Journal of Diagnostic Medical Sonography* 2002; 18 (1): 5-15.
26. Thomas Alberecht, Martin J.K. Blomley, Peter N. Burns, Stephanie Wilson, Christopher J. Harvey, Edward Leen, et al. Improved Detection of Hepatic Metastases with Pulse-Inversion US during the Liver-specific Phase of SHU 508A: Multicenter Study. *Radiology* 2003; 227: 361-370.
27. Sara Badvie. Review, Hepatocellular carcinoma. *Postgrad Med J* 2000;76:4-11 .
28. T.B. Larssen, J. Rorvik, S.R. Hoff, A. Horn, K. Rosendahl. The occurrence of asymptomatic and symptomatic simple hepatic cysts. A prospective, hospital-based study. *Clinical Radiology* 2005; 60: 1026-1029.
29. Ihab R. Kamel, and David A. Bluemke. Imaging Evaluation of Hepatocellular Carcinoma. *Journal of Vascular and Interventional Radiology* 2002; 13: 173-184.
30. V Glinkova, O Shevah, M Boaz, A Levine and H Shirin. Hepatic haemangiomas: possible association with female sex hormones. *Gut* 2004; 53:1352-1355.
31. Koenraad J. Mortelé and Pablo R. Ros. Cystic focal liver lesions in the adult: differential CT and MRI imaging features. *Radiographics*. 2001; 21: 895-910.
32. Steven C. Eberhardt, Patricia H. Choi, Ariadne M. Bach, Stacey A. Funt, Howard E. Felderman, BA and Lucy E. Hann. Utility of Sonography for Small Hepatic Lesions Found on Computed Tomography in Patients With Cancer. *J Ultrasound Med* 2003; 22: 335-343 .
33. Sharlene A. Teefey, Charles C. Hildboldt, Farrokh Dehdashti, Barry A. Siegel, Marion G. Peters, Jay P. Heiken, et al. Detection of Primary Hepatic Malignancy in Liver Transplant Candidates: Prospective Comparison of CT, MR Imaging, US and PET. *Radiology* 2003; 226: 533-542.
34. Valerie Byrnes, Andrés Cárdenas, Nezam Afdhal, Douglas Hanto. Symptomatic focal nodular hyperplasia during pregnancy: A case report. *Annals of Hepatology* 2004; 3 (1): 35-37.
35. Carl M. Bloom, Bernard Langer and Stephanie R. Wilson. Role of US in the Detection, Characterization, and Staging of Cholangiocarcinoma. *Radiographics*. 1999;19:1199-1218.
36. Alexandra von Herbay, Christoph Vogt, Reinhard Willers and Dieter Häussinger. Real-time Imaging With the Sonographic Contrast Agent SonoVue: Differentiation Between Benign and Malignant Hepatic Lesions. *J Ultrasound Med* 2004; 23: 1557-1568.
37. Richard Tello, Helen M. Fenlon, Todd Gagliano, Victor L. S. deCarvalho and E. Kent Yucel. Prediction Rule for Characterization of Hepatic Lesions Revealed on

- MR Imaging American Journal of Roentgenology 2001; 176:879-884.
38. Ihab R. Kamel, Michael A. Choti, Karen M. Horton, H. J. V. Braga, Bernard A. Birnbaum, Elliot K. Fishman, et al. Surgically Staged Focal Liver Lesions: Accuracy and Reproducibility of Dual-Phase Helical CT for Detection and Characterization. *Radiology* 2003;227:752-757.
  39. Tranquart F, Bleuzen A, Kissel. A. Value of combined conventional and contrast enhanced sonography in the evaluation of hepatic disorders. *Journal of Radiology* 2004;85:755-62.
  40. M. Beissert, S. Delorme, S. Mutze, W. R. Lees, M. L. Bahner, S. Filimonow, et al. Comparison of B-Mode and Conventional Colour/Power Doppler Ultrasound, Contrast-Enhanced Doppler Ultrasound and Spiral CT in the Diagnosis of Focal Lesions of the Liver: Results of a Multicentre Study. *Ultraschall Med* 2002; 23: 245-250.
  41. Suwan Z. Sonographic findings in hydatid disease of the liver: comparison with other imaging methods. *Ann Trop Med Parasitol.* 1995;89 (3):261-9.
  - A. Izadpanah, F. Saidi. Asymptomatic Liver Hydatid cysts; a Preferred Approach . *Iran Journal Med Sci* 2006; 31(3): 21-124.Ori
  42. Michael Safioleas, Evangelos Misiakos, Christine Manti, Demetrios Katsikas and Gregory Skalkeas. Diagnostic evaluation and surgical management of hydatid disease of the liver. *World Journal of Surgery* 1994; 18 (6) : 859-865.
  43. Cohen H, Paolillo E, Bonifacino R, Botta B, Parada L, Cabrera P, et al. Human cystic echinococcosis in a Uruguayan community: a sonographic, serologic, and epidemiologic study. *Am J Trop Med Hyg.* 1998;59(4):620-7.
  44. Shambesh MA, Craig PS, Macpherson CN, Rogan MT, Gusbi AM and Eghtuish EF. An extensive ultrasound and serologic study to investigate the prevalence of human cystic echinococcosis in northern Libya. *American Journal of Tropical Medicine and Hygiene.* 1999;60(3):462-8.
  45. Sanchez H, Gagner M, Rossi RL, Jenkins RL, Lewis WD, Munson JL, et al. Surgical management of nonparasitic cystic liver disease. *American Journal of Surgery.* 1991;161(1):113-8.
  46. Basil J. Ammori, Benjamin L. Jenkins, Phillip C.M. Lim, K. Rajendra Prasad, Stephen G. Pollard and J. Peter A. Lodge. Surgical Strategy for Cystic Diseases of the Liver in a Western Hepatobiliary Center. *World Journal of Surgery* 2002; 26(4): 462-469.
  47. A.H. Mohsen<http://qjmed.oxfordjournals.org/cgi/content/full/95/12/797#FNC1>, S.T. Green, R.C. Read and M.W. Mckendrick. Liver abscess in adults: ten years experience in a UK centre. *An International Journal of Medicine* 2002; 95(12): 797-802.
  48. Zibari GB, Maguire S, Aultman DF, McMillan RW, McDonald JC. Pyogenic liver abscess. *Surg Infect* 2000;1(1):15-21.
  49. Salzano A, Rossi E, Carbone M, Mondillo F, De Rosa A, Tuccillo M, et al. Suburban amebiasis: the diagnostic aspects via computed tomography and echography and the percutaneous treatment of amebic liver abscesses. *Radiol Med* 2000;99(3):169-73.
  50. Abdelouafi A, Ousehal A, Ouzidane L, Kadiri R. Ultrasonography in the diagnosis of liver abscesses. Apropos of 32 cases. *Ann Radiol* 1993;36(4):286-92.
  51. W-T Huang, C-C Wang, W-j Chen, Y-F Cheng and H-L Eng. The nodular form of hepatic tuberculosis: a review with five additional new cases. *Journal of Clinical Pathology* 2003;56:835-839.
  52. C F Dietrich, A Ignee, J Trojan, C Fellbaum and G Schuessler. Improved characterisation of histologically proven liver tumours by contrast enhanced ultrasonography during the portal venous and specific late phase of SHU 508A. *Gut* 2004;53:401-405.

\*\*\*\*\*