



ISSN: 0975-833X

Available online at <http://www.journalcra.com>

International Journal of Current Research
Vol. 12, Issue, 01, pp.9292-9294, January, 2020

DOI: <https://doi.org/10.24941/ijcr.36772.01.2020>

INTERNATIONAL JOURNAL
OF CURRENT RESEARCH

RESEARCH ARTICLE

KERATOCYTTIC ODONTOGENIC TUMOR, A CASE REPORT WITH CBCT FINDINGS AND ONE YEAR FOLLOW UP

^{1,*}Dr. Munish Kumar, ²Dr. Sweta Choudhary, ³Dr. Sunny Kala and ⁴Dr. Mamta Sharma

¹MDS, Reader, SGT University, Gurugram, Haryana, India

²MDS, SGT University, Gurugram, Haryana, India

³MDS, Sr. Resident, AIIMS Delhi, India

⁴PG student, PDM dental college, Bahadurgarh, Haryana, India

ARTICLE INFO

Article History:

Received 15th October, 2019

Received in revised form

18th November, 2019

Accepted 09th December, 2019

Published online 30th January, 2020

Key Words:

Keratocytic Odontogenic Tumor,
CBCT, One year Follow up, Parakeratinized.

ABSTRACT

We are presenting a case report of Keratocytic Odontogenic Tumor in mandible with pre-operative CBCT finding, Histopath and Surgical treatment followed by one year follow up and post-operative CBCT findings. The case was managed by surgical enucleation along with chemical cauterization using Carnoy's solution. Histopath was done and it was found parakeratinized stratified squamous cystic lining. Case was followed up after 3 months, 6 months, 9 months and one year and found uneventful and CBCT was done after one year which shows decreased size and extent of bone defect and signs of good healing with evidence of bone remodeling. Hence we conclude that multidisciplinary approach is required for diagnosis and management of Keratocytic Odontogenic Tumor.

Copyright © 2020, Munish Kumar et al. This is an open access article distributed under the Creative Commons Attribution License, which permits unrestricted use, distribution, and reproduction in any medium, provided the original work is properly cited.

Citation: Dr. Munish Kumar, Dr. Sweta Choudhary, Dr. Sunny Kala and Dr. Mamta Sharma. 2020. "Keratocytic Odontogenic Tumor, A case report with CBCT findings and one year follow up.", *International Journal of Current Research*, 12, (01), 9292-9294.

INTRODUCTION

CBCT is a 3D imaging dental facility which has gained popularity in last decade and helping the dentist to get 3D view of the anatomy and giving an edge in diagnosis by showing any cortical expansions, involvement of the anatomical structures and other useful information however in the case of Keratocytic Odontogenic Tumor CBCT gives an appearance of multilocular lesion which mimics other anomalies also hence histopathological evaluation is required for giving a definitive diagnosis. We hereby presenting a case report of Keratocytic Odontogenic Tumor with pre-operative CBCT, histopathology and post-operative CBCT managed by surgical enucleation along with chemical cauterization with Carnoy's solution.

CASE REPORT

A 35 year old female, reported with swelling in the right side of face and discomfort in the same. Pt. was asymptomatic one year ago after which she started experiencing swelling in the right side of face which gradually increased. There is no pain associated with the swelling. Patient medical history was negative for other conditions.

Oral examination revealed unilateral swelling of the right side mandible, of hard consistency with crepitus in the area of swelling. Tenderness was present on deep palpation, with no point of fluctuation, no purulent discharge, on the distal surface of tooth no. 47, and 48 found to be clinically missing, for which pt. gave a history of uneventful extraction 2 years ago. The extent of the buccal bulge was from the right mandibular ramus to the coronoid region. OPG (Figure 1) was done as scout radiograph and revealed a unilocular, large radiolucent area extending from the distal aspect of tooth no. 47 superiorly involving mandibular ramus till coronoid, mandibular notch and neck of condyle. CBCT was advised for further evaluation and 3D evaluation of the lesion using Kodak CS9300 Extraoral Imaging System, USA. CBCT revealed A large unilocular, non expansile, radiolucency affecting the right posterior body, angle and ascending ramus of the mandible. The lesion extends from the distal surface of tooth 47 involving ramus superiorly the sigmoid notch/neck of the condylar head and antero-posteriorly extended from the anterior border of the ramus upto the posterior border (Fig. 2) of size : 32.15 mm X 13 mm X 40.5 mm (S-I; B-L; A-P). The lesion is irregular, partially corticated with radiolucent internal structure. Lesion was effecting the adjoining structures revealing loss of the superior cortical margin of the IAC was noted in many sections w.r.t angle and ramus of mandible.

***Corresponding author:** Dr. Munish Kumar,
MDS, Reader, SGT University, Gurugram, Haryana, India.

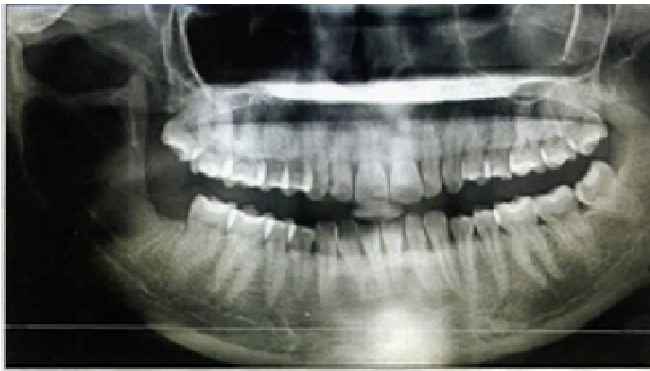

Figure 1. OPG revealing large unilocular lesion in right mandible

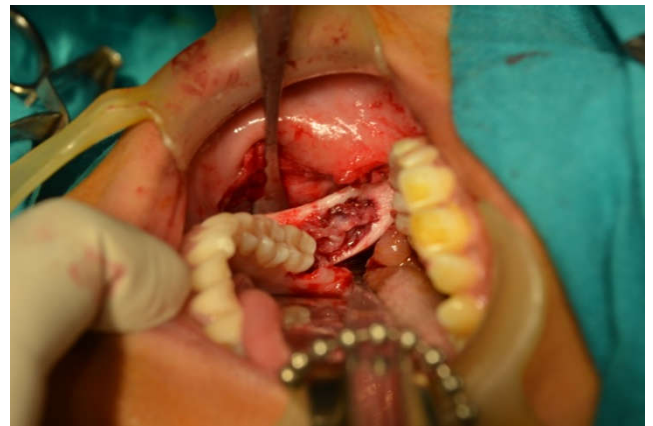


Figure 3. Intra operative

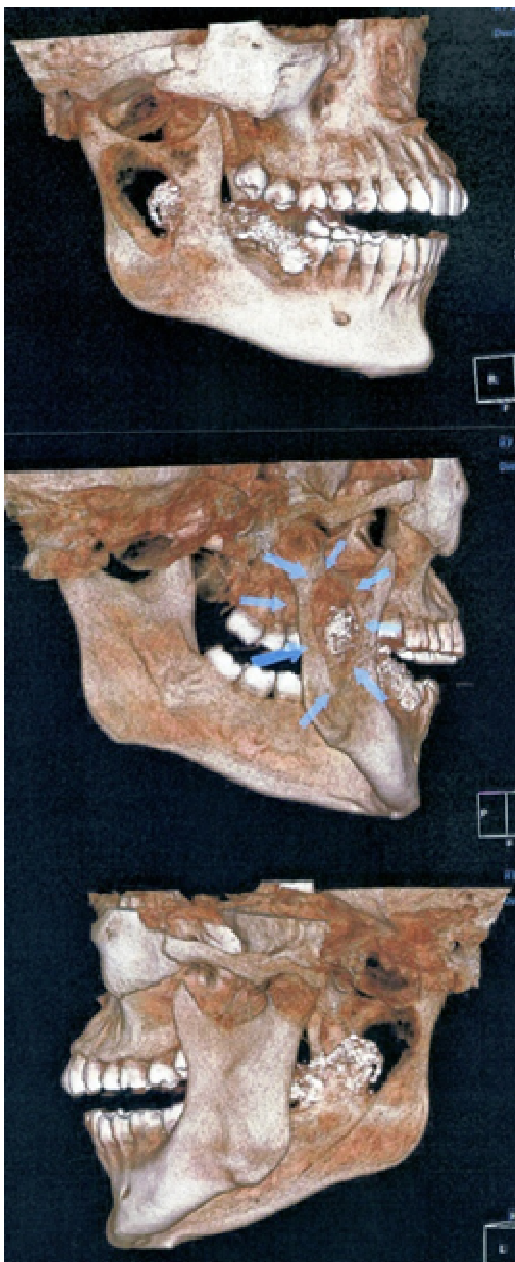


Figure 2. Pre op CBCT images

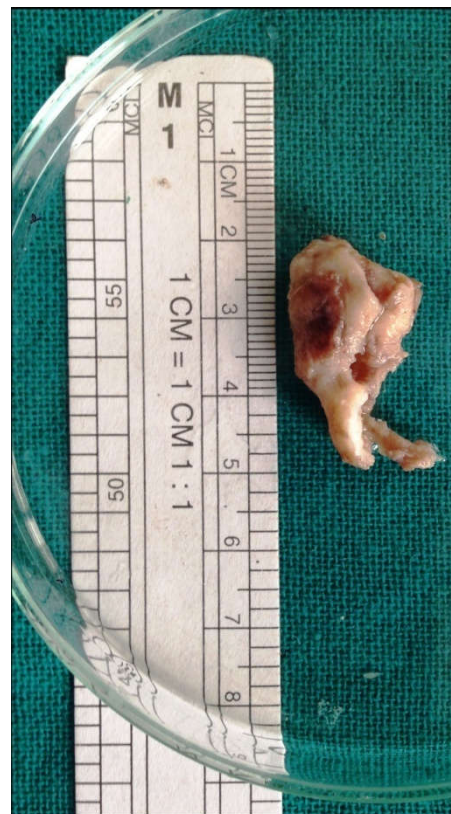

Figure 4. Biopsy specimen

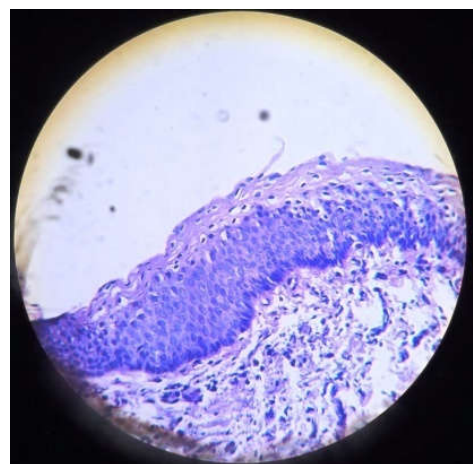


Figure 5. Histopathology

Thinning of cortical bone was noted in many sections, discontinuity of the buccal and lingual cortical plates i.r.t ramus was visualized, loss of crestal cortical bone w.r.t tooth 48 region was seen. Borders of sigmoid notch were found to be intact.

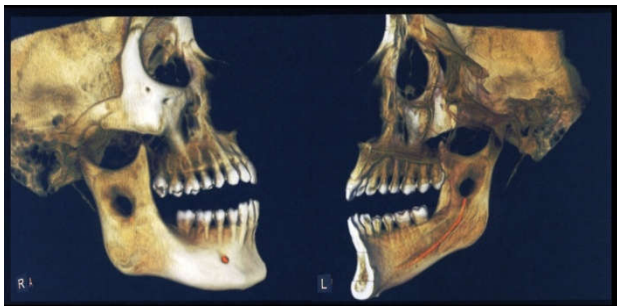


Figure 6. Post operative CBCT

Findings are constant with a P/D of Keratocystic odontogenic tumour (OKC). Looking at the extent of lesion enucleation along with chemical cauterization with Carnoy's solution was planned under general anesthesia using standard aseptic protocols. Incision was started in the buccal vestibule and continued upto distal of second molar and further along the anterior border of ramus. Mucoperiosteal flap was raised to expose the bony defect (Fig. 3). The cyst lining was identified and removed. After enucleation peripheral ostectomy followed by chemical cauterization using Carnoy's solution was done. Care was taken to prevent damage to IAN. The specimen was sent for histopathologic examination (Fig. 4).

Histopathological Examination (Fig. 5) revealed 4-8 cell layer of parakeratinised stratified epithelium with flat connective tissue epithelial interface. Nuclei of basal cell of epithelium are arranged in palisaded manner. Surface corrugations present on surface layer of epithelium. Surrounding connective tissue is infiltrated by mild inflammatory infiltrate in loose connective tissue stroma. Follow up was done after 3 months, 6 months, 9 months and one year which was found to be uneventful and CBCT was done after one year. Post operative CBCT revealed focal solitary well defined round to ovoid osteolytic bone defect noted in middle third of right ramus region measuring 9.3 mm x 5.3 mm x 10.45 mm (S-I; B-L; A-P). Post operative changes in the form of numerous small condensed new bone trabeculae are noted at the periphery of the osseous defect in-situ. Findings are suggestive of normal post-operative healing and remodeling with decrease in the size of the osseous defect. (Fig. 6)

DISCUSSION

The term Odontogenic keratocyst was first used by Philipsen in 1956 (Auluck, 2006). This relatively uncommon lesion arises from the cell rests of dental lamina. This is highly aggressive odontogenic origin cyst with rapid growth and tendency to invade adjacent structures. It has a high rate of recurrence (Woolgar, 1987). It is commonly seen in the posterior part of the mandible but can occur anywhere in the jaw. Since the clinical features and radiological appearance are not characteristic this condition is commonly misdiagnosed. This is more so when the lesion is related to the non-vital tooth. Odontogenic keratocyst has been recoinced as keratocystic odontogenic tumor by WHO working group in 2005. So it was necessitated to differentiate this form of lesion from its orthokeratinizing variant which is considered as odontogenic keratocyst. The term keratocystic odontogenic tumor was necessitated because of the aggressive biological behavior of the lesion and associated chromosomal and genetic abnormalities which was consistent with neoplastic progression.

Essential histological criteria for the diagnosis of keratocystic odontogenic tumor which helped in differentiating parakeratinizing type from orthokeratinizing type (Worrall, 1992). Histologic features include: cyst lining uniformly distributed around the lesion, Presence of hyperchromatic and palisaded basal cells. Also there is keratin production and flat interface between epithelium and connective tissue. These features could easily be distorted / lost in the presence of inflammation posing diagnostic challenge. When compared to other cystic lesions of mandible Keratocystic Odontogenic Tumors are notorious for its recurrence rate which ranges between 25-30% (Marx, 2003). Maximum recurrences occur within the first 5 years following the treatment⁵. Nearly 75% of these tumors involve the mandible especially in the molar region or close to the angle of mandible. Majority of these lesions are asymptomatic but patient seek expert advice for the presence of swelling over the involved portion of the mandible. These lesions are identified commonly from routine radiographs (Meiselman, 1994). Recurrence following the surgical treatment of keratocysts of the jaws may present a major problem to the oral surgeon (Auluck, 2006). Recurrence of Keratocystic Odontogenic Tumors has been attributed to several mechanisms, Woolgar et al. (1987) described three different theories. The first involves incomplete removal of the original cyst lining. The second one involves growth of a new lesion from small satellite cysts or odontogenic epithelial rests left behind after the surgical treatment. The third involves the development of an unrelated OKC in an adjacent region of the jaws that is interpreted as a recurrence. It has been suggested that recurrence is a consequence of microcysts in the mucosa overlying the recurrent lesions (Worrall, 1992). Attempts have been made to reduce this high recurrence rate by improved surgical techniques, such as removal of adjacent mucosa, smoothing of the osseous wall of the cystic cavity, resection of neighbouring parts of the mandible, tanning of the epithelial lining of the cyst with Carnoy's solution and marsupialization (Marx, 2003; Williams, 1992; Meiselman, 1994).

Conclusion

Multidisciplinary approach is must for treating Keratocystic odontogenic tumour and CBCT is promising tool for aiding in diagnosis and treatment planning for the same to get a better outcome. Post operative CBCT is recommended to see the treatment outcome and healing progress.

REFERENCES

- Auluck A., Pai KM. 2006. Treatment of recurrent Keratocystic Odontogenic Tumor: a known but forgotten point. *Br J Oral Maxillofac Surg.*, 44(1):74-75.
- Marx RE., Stern D. 2003. Oral and maxillofacial pathology: a rationale for diagnosis and treatment. Chicago, 11, Quintessence 590-601.
- Meiselman F. 1994. Surgical management of the Keratocystic Odontogenic Tumor: conservative approach. *J Oral Maxillofac Surg.*, 52(9):960-963.
- Williams TP., Connor FA. 1992. Jr Surgical management of the Keratocystic Odontogenic Tumor: aggressive approach. *J Oral Maxillofac Surg.*, 52(9):964-966.
- Woolgar A., Rippin JW., Browne RM. 1987. A comparative study of the clinical and histological features of recurrent and non recurrent Keratocystic Odontogenic Tumors. *Oral Pathol Med.*, 16(3): 124-128.
- Worrall SF. 1992. Recurrent Keratocystic Odontogenic Tumor within the temporalis muscle. *Br J Oral Maxillofac Surg.*, 30(1):59-62.