



ISSN: 0975-833X

Available online at <http://www.journalcra.com>

International Journal of Current Research  
Vol. 11, Issue, 07, pp.5824-5825, July, 2019

DOI: <https://doi.org/10.24941/ijcr.36043.07.2019>

INTERNATIONAL JOURNAL  
OF CURRENT RESEARCH

## RESEARCH ARTICLE

### A CASE OF ACUTE RIGHT UPPER LIMB ISCHEMIA IN A FEMALE AGED 50 YRS PRESENTING TO ED

\*Dr. Shastry, V.G.R., Dr. Rakesh Patro and Dr. Indranil Das

Institute of Emergency Medicine, VPS Medeor Hospital, Delhi-NCR, India

#### ARTICLE INFO

##### Article History:

Received 18<sup>th</sup> April, 2019  
Received in revised form  
24<sup>th</sup> May, 2019  
Accepted 27<sup>th</sup> June, 2019  
Published online 31<sup>st</sup> July, 2019

##### Key Words:

Limb Ischaemia, Myocardial infarction,  
Embolism, Atrial fibrillation,  
Rheumatic Heart disease.

##### \*Corresponding author:

Dr. Shastrv. V.G.R.

Copyright © 2019, Shastry et al. This is an open access article distributed under the Creative Commons Attribution License, which permits unrestricted use, distribution, and reproduction in any medium, provided the original work is properly cited.

Citation: Dr. Shastry, V.G.R., Dr. Rakesh Patro and Dr. Indranil Das, 2019. "A case of acute right upper limb ischemia in a female aged 50 yrs presenting to ED", *International Journal of Current Research*, 11, (07), 5824-5825.

#### ABSTRACT

We present a case of a middle aged lady who presented to Emergency with acute onset severe 9/10 scale pain and numbness in right upper limb with no history of any previous morbidities. Myocardial infarction/acute cervical radiculopathy/CVA were being considered as working diagnosis after primary and secondary survey. An ECG done as P.O.C test showed AF with FVR. A detailed history at this stage revealed patient having received Injection Benzathine Penicillin for 5 years during her childhood but no other complaints suggesting rheumatic heart disease. Possibility of acute limb ischemia was suspected and an urgent color Doppler was ordered. This revealed total occlusion of proximal brachial artery. N.C.C.T brain was normal Consultation of CTVS surgeon taken who performed an emergency brachial artery embolectomy. Patient recovered well post operatively. But next morning patient showed signs of hemiparesis left side. MRI brain revealed MCA infarct right side.

## INTRODUCTION

The incidence of Acute limb ischemia (ALI) is 10 to 14 per 100000 per year (Galbraith *et al.*, 1985; Alef and Hamdan, 2014). Upper limb arterial ischemia is responsible for <5% of all cases of limb ischemia (McCarthy *et al.*, 1986). Upper extremity ischemia is more frequent in women with atrial fibrillation (8). ALI requires an urgent diagnosis and management and demand clinical acumen of Emergency Physician lest limb/life may be lost. The 6 P's have been classically described as signs and symptoms for acute limb Ischemia. They are Pain, Pallor, Pulselessness/pulse deficit, Poikilothermic, Paraesthesia and Paralysis. Non cardiac causes that can lead to upper limb arterial ischemia are autoimmune, connective tissue diseases such as scleroderma, rheumatoid arthritis, systemic lupus, Protein C&S deficiency and others. Although Burger's disease (thromboangiitis obliterans) most commonly affects the lower limbs, approximately 50% of patients also have upper limb involvement with subsequent digital ischemia (Olin, 2000). Another leading non cardiac cause for upper limb ischemia is large-vessel arteriopathy i.e. atherosclerosis (Campbell *et al.*, 1998), and the most common occlusive site is the origin of the left subclavian artery. Amongst the cardiac causes embolism is the most common cause of acute upper limb ischemia (Eyers and Earnshaw, 1998). Most emboli originate from the heart, caused by atrial fibrillation, recent myocardial infarction, and valvular heart disease (Deguara *et al.*, 2005). Embolic occlusion from atrial

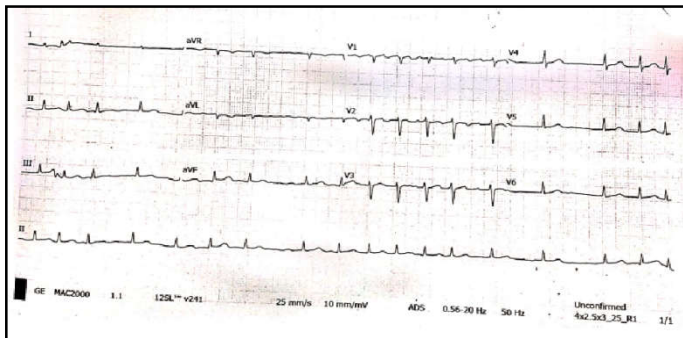
fibrillation or other sources is classically seen in the brachial artery before the bifurcation of the radial and ulnar arteries (Alef *et al.*, 2014; Eyers and Earnshaw, 1998). A majority of ALI is caused by thrombosis, with the remainder of cases caused by embolism, 85% and 15% respectively (Galbraith *et al.*, 1985). The treatment of choice for acute upper limb ischemia is surgical correction via embolectomy using a Fogarty balloon catheter. Incision of the antecubital fossa still remains the best treatment for removing brachial emboli (Deguara *et al.*, 2005). Anticoagulation – Most commonly by heparin infusion for easy titration (But some surgeons postpone heparin for 6 hrs after surgery to decrease the risk of a haematoma forming) and also starting on warfarin.

**Mortality:** The hospital mortality rate is 10 – 20%, usually secondary to Heart failure, Recurrent embolism, particularly CVA.

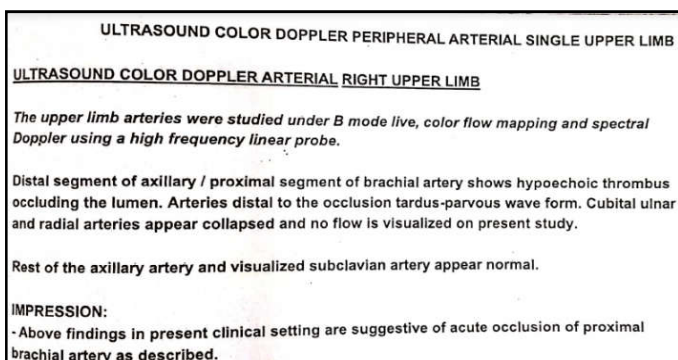
## CASE PRESENTATION

55 year old lady working as a teacher in a nearby school presented to Emergency with acute onset pain and numbness of right upper limb while teaching in her class from last 15 minutes. She never had similar episode in the past. She has no specific past medical or surgical history. Pain is severe 9/10 scale and extending from arm to finger tips. No associated symptoms like sweating, giddiness, chest pain, shortness of breath. Vitals on presentation (3.10PM): P – 140/min, BP –

130/70 mm Hg, RR – 22/min, SpO<sub>2</sub> – 96% RA, HR 140/mt. Airway, Breathing and Circulation were normal except tachycardia. There was no focal neurological deficit. In secondary survey all systems were normal. On local examination tenderness on pressure present, temperature of the affected limb was normal, no change of color seen and numbness over forearm and hand was present. Radial pulse was feeble when compared to left upper limb. Pulse Oximetry was not recordable on the affected side. Pain management was done with Inj. Tramadol 100mg I.V stat. but there was no relief in pain. Then Injection Nalbuphine 10mg I.V was given and mild relief in pain was noted (6/10). An E.C.G was taken which showed AF with FVR @140/min.



4 PM – On reassessment of vitals, the BP was measured at 90/60mmHg, and the rest of the vitals were as before. I.V fluids Normal Saline challenge of 300ml bolus given. As there was no improvement in blood pressure Vasopressor Noradrenaline @15mcg/min started. In view of Atrial fibrillation seen in ECG a further interaction with the patient regarding past history was done. She gave a history of having received Inj. Penidure (Benzathine penicillin) for five years during childhood. No further documentation/oral revelation of further morbidity was available. Presuming a rheumatic cardiac component and the ECG showing AF, acute limb ischemia secondary to an embolic event was suspected, and a CTVS referral was made, and a stat dose of Inj.Heparin 5000IU was administered. An urgent right upper limb Doppler was ordered which revealed – Acute cut-off of proximal brachial artery (Clot at distal segment of axillary/prox. segment of brachial A.)



An Echo cardiograph was done in ED which showed no clot/vegetation, grossly dilated LA, Mod. MR Mitral valve – Sclerosed and thickened, EF – 55%, No RWMA

C.T angiogram was not done as Serum creatine levels were not readily available and cyanotic changes in the limb progressing fast. Patient underwent emergency brachial artery embolectomy by CTVS team, and subsequently admitted in ward. Early morning the next day, she was noted to be drowsy,

with slurring of speech, deviation of left angle of mouth and left upper limb weakness.

NCCT Brain was normal, but MRI revealed an Acute Right MCA infarct.

ECHO – No clot/vegetation, grossly dilated LA, Mod. MR Mitral valve – Sclerosed and thickened, EF – 55%, No RWMA.

B/L Lower limbs Arterial Doppler – No occlusion.

Patient and family refused to give consent for thrombolysis. Pt. was managed with – Heparin infusion, Inj. Mannitol, T. Metoprolol and Warfarin (2mg OD).

## DISCUSSION

Patient presented to Emergency with sudden severe acute pain and numbness of upper limb without any past similar episode or specific medical or surgical co morbidity. In view of this, Myocardial infarction, CVA, Acute cervical radiculopathy were thought as Working Diagnosis. ECG done as P.O.C showed AF with FVR which led us to go further into the history. Patient came up with history of taking Injection Benzathine Penicillin in child hood for five years which is suggestive of Rheumatic component. An embolic phenomenon suspected and confirmed by Colour Doppler. This case was presented in view of its rarity (10-14/100000), absence of Classical symptoms and signs and sudden onset and lack of any past medical history. Importance of focussed history taking and most importantly a proper SAMPLE history will always aid in formulating a range of differential diagnosis for patients presenting to ED and will help in evidence based management in emergency department.

## REFERENCES

- Galbraith K, Collin J, Morris PJ, Wood RF. 1985. Recent experience with arterial embolism of the limbs in a vascular unit. *Ann R Coll Surg Engl.*, 67:30–3. [PMC free article] [PubMed] [Google Scholar]
- McCarthy WJ, Flinn WR, Yao JS, Williams LR, Bergan JJ. 1986. Result of bypass grafting for upper limb ischemia. *J Vasc Surg.*, 3:741–6. Doi: 10.1016/0741-5214(86)90038-8. [PubMed] [CrossRef] [Google Scholar]
- Alef MJ, Hamdan A. 2014. Upper extremity arterial disease: general considerations. In: Rutherford RB, editor. *Vascular surgery*. 8th ed. Philadelphia: Elsevier Saunders; pp. 1868–74. [Google Scholar]
- Olin JW. Thromboangiitis obliterans (Burgers' disease) *N Engl J Med.*, 343:864–9. Doi: 10.1056/NEJM200009213431 207. [PubMed] [CrossRef] [Google Scholar]
- Campbell WB, Ridler BM, Szymanska TH. 1998. Current management of acute leg ischemia: results of an audit by the Vascular Surgical Society of Great Britain and Ireland. *Br J Surg.* 85:1498–503. Doi: 10.1046/j.1365-2168.1998.00906.x. [PubMed] [CrossRef] [Google Scholar]
- Eyers P, Earnshaw JJ. 1998. Acute non-traumatic arm ischaemia. *Br J Surg.*, 85:1340–6. Doi: 10.1046/j.1365-2168.1998.00884.x. [PubMed] [CrossRef] [Google Scholar]
- Deguara J, Ali T, Modarai B, Burnand KG. 2005. Upper limb ischemia: 20 years' experience from a single center. *Vascular.* 13:84–91. Doi: 10.1258/rsmvasc.13.2.84. [PubMed] [CrossRef] [Google Scholar]
- Landry GJ, Shukla R, Rahman A, Azarbal AF, Mitchell EL, Liem TK, Moneta GL. Demographic and echocardiographic predictors of anatomic site and outcomes of surgical interventions for cardiogenic limb emboli.