



RESEARCH ARTICLE

COMPARATIVE EVALUATION OF PERIOSTEAL PEDICLE MEMBRANE WITH DFDBA VERSUS OPEN FLAP DEBRIDMENT WITH PRF IN CLASS II/ III FURCATIONS

¹Dr. Gazanfer Ali Shah, ²Dr. Syed Saima and ³Dr. Reyaz Ahmad Mir

¹Postgraduate Scholar, Department of Periodontics, Government Dental College and Hospital, Srinagar

²Dept of Periodontics, Government Dental College and Hospital Srinagar

³Tutor, Department of Periodontics, Government Dental College and Hospital, Srinagar

ARTICLE INFO

Article History:

Received 26th December, 2018
Received in revised form
10th January, 2019
Accepted 08th February, 2019
Published online 31st March, 2019

Key Words:

Scaling, Kirkland flap,
Calculus, Pocket depth,
DFDBA, PRF.

ABSTRACT

Background: The objective of this study was to compare the effectiveness of Periosteal pedicle membrane with DFDBA versus open flap debridement with PRF in Grade II/III furcations defects

Methods: The study population included 10 subjects, who visited the out-patient department of periodontics, Govt Dental College and Hospital Srinagar with complaint of bleeding and sensitivity, diagnosed as chronic periodontitis. After conducting routine examinations, Relative attachment and probing depth and Horizontal defect fill was measured were measured. The measurement of Relative attachment was made with oclusal stent as guiding value. Test side operated (Periosteal pedicle membrane with DFDBA), on contralateral control side Open flap debridement with PRF was done.

Results: Results showed that Patients treated with periosteal pedicle membrane in combination with DFDBA graft in Grade II/ III showed favourable results in test group than control (open flap debridement with PRF) as per Relative attachment level and furcaion defect fill is concerned.

Conclusion: within the limitations of this study, it can be concluded that space provision by an alloplastic graft material increases the regenerative potential of periosteal pedicle graft.

Copyright © 2019, Dr. Gazanfer Ali Shah et al. This is an open access article distributed under the Creative Commons Attribution License, which permits unrestricted use, distribution, and reproduction in any medium, provided the original work is properly cited.

Citation: Dr. Gazanfer Ali Shah, Dr. Syed Saima and Dr. Reyaz Ahmad Mir. 2019. "Comparative evaluation of periosteal pedicle membrane with dfdba versus open flap debridment with prf in class ii/ iii furcations", *International Journal of Current Research*, 11, (02), xxxxx-xxxxxx.

INTRODUCTION

The primary etiologic agents in periodontitis are bacterial plaque and calculus. Correlation of supragingival plaque and calculus with gingivitis and periodontitis has been demonstrated in several studies (Lindhe *et al.* 1973, 1975, Loe *et al.* 1965, Theilade *et al.* 1966). Scaling and root planing are widely used techniques in periodontal therapy to remove irritants from the surfaces of the teeth and also to reduce tooth surface roughness which may facilitate the accumulation of irritants (Waerhaug 1956). It has become increasingly evident that the most important aspect of periodontal therapy is the removal of all accretions from tooth surfaces exposed by periodontal disease (Aleo and Vandersall 1980, Axelsson & Lindhe 1978, Caton *et al.* 1982, Hughes & Caffesse 1978, Lindhe *et al.* 1973, 1975, Listgarten *et al.* 1978, Rosling *et al.* 1976, Theilade *et al.* 1966, Waerhaug 1978b). Chronic periodontitis can be treated by nonsurgical or surgical therapy, provided adequate plaque control is maintained during supportive phase of treatment (Lindhe, 1975). Non-surgical therapy consisting of oral hygiene instructions and scaling and root planing, has consistently been shown to be one of the most

effective means of treating periodontal disease (Tagge, 1975; Hughes, 1978; Morrison, 1980 and Badersten, 1981). The animal studies and clinical trials have shown that the periosteum has the potential to stimulate bone formation when used as a graft or barrier membrane. Periosteum samples taken from the chick embryos have been demonstrated with an osteogenic capacity in vitro (Fell, 1932). Free periosteal grafts taken from the tibia in the rabbits have shown the osteogenic potency when placed in the anterior chamber of the eye, in the capsule of the kidney, and in the donor site of the tibia (Cohen). Osteogenic and growth capacities of the free tibial periosteal graft in cleft lip and palate has been reviewed, and ossification of the periosteal graft has been confirmed (Raphaël, 2002). Free autogenous periosteal graft taken from the palate has shown the evidence of defect fill and improvements in pocket depths in Class II furcation defects and interproximal bony defects, when placed as a barrier membrane (Lekovic, 1991 and Kwan, 1988). The use of the cultured periosteum taken from the mandibular body of adult hybrid dog has shown evidence of regenerating periodontal tissues in class II and class III furcation defects (Wada). Case reports of periosteal displacement used a barrier in periradicular surgery have shown early remission of clinical signs and symptoms and successful healing (Tobon-Arroyave, 2004). A new technique of periosteoplasty (Periosteal eversion technique) was

*Corresponding author: Dr. Gazanfer Ali Shah

Postgraduate Scholar, Department of Periodontics, Government Dental College and Hospital, Srinagar

described by Gaggl *et al.* (Gaggl, 2005). In this technique, periosteal membrane was everted, and side opposite to cambium layer of periosteum is juxtaposed to recession area in the anterior teeth.

MATERIALS AND METHODS

Sufficient number of subjects comprising of both the sexes and diagnosed with chronic generalized periodontitis with furcation involvement between the age group of 25-50 years, were considered for the present study from the Outpatient Department of Periodontics, Government Dental College and Hospital Srinagar. The inclusion criteria included that, subjects who were diagnosed as suffering from generalized chronic periodontitis on clinical and radiological examination with furcation involvement and furcal involvement was nearly similar in selected contralateral quadrants. Subjects who were willing to appear after every two weeks for maintenance during study period were included in the study. The subjects who had history of systemic disease like i.e. diabetes, cardiovascular disease, females who were pregnant and nursing mothers and the subjects who presented mobility of teeth in selected quadrants were not included in the study. The study was performed for a 9 months. At initial examination, oral prophylaxis was performed and meticulous oral hygiene instructions were given.

The patients were recalled after 21 days. At baseline, 10 subjects were selected with Grade II/III furcation involvement in at least 2 quadrants of the mouth. Split mouth design, with one quadrant of mouth as Control Group and another quadrant as Test Group was adapted. In the Control group, Scaling and root planning was carried out and furcation defect was filled with PRF and in test group DFDBA was filled in the furcation defect and periosteal pedicle flap was taken from the adjacent area of defect site and covered over DFDBA filled furcation defect. Sutures were removed after 1 week. Oral hygiene instructions and professional tooth cleaning were repeated once every 2 weeks during study period for both selected quadrants. The clinical assessment was carried out at baseline and 9 months to evaluate the respective treatments in both the groups. The indices used for clinical assessment were Relative attachmnet level with (UNC-15) (Raphaël, 2002), from occlusal stent (Raphaël, 2002), customized acrylic stent which served as a fixed reference point for relative attachment level. Horizontal defect fill was assessed with UNC-15 periodontal probe.

RESULTS

There was statistically significant difference between two groups. Table 1 and Table 2 showed that after 9 months post Periosteal pedicle membrane with DFDBA (Test group) showed significant gain in relative attachment level and furcation depth than (Control) patients in which furcation defect was filled with PRF.

Table 1. Relative attachment level (Periosteal pedicle membrane with DFDBA versus PRF)

Time Interval	Test Group	Control Group	p-value
T1	12.5 +- 2.22	12.5 +- 2.22	
T2	6.5 +- 1.90	9.0 +- 1.63	
T1-T2	6.0 +- 1.56	3.5 +- 1.18	0.000772

P-value < 0.001 (Statistically significant)

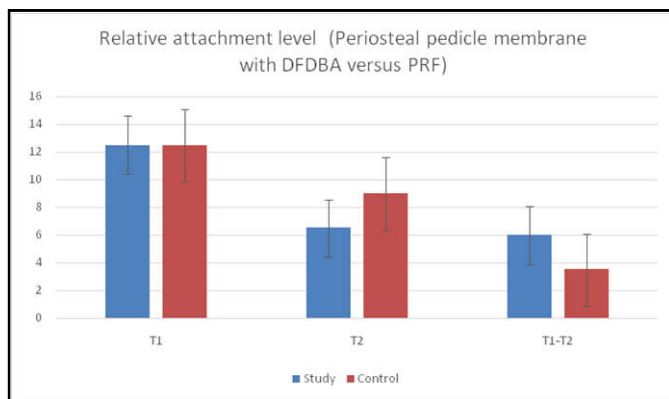
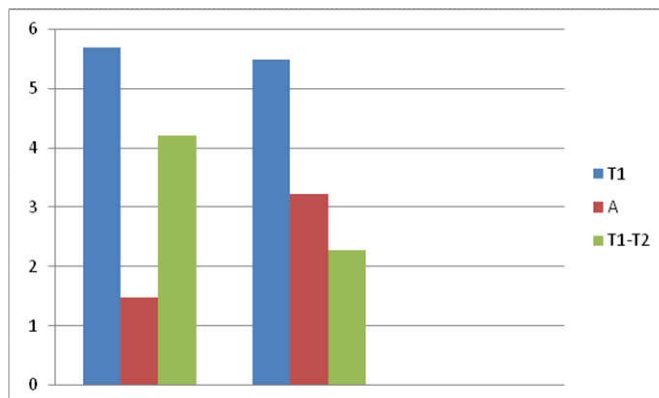


Table 2. Reduction in furcraion depth penetration on probing

Time Interval	Test Group	Control Group	P value
T1	5.70±0.78	5.50±0.89	
T2	1.48±0.77	3.23±0.78	
T1-T2	4.22±0.01	2.27±0.11	0.000878

P-value < 0.001 (Statistically significant)



DISCUSSION

This study showed significant gain in RAL and defect fill with the use of periosteal membrane in combination with DFDBA where periosteal membrane acts as a barrier. These findings can be compared to observations made by Kwan *et al.* and Lekovic *et al.*, utilizing periosteal graft as a barrier membrane in vertical and furcation defects, respectively. However, comparisons between the studies are difficult to make because of a number of differences in the study design. The measurements taken in this study were limited to the depth of furcation defects, and changes in the alveolar crest were not considered. Hirata *et al.* described the ability of vascularized periosteum to form new bone (Hirata, 2004). Periosteum contains two distinct layers: A thick, outer fibrous layer and a thin inner cambium layer which is adjacent to bone. The cambium layer has the potential to stimulate the bone formation.¹⁷ In the present study, the autogenous periosteal membrane was mobilized and placed over the exposed furcationinn combination with DFDBA with cambium layer juxtaposed to the exposed furcation. In the present study, autogenous periosteal membrane maintained its vascular supply by the fact that it was attached at one side to the mucoperiosteal flap. This is important for the healing and maintenance of the vital cambium layer which has the potential to stimulate Coronally positioned flaps and have the advantage of using the periosteum as a barrier membrane (Gantes, 1988; Garrett, 1990 and Kerdvongbundit, 1999). However, in the pocket area, the periosteum may get infected and destroyed. Hence, if the pocket depth is 5 mm or more in the furcation

area, then the flap cannot be coronally positioned to full extent. Hence in the present study, periosteum displacement technique was used. The principles of GTR are now the basis for most regenerative procedures. However, ideal GTR material should be economic, biocompatible, easy to harvest and manipulate. This barrier membrane is easy to harvest and manipulate and there is no need of a 2nd surgery to remove it as well as the need for surgery to harvest the graft, causing trauma, is avoided. Also, it being a pedicle autograft, vascular supply is maintained. Thus, the autogenous vascularized periosteal membrane is an effective alternative to the existing barrier membranes. Relative attachment level showed change from 12.5 ± 2.22 mm to 6.5 ± 1.90 mm with a gain of 6.0 ± 1.56 mm in attachment level in test group (Periosteal pedicle flap with DFDBA). Relative attachment level showed change from 12.5 ± 2.22 to 9.0 ± 1.63 mm with a gain of 3.5 ± 1.18 mm in attachment level in Control group (flap debridement with PRF), depicting statistically significant results in test than in control group. Reduction in furcation depth penetration on probing in test group (Periosteal pedicle flap with DFDBA) changed from 5.70 ± 0.78 to 1.48 ± 0.77 with filling of defect by 4.22 ± 0.01 mm, in control group Reduction in furcation depth penetration on probing changed from 5.50 ± 0.89 mm to 3.23 ± 0.78 mm with a gain of 2.27 ± 0.11 showing statistically significant results in test than in control.

Conclusion

The results of this study indicate that periosteal membranes with DFDBA were more effective than PRF in the treatment of grade II/III furcation defects in terms of depth reduction of furcation and relative attachment levels. Histologic evaluation is needed to confirm the efficacy of periosteal membrane in promoting true periodontal regeneration.

REFERENCES

- Badersten A, Nilveus R, Egelberg J. 1981. Effect of non-surgical periodontal therapy Moderately advanced periodontitis. *J Clin Periodontol.*,
- Cohen J, Lacroix P. Bone and cartilage formation by periosteum: Assay of experimental autogenous grafts. *J Bone Joint Surg Am.*,
- Fell HB. 1932. The osteogenic capacity *in vitro* of periosteum and endosteum nisolated from the limb skeleton of fowl embryos and young chicks. *J Anat.*, 66:157-80.
- Gaggl A, Jamnig D, Triaca A, Chiari FM. 2005. A new technique of periosteoplasty for covering recessions: Preliminary report and first clinical results. *Perio.*, 2:55-62. 1955;37:717-30.
- Gantes B, Martin M, Garrett S, Egelberg J. 1988. Treatment of periodontal furcation defects: (II) Bone regeneration in mandibular class II defects. *J Clin Periodontol.*, 15:232-9.
- Garrett S, Martin M, Egelberg J. 1990. Treatment of periodontal furcation defects. Coronally positioned flaps versus duramater membranes in class II defects. *J Clin Periodontol.*, 17:179-85.
- Hirata A, Maruyama Y, Onishi K, Hayashi A, Saze M, Okada E. 2004. A vascularized artificial bone graft using the periosteal flap and porous hydroxyapatite: Basic research and preliminary clinical application. *Wound Repair Regeneration.*, 12:1067-1927.
- Hughes TP, Caffese RG. 1978. Gingival changes following scaling, rootplaning and oral hygiene A biometric evaluation. *J Periodontol.*, 49: 245.
- Ito Y, Fitzsimmons JS, Sanyal A, Mello MA, Mukherjee N, O'Driscoll SW. 2001. Localization of chondrocyte precursors in periosteum. *Osteoarthritis Cartilage.*, 9:215-23.
- Kerdvongbundit V, Sirirat M, Sirikulsathean A. 1999. A clinical comparison of the new attachment obtained by guided tissue regeneration and coronally positioned flap techniques in the management of human molar furcation defects. *Aust Dent J.*, 44:31-9.
- Kwan SK, Lekovic V, Camargo PM, Klokkevold PR, Kenney EB, Nedic M, *et al.* 1998. The use of autogenous periosteal grafts as Barriers for the treatment of intrabony defects in humans. *J Periodontol.*, 69:1203-9.
- Lekovic V, Kenney EB, Carranza FA, Martignoni M. 1991. The use of autogenous periosteal grafts as barriers for the treatment of class-II furcation involvements in lower molars. *J Periodontol.*, 62:775-80.
- Lindhe J, Nyman Sture. The effect of plaque control and surgical pocket elimination on the establishment and maintenance of periodontal health. A longitudinal study of periodontal therapy in cases of advanced disease. *Journal of clinical periodontology*, 1975; 2: 67-79.
- Lindhe, J., Hamp, S.-E. & Loe, H. 1973. Experimental periodontitis in the Beagle dog. *Journal of Periodontal Research* 8, 1-10.
- Lindhe, J., Hamp, S.-E. & Loe, H. 1975. Plaque induced periodontal disease in Beagle dogs. A 4 year clinical roentgenographical and histometrical study. *Journal of Periodontal Research.*, 10, 243-255.
- Morrison EC, Ramfjord SP, Hill RW. 1980. Short term effects of initial non surgical periodontal treatment (hygienic phase). *J Clin Periodontol.*, 7: 199.
- Raphaël B, Morand B, Bettega G, Lesne C, Lesne V. 2002. Alveolar and hard palate repair by tibial periosteal graft in complete unilateral cleft lip and palate: Long-term follow-up of 51 cases. *Ann Chir Plast Esthet.*, 47:196-203.
- Tagge, D.L., O'Leary, EL-KafrawyA. The clinical and histological response of periodontal pockets to root planing and oral hygiene. *J Periodontol.*, 1975; 46: 527.
- Tobon-Aroyave SI, Dominguez-Mejia JS, Florez-Moreno GA. 2004. Periosteal grafts as barriers in periradicular surgery: Report of two cases. *Int Endod J.*, 37:632-64.
- Wada K, Mizuno H, Hata K, Ueda M. A novel approach to regenerating periodontal tissue using cultured periosteum. The 8th International Symposium on Periodontics and Restorative Dentistry; Poster No. 11.
