



ISSN: 0975-833X

Available online at <http://www.journalcra.com>

International Journal of Current Research
Vol. 10, Issue, 12, pp.76040-76044, December, 2018

DOI: <https://doi.org/10.24941/ijcr.33266.12.2018>

**INTERNATIONAL JOURNAL
OF CURRENT RESEARCH**

RESEARCH ARTICLE

PRIMARY TUBERCULOUS OSTEOMYELITIS OF PEDIATRIC MANDIBLE: DIAGNOSTIC DILEMMA AND RARE ENTITY

***¹Dr. Tejinder Kaur, ²Dr. Sarika Kapila, ³Dr. Ramandeep Singh Bhullar,
⁴Dr. Era Arora and ⁵Dr. Amneet Sandhu**

¹M.D.S, Professor & H.O.D, Department of Oral and Maxillofacial Surgery, Sri Guru Ram Das Institute of Dental Sciences and Research, Amritsar

²M.D.S, Reader, Department of Oral and Maxillofacial Surgery, Sri Guru Ram Das Institute of Dental Sciences and Research, Amritsar

³MDS, FICS, FICD, Professor & Dean Academics, Department of Oral and Maxillofacial Surgery, Sri Guru Ram Das Institute of Dental Sciences and Research, Sri Amritsar

⁴Post graduate student, Department of Oral and Maxillofacial Surgery, Sri Guru Ram Das Institute of Dental Sciences and Research, Amritsar

⁵M.D.S, Reader, Department of Oral and Maxillofacial Surgery, Sri Guru Ram Das Institute of Dental Sciences and Research, Amritsar

ARTICLE INFO

Article History:

Received 14th September, 2018

Received in revised form

26th October, 2018

Accepted 17th November, 2018

Published online 29th December, 2018

Key Words:

Primary tuberculous osteomyelitis, panoramic radiograph, Computed tomography, histopathological examination, antitubercular chemotherapy.

ABSTRACT

Introduction: Primary tuberculous osteomyelitis of mandible is an extremely rare condition, particularly in comparison to pyogenic infections and neoplastic diseases involving the mandible. Osteoarticular tuberculosis accounts for 1–2% of all the types of bone tuberculosis. Bone tuberculosis forms about 10% of extrapulmonary tuberculosis, of which 50% occur in the spine. Tuberculosis of the flat bones of the skull is uncommon and that of the mandible is especially rare as it contains less cancellous bone. **Case report:** A 9 year old female patient presented with complaint of gradually increasing swelling and persisting pus discharge from sinus on left lateral border of mandible and submandibular region since 2 months with accompanying low grade fever. Extraoral examination revealed a unilateral diffuse swelling over the left body of the mandible. The overlying skin was erythematous and showed the presence of a fistula with a serosanguinous discharge. Routine laboratory investigations were grossly unremarkable with raised total leucocyte count. There was no evidence of regional lymphadenopathy. Radiographic examination revealed carious deciduous molars with periapical abscess, CT mandible revealed marked periosteal thickening with change in trabecular pattern followed by chest examination and radiograph. Curettings from the lesion sent for histopathological examination showed collection of epithelioid cells alongwith Langhan type of giant cell and multiple granulomas. Tentative diagnosis of primary tuberculous osteomyelitis of the mandible was made and patient had been put on antitubercular drug therapy. Due to its rarity and clinical interest one should always have a suspicion of mycobacterial infection in the back of mind when dealing with chronic maxillofacial infections not responding to the usual antibiotic course and local debridement.

Copyright © 2018, Pragnesh Patel and Chirag Adroja. This is an open access article distributed under the Creative Commons Attribution License, which permits unrestricted use, distribution, and reproduction in any medium, provided the original work is properly cited.

Citation: Dr. Tejinder Kaur, Dr. Sarika Kapila, Dr. Ramandeep Singh Bhullar, Dr. Era Arora and Dr. Amneet Sandhu. 2018. "Primary tuberculous osteomyelitis of pediatric mandible: diagnostic dilemma and rare entity", *International Journal of Current Research*, 10, (12), 76040-76044.

INTRODUCTION

Tuberculosis is a chronic infectious granulomatous disease caused by *Mycobacterium tuberculosis* and less frequently by *Mycobacterium bovis*. Although tuberculosis can affect any part of the body involving both soft and hard structures with variable measures; such an occurrence in the cranio-facial

bones is relatively rare (Kamath, 2015). Osteoarticular tuberculosis accounts for 1–2% of all the types of bone tuberculosis (Koul, 2014). Bone tuberculosis forms about 10% of extrapulmonary tuberculosis, of which 50% occur in the spine (Ur-Rahman, 1980). Primary tuberculosis of the flat bones of the skull is uncommon and that of the mandible is especially rare as it contains less cancellous bone (Sachs, 1977). Primary lesions develop when tuberculosis bacilli are directly inoculated into the oral tissues of a person who has not acquired immunity to the disease. Secondary infection of oral

***Corresponding author: Dr. Tejinder Kaur,**

M.D.S, Professor & H.O.D, Department of Oral and Maxillofacial Surgery, Sri Guru Ram Das Institute of Dental Sciences and Research, Amritsar

tissues can result from either hematogenous or lymphatic spread or from autoinoculation by infected sputum and direct extensions from neighboring structures. Most of the reported cases of mandibular tuberculosis are secondary to focus elsewhere in the body and primary tuberculosis of the mandible is a rare occurrence (Koul, 2014). In an attempt to highlight a rare but equally significant presentation, we document a case of primary tuberculous osteomyelitis of mandible in a 9 year old girl who was initially suspected for dental abscess with nonspecific chronic osteomyelitis and later proved as primary tubercular osteomyelitis.

Case Report

A 9-year-old female child presented with a gradually progressive swelling on left side of the lower face and persisting pus discharge from sinuses on left lower border of mandible and in submandibular region (FIG.1) for 2 months with accompanying low grade fever. Physical examination revealed that patient was moderately built, well nourished but febrile at the time of examination. Extraoral examination revealed a unilateral diffuse swelling over the left body of the mandible. The overlying skin was erythematous, smooth, shiny, with presence of sinus having serosanguinous discharge. On palpation it was tender, firm in consistency, nonfluctuant, with elevated temperature and there was no fixation of skin with underlying tissue. There was no evidence of regional lymphadenopathy. On intra oral examination, mandibular left deciduous molars had carious exposure. However, first permanent molar was intact with no evidence of any carious lesion. On palpation there was tenderness and obliteration of the mandibular left buccal vestibule extending from the lower left deciduous first molar to the lower left permanent first molar. There was no incidence of trismus and overall oral hygiene of the patient was satisfactory.

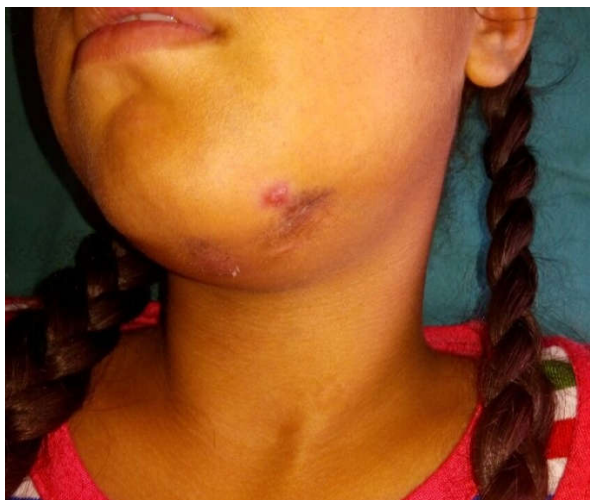


Figure 1. Extraoral sinuses on left lateral border of mandible

A Panoramic radiograph revealed carious mandibular left deciduous molars with periapical infection and ill-defined area of rarefaction with trabecular blurring with gradual erosion of cortical bone surrounding the developing crypt of left permanent mandibular second premolar that could be traced to the lower border of the mandible (FIG.2). Computed tomography (CT) was carried out with a 2-mm slice width to evaluate the complete extent of the lesion. It revealed osteolytic lesion and new bone formation in the left mandibular body region (FIG.3). Radiological findings of

destructive and reactive sclerotic changes were compatible with chronic Infection. A provisional diagnosis of a Garre's osteomyelitis, chronic non specific osteomyelitis was given initially.

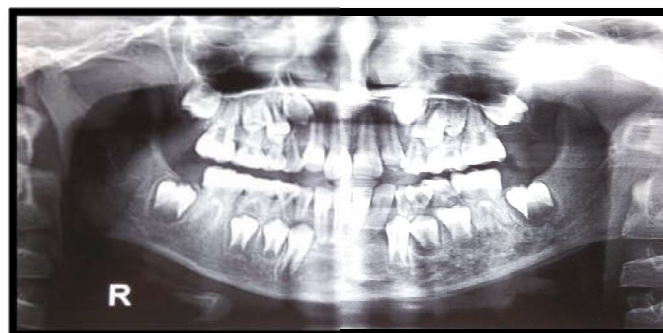

Figure 2. Preoperative panoramic radiograph revealed ill-defined area of rarefaction with trabecular blurring with gradual erosion of cortical bone

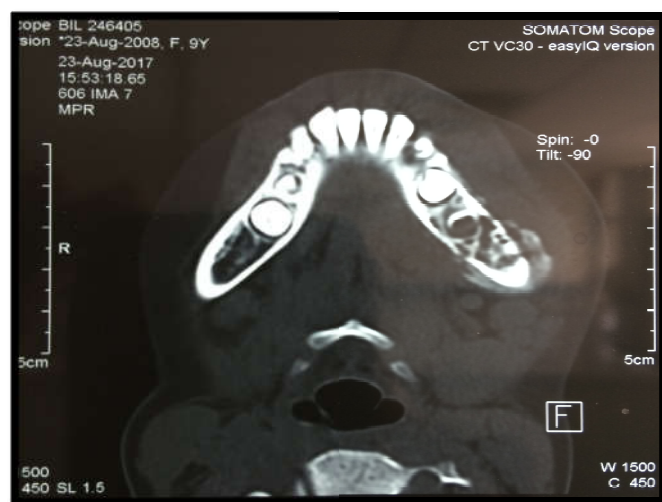


Figure 3. Computed tomography revealed osteolytic lesion and new bone formation

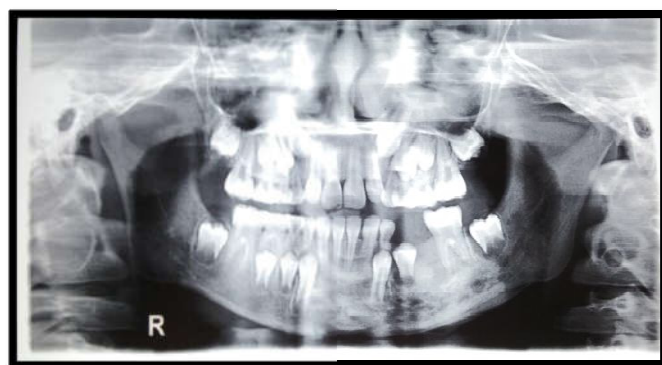


Figure 4. Panoramic radiograph revealing removal of tooth follicle irt 35

Actinomycosis and tuberculosis were thought of as differential diagnosis since it was refractory to medication. Her routine laboratory investigations were grossly unremarkable that revealed hemoglobin 9.0 gm%, total leukocyte count (TLC) 12,400 cu mm with a differential count of 80% polymorphs, 18% lymphocytes, 1% monocytes, 2% eosinophils and ESR 18mm/hr. The patient was admitted for further investigations.

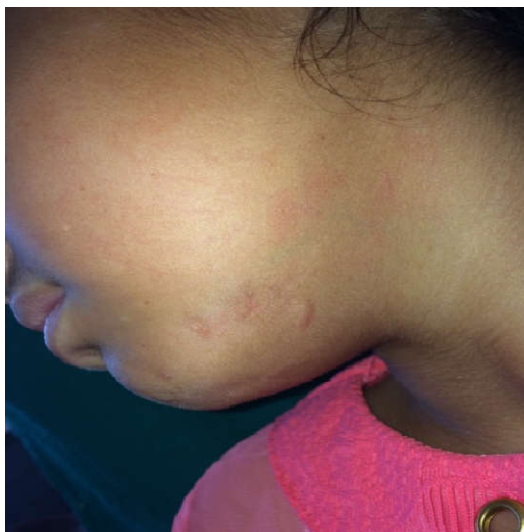

Fig. 5(A).

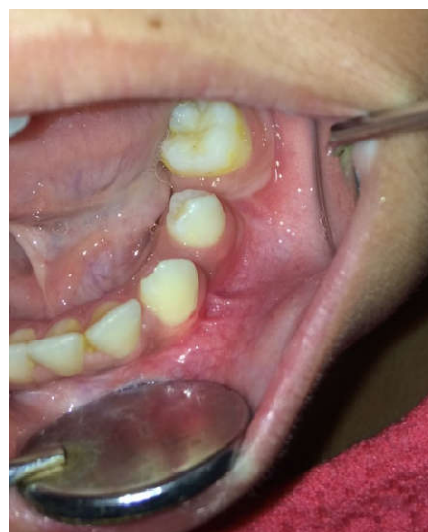

Fig. 5(B).

Figure 5(A)- At 12th month follow-up after curettage and medicinal treatment swelling regressed completely along with healing of extraoral sinus

Figure 5(b). Intra-oral picture showing uneventful healing of mucosa and erupting premolar

Table 1. Drug regimens for treatment categories I to IV

Category	Characteristic of a TB case	Treatment Regimen	
		Intensive Phase	Continuation Phase
I	New sputum smear, positive, seriously ill; negative, seriously ill, extrapulmonary	2(HRZE) ₃	4(HR) ₃
II	Relapse failure treatment after default others	2(SHRZE) ₃ followed by 1 (HRZE) ₃	5(HRE) ₃
III	Sputum smear: negative not seriously ill, extrapulmonary	2(HRZ) ₃	4(HR) ₃
IV	For treatment of MDR-TB cases (and those with rifampicin resistance)	6 Drugs: kanamycin, ofloxacin (levofloxacin), ethionamide, pyrazinamide, E, cycloserine during 6-9 months of intensive phase	4 Drugs: ofloxacin (levofloxacin), E, cycloserine during 18 months of continuation phase

During her stay, Injection Taxim (Cefotaxime sodium) 500mg 12 hourly, Injection Amikacin (Amikacin sulfate) 250 mg 12 hourly and infusion Metrogl (Metronidazole) 50 ml TDS were administered parentally. Patient underwent extraction with respect to 74 and 75 along with incision and drainage of the extraoral abscess on the left side of the mandible. A typical caseous material with a white cheesy appearance was aspirated and sent for culture sensitivity which reported the growth of streptococcus viridians organism that showed resistance to Ampicillin, Ceftazidime, Metronidazole, Clindamycin. Further investigations were carried out, including tuberculin (Montoux) test which was negative, Chest radiograph (PA view) did not reveal any abnormal findings. Polymerase chain reactions (PCR) test for Mycobacterium tuberculosis was negative. Since the tests were inconclusive, under general anesthesia, tooth follicle of 35 was removed and along with it curettage of the lesion was performed (FIG.4). The follicle and curettings were sent for histopathological examination. It showed granulomas of varying sizes and shapes consisting of central Langhan's giant cell, epitheloid cells surrounded by lymphocytes and few plasma cells. A confirmatory diagnosis of tuberculous osteomyelitis was made based on clinical findings corroborated by histopathological finding. The patient was commenced on antitubercular chemotherapy for 9 months after consultation with the physician initially with rifampicin (450 mg – two capsules once daily), isoniazid (300 mg – 2 tablets once daily), Ethambutol (600mg-2 Tablets) and pyrazinamide (750mg – 2 tablets once daily) every alternate day for 2 months followed by isoniazid (300mg-2 Tablets once daily) + rifampicin (450mg-1capsule) and pyridoxine (5mg- 1 tablet) every alternate day for 7 months.

At 2 weeks follow up some reduction in size of swelling was noticed. Patient was followed up till 12 months period and noted that the swelling regressed completely along with healing of extraoral sinus and at this stage, radiographs showed evidence of new bone formation and complete resolution of the lesion (FIG. 5-6).

DISCUSSION

Tuberculosis is a chronic granulomatous disease that can affect various systems of the body. Although pulmonary tuberculosis is the most common form of the disease, it also can occur in other organ systems such as the lymph nodes and lymphatics, central nervous system, renal system, skeletal system, hepatic system, and gastrointestinal system, including the oral cavity. Extrapulmonary tuberculosis is an uncommon form of chronic infection, which does not present with the typical signs and symptoms of pulmonary tuberculosis. Most extrapulmonary forms of tuberculosis affect organs with suboptimal conditions for bacillary growth. Therefore, extrapulmonary tuberculosis generally has an insidious presentation, a slow evolution, and paucibacillary lesions and/or fluids (Andrade, 2012). Orofacial tuberculosis is an uncommon form and presents at different sites such as the mandible (alveolar and basal bone); head; face and neck lymph nodes; salivary glands; maxilla and maxillary antrum; soft tissues such as the gingiva, tongue, muscles of mastication, and buccal mucosa. The involvement of the mandible by tuberculous infection is extremely rare as it contains less cancellous bone (Gupta, 2005). However, mandibular involvement is more frequent than maxillary

(Fukuda, 1992 and Ebenezer, 2006), with the alveolar and angle regions showing greater affinity (Eramus, 1998), 60% of all cases of TB of the jaw occur in children below the age of 16 years (Gupta, 2005); our patient was 9 years old.

Chapotel (Chapotel, 1930), described four clinical forms of tuberculosis of the mandible

- **The superficial or alveolar form** in which the alveolar process is involved either by direct extension of the tuberculous gingival tissues or by way of a deep carious tooth. The course is usually chronic, and necrosis of bone is progressive, with the formation of abscesses and fistulae.
- **The deep or central form**, in which the lesion involves the angle of the mandible. It is found, according to Chapotel, almost exclusively in children during the period of eruption of the molar teeth.
- **The diffuse form**, characterized by progressive extensive necrosis of mandible, which at times involves the tempromandibular articulation following a period of swelling and suppuration. Painless pathological fracture may occur. Severe general symptoms, accompanying a wide spread of tuberculosis affecting the liver, the lungs, the kidneys, and the meninges, are characteristic of the fatal aspect of this form.
- **The acute osteomyelitis form**, in which, as the name implies, the sudden onset, the acute local and general manifestations, and the rapid course simulate those of an acute osteomyelitis of the mandible. This form is, however, very rarely observed.

Andrade's classification (Andrade, 2012) for orofacial tuberculosis is

- **Type I Lumpy jaw:** patient presents with extraoral swelling without any intraoral or extraoral draining sinuses; the focus of infection involves the mandible or maxilla; in general, the patient's oral hygiene is good
- **Type II** Patients report a history of extraction and present with nonhealing extraction sockets with/without intraoral or extraoral draining sinus/sinuses
- **Type III** Patients report no history of extraction and present with intraoral or extraoral draining sinus/sinuses in the orofacial region and an osteomyelitic bony lesion
- **Type IV** Tuberculous lymphadenitis of the head face neck region without any features of type I, II, III, or V
- **Type V** Lesion of other sites in and around the oral cavity, eg, maxillary antrum, salivary glands, orofacial muscles, gingiva, tongue.

Radiologically mandibular tuberculosis begins as an area of rarefaction with trabecular blurring. Gradually erosion of cortical bone occurs which is then replaced by soft granulation tissue and subsequently a sub-periosteal abscess formation takes place culminating into a visible painful swelling. The granulation tissue undergoes caseation necrosis leading to liquefaction which may burst either intra-orally or outside leading to multiple discharging sinuses mostly along the inferior border of the mandible or sometimes in the pre-auricular region (Gupta, 2005). High resolution CT may reveal occult abscesses, pathological cavities, and the extent of the disease. The radiographic examination of the mandible in the present case revealed the presence of an ill-defined osteolytic

lesion involving the periapical region of carious deciduous molars and crypt of the developing left lower second premolar with periosteal reaction. Erasmus et al (1998) stated that osteomyelitis in young children involved the mandible and radiographically the lesions appeared as a unilocular destructive bony lesion that has elicited a periosteal reaction with cortical expansion. In the present case, the cause of infection could be attributed to the fact that the patient had a severely carious lower left deciduous molar which could have facilitated the entry of bacilli into the underlying connective tissue. Our patient had a chronic swelling in the region of the left body of mandible that initially resembled a chronic residual dentoalveolar abscess. It is very important to document a patient's thorough history and clinical and radiologic examinations for a correct diagnosis. The final diagnosis is established by a histopathologic confirmation and microbiological study of the tissue specimen for a definitive diagnosis of tuberculosis. Since the tests were inconclusive, biopsy from extraction socket and curettage of the lesion was performed and sent for histopathological examination. It showed granulomas of varying size and shape consisting of central Langhan's giant cell, epithelioid cells, surrounded by lymphocytes and few plasma cells. The above features were consistent with tuberculous granuloma, a chronic granulomatous lesion.

The treatment of tuberculous osteomyelitis is primarily medical. Indications for surgical treatment as an adjunct to chemotherapy include unresponsiveness to and noncompliance with medical therapy and the presence of a large or otherwise undrainable abscess. The patient could be commenced on antitubercular chemotherapy; initially with rifampicin (150 mg – two capsules once daily), isoniazid (100 mg – 2.5 tablets once daily), and pyrazinamide (500 mg – 1.5 tablets once daily) every alternate day for 2 months Further treatment with two drugs (rifampicin and isoniazid at the initial dosages) to be continued for 6 months (Andrade, 2012 and Dinkar, 2008). Antitubercular therapy consists of four conventional drugs in the form of rifampicin, isoniazid, pyrazinamide and ethambutol initially as an intensive regimen followed by rifampicin and isoniazid for a period of 9–12 months; however, WHO recommends a short course therapy of 6 months because of the pauci-bacillary nature of the disease (American Thoracic Society, 2003). A triple-drug regimen including isoniazid, rifampicin and pyrazinamide is recommended for the initial therapy. According to DOTS guidelines (Andrade, 2012), patients with less severe forms of extrapulmonary tuberculosis are categorized under treatment category III, and those with a severe form of extrapulmonary tuberculosis are categorized under treatment category I (Table.1). The total duration of therapy is still a matter of debate. Uncomplicated skeletal tuberculosis in human immunodeficiency virus-negative subjects most often benefit from a 6–9 month treatment with isoniazid and rifampicin.¹² We used three antituberculous drugs, since the patient did not have underlying immune deficiency.

Conclusion

The case reported in this paper emphasizes the importance of histopathological diagnosis in any long standing swelling, refractory to routine treatment, of which tuberculosis is one. The pivotal role in reducing morbidity and emergence of tuberculosis is through early diagnosis and prompt initiation of an effective regimen. Although tuberculous osteomyelitis of

the mandible is a rare occurrence, it must be kept in mind when routine therapy fails to bring improvement to lesions of the mandible. This case report emphasises that if the lesion is primary and detected early, the disease is completely curable and all destructive bony changes can be reversed.

Conflict of Interest: The author declares that they have no conflict of interest.

Funding Source: No grants were used.

REFERENCES

- American Thoracic Society, CDC, Infectious Disease Society of America. Treatment of tuberculosis, Morbidity and Mortality Report: Recommendations and Reports, 2003;52 (RR-11):1-77
- Andrade N, Mhatre T.S. 2012. Orofacial Tuberculosis—A 16-Year Experience With 46 Cases. *J Oral Maxillofac Surg* 70:e12-e22, 2012
- Chapotel S. 1930. Tuberculous mandibularie. *Rev Odont.*, 51:444-5
- Dinkar, A.D. V. Prabhdesai. 2008. Primary tuberculosis of the mandible, *Dentomaxillofacial. Radiol.* 37. 415-420.
- Ebenezer J, Samuel R, Mathew GC, Koshy S, Chacko RK, et al. 2006. Primary oral tuberculosis. Report of two cases. *Ind J Dent Res.*, 17: 41-44.
- Eramus JH, Thompson IOC, van der Westhuijzen AJ. Tuberculous osteomyelitis of the mandible: report of a case. *J Oral Maxillofac Surg.*, 56: 1355-1358.
- Fukuda J, Shingo Y, Miyako H. 1992. Primary tuberculous osteomyelitis of the mandible. A case report. *Oral Surg Oral Med Oral Pathol.*, 73: 278-280
- Gupta KB, Manchanda M, Yadav SP, Mittal A. 2005. Tubercular osteomyelitis of mandible. *Indian J Tuberc.*, 52:147-50
- Kamath AT, Radhakrishnan R, Bhagania M, and Mohan A. 2015. Tuberculous Osteomyelitis of the Mandible. *J Maxillofac Oral Surg.*, Mar; 14(Suppl 1): 200-202
- Koul PA, Khan UH, Jan RA, Shah TH, Bagdadi F, et al. Tubercular osteomyelitis of the mandible in a young female. *International Journal of Mycobacteriology.* Volume 3, Issue 2, June 2014, Pages 155-157
- N. Ur-Rahman, Atypical forms of spinal tuberculosis, *J. Bone Joint Surg. Br.* 62 (1980) 162-165.
- Sachs S.A, Eisenbud L. Tuberculous osteomyelitis of mandible, *Oral Surg. Oral Med. Oral Pathol.* 44 (1977) 425-429.
