



RESEARCH ARTICLE

CASE OF MALIGNANT PERIPHERAL NERVE SHEATH TUMOR (MPNST) OF BREAST IN A MALE
PATIENT: A VERY RARE CASE REPORT

¹Dr. Hemish Kania, ²Dr. Shashank Bansal and ³Dr. Amit Inamdaar

¹Postgraduate Fellow in Surgical Oncology, Dr B Borooah Cancer Institute

²Postgraduate Third year Resident in Radiation Oncology, Dr B Borooah Cancer Institute

³Post Graduate Fellow in Medical Oncology at Dr B Borooah Cancer Institute

ARTICLE INFO

Article History:

Received 29th April, 2018
Received in revised form
02nd May, 2018
Accepted 09th June, 2018
Published online 30th July, 2018

Key Words:

Malignant Peripheral Nerve Sheath
Tumour Breast,
Soft tissue sarcoma breast.

ABSTRACT

Malignant peripheral nerve sheath tumor (MPNST) is very unusual type of soft tissue sarcoma (STS) and occurs mostly in patients of neurofibromatosis. The occurrence of MPNST in breast tissue is particularly rare. Only 8 cases have been reported till date in absence of history of neurofibromatosis. We are reporting such case in a 30 years old male who presented with hard and painless breast lump for 3 months. Patient was treated with wide local excision and surgical specimen was submitted for histopathological examination. Microscopic examination revealed a malignant spindle cell tumor of low grade. Immunohistochemistry (IHC) was performed which showed positivity of vimentin and negative for LCA (leukocyte common antigen), CD99, desmin, Bcl-2, S-100. Final diagnosis MPNST was put on the basis of morphological appearance and IHC. Patient was treated with postoperative radiotherapy in dose of 50 Gy in 25 fractions in view of unknown margin status. At present patient is on regular follow up.

Copyright © 2018, Hemish Kania et al. This is an open access article distributed under the Creative Commons Attribution License, which permits unrestricted use, distribution, and reproduction in any medium, provided the original work is properly cited.

Citation: Dr. Hemish Kania, Dr. Shashank Bansal and Dr. Amit Inamdaar, 2018. "Case of malignant peripheral nerve sheath tumor (mpnst) of breast in a male patient: a very rare case report", *International Journal of Current Research*, 10, (07), 71161-71162.

INTRODUCTION

Malignant peripheral nerve sheath tumors (MPNST) are an uncommon and the incidence of MPNSTs in the common population is 0.001 percent. MPNSTs, which are classified as malignant soft tissue sarcomas, can arise from pre existing plexiform neurofibromas or perineuriomas, or normal nerves. They do not arise from schwannomas. MPNSTs also occur as secondary neoplasm 10 to 20 years after radiation therapy, accounting for up to 10 percent of MPNSTs (Perrin, 2004). From 22 to 50 percent of MPNSTs occur in patients with neurofibromatosis type 1 (NF1), the rest being sporadic (Baehring, 2003). We report a case of MPNST occurring in breast in a 30 years old male patient without any confirmation of NF1 syndrome.

Case Summary

A 30 years-old man without any previous remarkable medical history presented with history of a painless mass in the upper outer quadrant of his left breast since last 3 months, which was

gradually increasing in size. There were no other breast-related symptoms. There were no axillary lymph nodes palpable clinically. On physical examination, he had a mass in the upper outer quadrant of his left breast, which was 6×5 cm in size, mobile, painless, hard, with irregular margins, without any visible veins, with overlying skin normal. Physical examination did not reveal any signs of neurofibromatosis. Rest general examination of the patient was normal.

Investigations: The patient underwent surgical excision of mass and the whole specimen was submitted for histopathological examination. Gross specimen consisted of single brownish soft tissue portion measuring 7×6×3 cm. On cut section one cystic cavity was identified from which clear fluid came out. On microscopic examination section showed spindle cell tumor arranged in fascicular pattern. Tumor cells showed vesicular nuclei, nucleoli and occasional mitotic figures. Areas of myxoidstroma, haemorrhage, and focal areas of necrosis were seen. Immunohistochemical (IHC) study revealed positivity for vimentin and was negative for LCA (leukocyte common antigen), CD99, desmin, Bcl-2, S-100. From all these findings, diagnosis of malignant peripheral nerve sheath tumors was made.

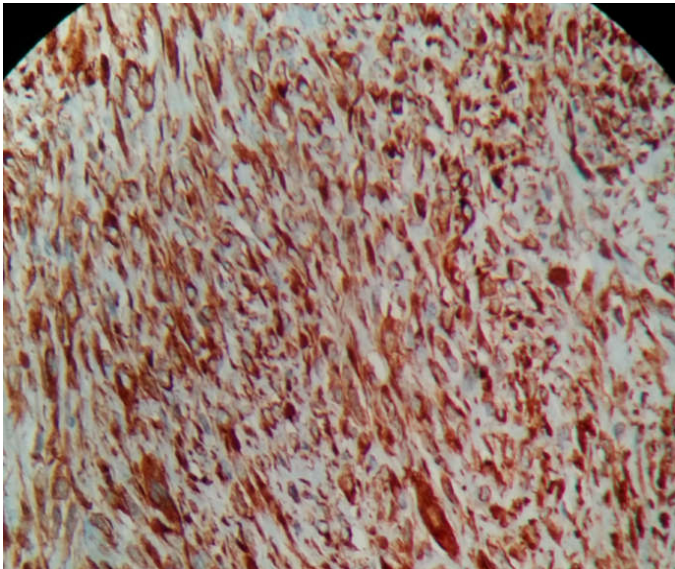
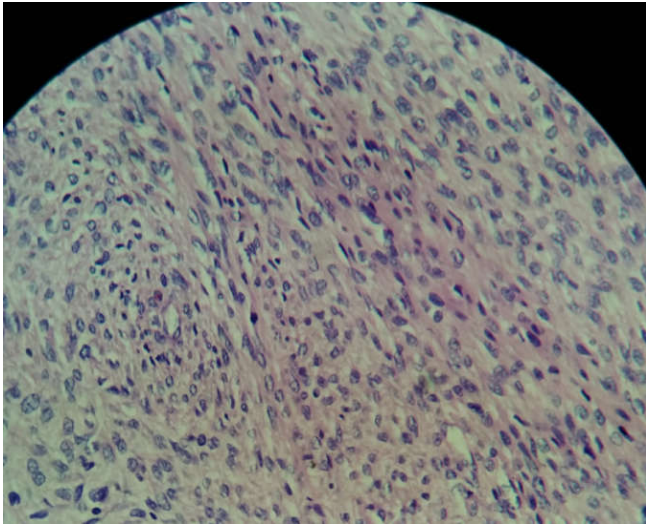
Treatment: The patient underwent surgical excision of mass, which is the main treatment modality of MPNSTs.

*Corresponding author: Dr. Hemish Kania

Post Graduate Fellow in Department of Surgical Oncology, Dr B Borooah Cancer Hospital, Guwahati, Assam

DOI: <https://doi.org/10.24941/ijcr.31311.07.2018>

The patient was referred for postoperative radiation therapy in view of unknown margin status as patient was operated outside .Patient was treated with postoperative radiotherapy in dose of 50 Gy in 25 fractions by radiation oncology department.



Breast tissue reveals spindle cell morphology with mitosis, high magnification

At present patient is on regular follow up. Chemotherapy has role in advanced disease in which combination of doxorubicin and ifosfamide has better response than single agent therapy with either drug (Kroep, 2011).

Conclusion

MPNST of breast is a very rare tumor and should be considered in differential diagnosis of breast lump. The best possible therapy is wide local excision and post operative radiotherapy. Despite multimodal therapy, including aggressive surgical resection and adjuvant radiotherapy, the prognosis remains poor.

Learning Points

- MPNST in patients without history of neurofibromatosis is very rare.
- Breast is rarest location for MPNSTs.
- Surgical excision is the best treatment.
- Postoperative radiotherapy has role in certain cases when indicated.
- In metastatic cases palliative chemotherapy used in soft tissue sarcomas can be used.

REFERENCES

- Baehring JM, Betensky RA, Batchelor TT. Malignant peripheral nerve sheath tumor: *Neurology*. 2003 Sep 9;61(5):696-8.
- Kroep JR , Ouali M, Gelderblom H , Le Cesne A , Dekker TJ , Van Glabbeke M. *et al*. First-line chemotherapy for malignant peripheral nerve sheath tumor (MPNST) versus other histological soft tissue sarcoma subtypes and as a prognostic factor for MPNST: an EORTC soft tissue and bone sarcoma group study. *Ann Oncol*. 2011 Jan; 22(1):207-14.
- Perrin RG, Guha A. 2004. Malignant peripheral nerve sheath tumors. *Neurosurg Clin N Am*. 004 Apr;15(2):203-16.
